

Transferrin iron uptake by human synovium

MARIE WILKINS, PETER WILLIAMS, AND IVOR CAVILL

From the Departments of Rheumatology and Haematology, University Hospital of Wales, Cardiff

SUMMARY ^{55}Fe -labelled transferrin was injected into the synovial fluid before synovectomy in 6 patients with rheumatoid arthritis. The results show that transferrin iron is taken up by synovial macrophages.

The synovium of patients with rheumatoid arthritis contains more than the normal amount of stainable iron (Mowat and Hotherstall, 1968; Muirden and Senator, 1968) despite the frequent presence of anaemia and sideropenia. In this respect the synovium mimics the reticuloendothelial iron stores of the marrow which in this disease may also contain increased quantities of iron. The marrow iron may come from the breakdown of worn out red cells, while in the synovium local bleeding as a result of joint damage may supply iron to the tissue macrophages. It is, however, possible that cells of the reticuloendothelial system may take up at least some of their iron from transferrin. Although Lynch *et al.* (1974) concluded that reticuloendothelial cells do not take up iron from transferrin, other workers (MacSween and MacDonald, 1969; O'Shea *et al.*, 1973) have shown that iron uptake from transferrin is possible *in vitro*. This study was undertaken to investigate whether synovial tissue macrophages can take up labelled transferrin iron *in vivo* and hence whether their intracellular iron could be in part derived from the same source.

Methods

The study was carried out in 6 patients who were to undergo synovectomy. All were suffering from classical or definite rheumatoid arthritis (Ropes *et al.*, 1959). Their haemoglobin concentrations were between 13 g/dl and 14 g/dl, with a mean corpuscular volume of 77-88 fl. Fully informed consent to participate in this study was obtained from each patient.

Approximately 2 hours before operation 10 ml venous blood was taken from each patient and the plasma transferrin labelled with ^{55}Fe by the method

of Cavill (1971). 5 ml labelled plasma was injected into the synovial fluid of the appropriate joint approximately one hour before synovectomy. The whole of the synovial tissue which was removed was immediately fixed in phosphate-buffered formalin pH 7.2. After 16 hours' dehydration portions of the tissue were embedded in wax. 5 μm sections were cut serially and mounted on glass slides which had been dipped in a solution containing 0.5 g chrome alum and 5.0 g gelatine per litre. They were then heated at 60°C for one hour, dewaxed, and passed through alcohol to water. Autoradiographs were prepared by a stripping technique using Kodak AR 10 stripping film. The coated slides were dried thoroughly, transferred to lightproof boxes, and kept at 4°C for periods of up to 4 months. After this time the film was developed and the section counterstained with Mayer's haematoxylin.

Results

After 2 months' exposure, 5 of the 6 patients showed evidence of an accumulation of ^{55}Fe in synovial

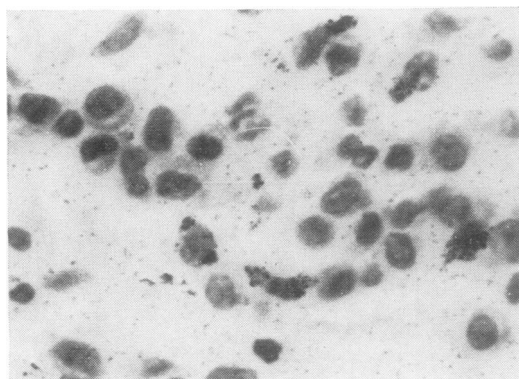


Fig. 1 Autoradiograph of ^{55}Fe distribution in the stroma of human synovium. $\times 640$.

Accepted for publication February 7, 1977
Correspondence to Dr. I. Cavill, Department of Haematology, University Hospital of Wales, Heath Park, Cardiff CF4 4XW

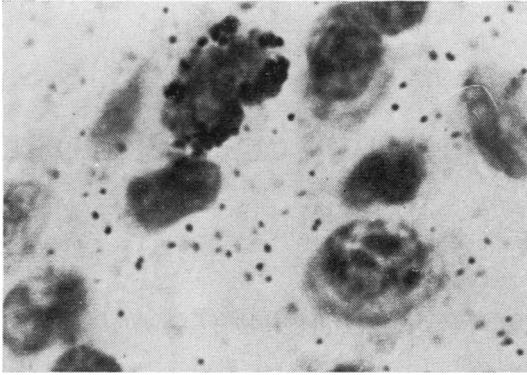


Fig. 2 Autoradiograph of ^{55}Fe distribution in the stroma of human synovium—enlarged from Fig. 1. $\times 1800$.

tissues. This appeared to be localized in macrophages below the superficial synovial cells (Fig. 1) and was consistently absent from plasma cells. Within the macrophages ^{55}Fe appeared to be confined to the cytoplasm. The nucleus did not take up any of the label (Fig. 2).

Discussion

The ^{55}Fe injected into the synovium of each patient was attached specifically and solely to transferrin. During the hour that the synovium was bathed by the labelled transferrin an unknown amount of ^{55}Fe would have moved from the joint into plasma and thence into developing red cells. These red cells would not, however, have been released into the circulation until after synovectomy. The only source therefore of the intracellular ^{55}Fe was that on transferrin in the synovial fluid. Our results show that tissue macrophages can, and do, accumulate iron from their transferrin-containing milieu.

In rheumatoid disease macrophages in both the synovium and reticuloendothelial system contain increased quantities of storage iron. The results of the present study have shown that transferrin iron can be taken up directly by these cells. Moreover, a proportion of this iron will undoubtedly become incorporated in the intracellular ferritin stores. The degree to which this occurs and the contribution it may make to the increased stores and concurrent sideropenia in these patients must remain speculative. It is clear, however, that the concept that red cells are the only source of intracellular iron in macrophages of the reticuloendothelial system is no longer tenable.

References

- Cavill, I. (1971). The preparation of ^{59}Fe -labelled transferrin for ferrokinetic studies. *Journal of Clinical Pathology*, **24**, 472–474.
- Lynch, S. R., Lipschitz, D. A., Bothwell, T. H., and Charlton, R. W. (1974). Iron and the reticuloendothelial system. *Iron in Biochemistry and Medicine*, p. 563. Ed. by A. Jacobs and M. Worwood. Academic Press, London.
- MacSween, R. N. M., and MacDonald, R. A. (1969). Iron metabolism by reticuloendothelial cells. *Laboratory Investigation*, **21**, 230–235.
- Mowat, A., and Hotherstall, T. E. (1968). Nature of anaemia in rheumatoid arthritis. VIII. Iron content of synovial tissue in patients with rheumatoid arthritis and in normal individuals. *Annals of the Rheumatic Diseases*, **27**, 345–351.
- Muirden, K. D., and Senator, G. B. (1968). Iron in the synovial membrane in rheumatoid arthritis and other joint diseases. *Annals of the Rheumatic Diseases*, **27**, 38–47.
- O Shea, M. J., Kershenovich, D., and Tavill, A. S. (1973). Effects of inflammation on iron and transferrin metabolism. *British Journal of Haematology*, **25**, 707–714.
- Ropes, M. W., Bennett, G. A., Cobb, S., Jacox, R., and Jessar, R. A. (1959). Diagnostic criteria for rheumatoid arthritis. 1958 revision. *Annals of the Rheumatic Diseases*, **18**, 49–53.