

Cardiac abnormality in polymyositis

G. P. SHARRATT, G. DANTA*, AND P. H. M. CARSON

From the Cardiac and Neurology Departments, North Staffordshire Hospital Group, Stoke-on-Trent

SUMMARY Thirteen patients with polymyositis were investigated for the presence of cardiac disease by clinical examination, chest *x*-ray, electrocardiogram, and systolic time intervals. 5 patients had evidence of cardiac involvement. Compared with the other 8 patients, their polymyositis was more long-standing, more severe, and had remained active. Electrocardiogram usually showed arrhythmias and conduction disturbances, and 4 of the 5 patients had abnormal systolic time intervals indicating left ventricular dysfunction. Left ventricular involvement in polymyositis is more frequent than previously recognized and systolic time intervals are a simple, noninvasive method of detecting this.

Isolated cases of heart disease have been reported in association with polymyositis (Radermecker and Van Bogaert, 1955; Hill and Barrows, 1968; Pennoit, *et al.*, 1969; Lynch, 1971; Schaumburg *et al.*, 1971). Walton and Adams (1958) found 4 cases with abnormal T waves on the electrocardiogram (ECG) out of 40 patients with polymyositis. We report an investigation of cardiac function on a group of patients with polymyositis.

Material and methods

Thirteen patients were studied. They were selected

Accepted for publication March 9, 1977

*Present address: Woden Hospital, Woden, Australia

Correspondence to Dr. G. P. Sharratt, Western Hospital, Oakley Road, Southampton SO9 4WQ

solely on the basis of their inpatient or outpatient availability during the period of investigation. Diagnosis of polymyositis was based upon clinical findings, serum values of muscle enzymes, electromyographic findings, and response to corticosteroids. Diagnosis was confirmed by muscle biopsy in 7 cases and 3 of the remainder had skin lesions which were characteristic of dermatomyositis. All patients were screened for the presence of carcinoma and none was found.

Cardiac investigations consisted of a clinical examination, chest *x*-ray, standard 12-lead ECG, and systolic time intervals (STI). STI were measured from a simultaneous recording of the ECG, phonocardiogram, and external right carotid pulse tracing at 100 mm/s paper speed. The following points were identified (Fig.): (a) the onset of the QRS complex of the ECG; (b) the first high frequency component

Table 1 *Cardiac findings in 5 patients with polymyositis and cardiac involvement*

Case no.	Symptoms	Abnormal physical signs	Chest <i>x</i> -ray	ECG	STI
1	None	None	Normal	Arrhythmia	Abnormal
2	Effort dyspnoea; palpitation	None	Mild cardiomegaly (CTR = 53%)	Complex arrhythmias; left anterior hemiblock	Unsatisfactory recording
3	None	None	Normal	Sinus rhythm; abnormal	Abnormal
4	Effort dyspnoea; palpitation	Soft apical pansystolic murmur	Gross cardiomegaly (CTR = 66%); pulmonary venous hypertension	Complex arrhythmias; left anterior hemiblock	Abnormal
5	Palpitation	None	Normal	Arrhythmia; right bundle branch block with left anterior hemiblock	Abnormal

CTR = cardiothoracic ratio.
STI = systolic time interval.

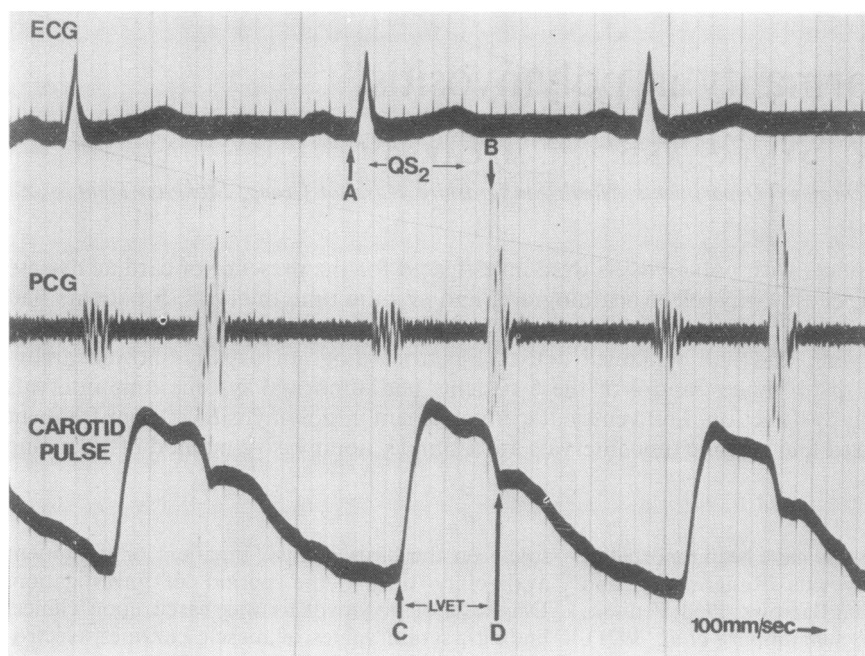


Fig. Simultaneous recording of the ECG lead which most clearly shows the onset of the QRS complex, the high frequency phonocardiogram (PCG) at the high left sternal edge, and the right external carotid pulse tracing. The traces have been recorded on thick trace for the purposes of illustration. The method of calculation of STI is explained in the text.

of the second heart sound; (c) the onset of the rapid upstroke of the carotid pulse; (d) the nadir of the dirotic notch of the carotid pulse. STI were then calculated as follows. Total electromechanical systole (QS_2) = A to B. Left ventricular ejection time (LVET) = C to D. Pre-ejection period (PEP) = QS_2 - LVET.

Recordings were made during midexpiratory apnoea. Five cardiac cycles were recorded for each period of apnoea and five periods were obtained. QS_2 , PEP, and LVET were expressed as STI indices, to correct for heart rate, using the regression equations of Weissler and Garrard (1971). The ratio PEP/LVET was calculated using uncorrected values.

Results

Seven patients had no evidence of heart disease in that clinical examination, chest x-ray, and ECG were normal and STI were all within one standard deviation of the normal range (Weissler and Garrard, 1971). In one other, chest x-ray, ECG, and STI were normal and it was therefore considered that there was no evidence of heart muscle disease. The findings in the remaining 5 patients are summarized in Table 1.

CASE 1

A 40-year-old female with an 11-year history of severe polymyositis and skin lesions treated with steroids, and at present the disease is inactive. ECG showed runs of ventricular bigeminy with occasional reciprocal beats, but was otherwise normal. The STI are shown in Table 2. LVET index was decreased and PEP index and PEP/LVET were higher than the normal.

Table 2 STI of the 5 patients with cardiac involvement

Case no.	QS_2 index (ms)	LVET index (ms)	PEP index (ms)	PEP/LVET
1	529	383	146	0.46
2	—	—	—	—
3	534	379	155	0.50
4	531	387	144	0.44
5	549	383	166	0.53
Normal values				
M	546 ± 14	413 ± 10	131 ± 13	0.35 ± 0.04
F	549 ± 14	418 ± 10	133 ± 11	

Normal values are those of Weissler and Garrard (1971). QS_2 = total electromechanical systole; LVET = left ventricular ejection time; PEP = pre-ejection period.

CASE 2

A 61-year-old male with a 7-year history of severe polymyositis treated with steroids who still had active disease. ECG had been abnormal since the onset of symptoms, showing persistent left anterior hemiblock and poor R wave progression in the anterior chest leads but no Q waves. The rhythm was originally a wandering atrial pacemaker with frequent ventricular extrasystoles and runs of atrial fibrillation. This returned to sinus rhythm with ventricular extrasystoles the following year, but 3 years later showed atrial fibrillation and runs of atrial tachycardia. The carotid pulse tracing was inadequate for the accurate determination of STI.

CASE 3

A 49-year-old female with a 4-year history of moderately severe polymyositis, with skin changes, which was treated with steroids but was still active. ECG showed a mean frontal QRS axis of 0° with a mean frontal T axis of $+50^\circ$ and inversion of T waves in leads V3, V4, V5, and V6. There was evidence of left atrial hypertrophy in that the P wave duration was 0.12 seconds and the P terminal force in lead V1 was increased. There were Q waves in leads V1 and V2 with slight ST segment elevation which has persisted. There were no arrhythmias. STI showed considerable shortening of LVET index with an increase in PEP and PEP/LVET (Table 2).

CASE 4

A 58-year-old female with a 12-year history of severe chronic polymyositis with persistent activity despite treatment with steroids and immunosuppressives. ECG has been abnormal for 12 years. Originally it showed an atrial tachycardia with 3:1 Wenckebach atrioventricular conduction. This rhythm was present on all ECGs for 4 years then sinus rhythm with multifocal ventricular extrasystoles was recorded. The only other abnormality at that time was a negative U wave in lead V6. Later that year the rhythm changed to a regular junctional rhythm with no evidence of any atrial activity, either retrograde or antegrade. There were still frequent multifocal ventricular extrasystoles and the ECG now showed left anterior hemiblock.

This rhythm persisted until 3 years ago when it became atrial fibrillation with a slow ventricular response. The T waves had become flattened in leads V4, V5, and V6. Atrial fibrillation was from time to time replaced by a junctional tachycardia with a rate of 120 per minute. The present ECG showed atrial fibrillation with runs of regular junctional rhythm with a rate of 70 per minute, frequent multifocal ventricular extrasystoles, and occasional short runs of ventricular tachycardia.

STI showed a decrease in LVET index with an increase in PEP index and PEP/LVET (Table 2). There was a soft pansystolic apical murmur, the echocardiogram of the anterior cusp was normal, and the murmur was thought to be due to functional mitral regurgitation with a large dilated left ventricle. The mitral regurgitation makes the interpretation of the STI more complex but there is little doubt that this woman had severe left ventricular myocardial disease.

CASE 5

A 52-year-old female with a $5\frac{1}{2}$ -year history of chronic, severe polymyositis which had not been treated with steroids and is still active. ECG showed paroxysmal atrial fibrillation and right bundle branch block with left anterior hemiblock. STI showed a decreased LVET index and increased PEP index and PEP/LVET (Table 2).

COMPARISON OF PATIENTS

A comparison of the 5 patients with evidence of cardiac involvement and the 8 patients with no evidence of involvement is shown in Table 3. There is no difference in the ages of the patients in the two groups. The patients with cardiac involvement have a longer history, more severe disease, and persistently active myositis, judged clinically and by serum creatine phosphokinase (CPK) values. They also have high maximum recorded levels of serum CPK. Of these 5, Case 1 had a normal level and the other 4 had 992, 4107, 2457, and 3953 IU/l respectively. Information was available about the levels in 7 of the 8 patients with no evidence of cardiac involvement. 3 had normal levels (up to 60 IU/l in females and up to 80 IU/l in males), and in the remainder the levels were 180, 108, 162, 110 IU/l.

Discussion

STIs are a calculation of the duration of some of the

Table 3 Comparison of 5 patients with evidence of cardiac involvement and 8 patients with no evidence of cardiac involvement

	Cardiac involvement	No cardiac involvement
Mean age (years) (range)	54 (40-61)	54 (24-67)
Sex	4F, 1M	5F, 3M
Duration of polymyositis (years) (range)	7.8 (4-12)	3.7 (1-7.5)
Severity of polymyositis	4 severe, 1 moderate	4 moderate, 4 mild
Persistent activity (n)	4	1
Steroids used (n)	4	5

basic haemodynamic periods of left ventricular systole from external recordings of ECG, phonocardiogram, and carotid pulse. In the absence of valvular disease, STIs are a reliable parameter of left ventricular pump performance and can detect left ventricular dysfunction when this is not clinically evident (Weissler and Garrard, 1971). Left ventricular dysfunction produces lengthening of the pre-ejection period (PEP) and shortening of left ventricular ejection time (LVET) with a consequent increase in the ratio PEP/LVET. Total electromechanical systole (QS₂) remains unchanged.

Four of the 13 patients studied had STI evidence of left ventricular dysfunction and these patients also had abnormal ECGs. In Case 2 it was not possible to obtain STI but the ECG was abnormal. These 5 patients had no symptoms to suggest that the aetiology of the heart disease was coronary artery disease but without coronary arteriography we cannot be certain. However, STIs cannot usually distinguish between normal subjects and those with symptomatic coronary disease unless there is severe three vessel disease (Perry and Garrard, 1970). Also, in Cases 2 and 4 the ECG abnormality had been present for some years with no symptomatic evidence of coronary artery disease. We therefore feel that at least the major portion of the left ventricular dysfunction and ECG abnormality is not due to coronary atheroma but in some way is related to the polymyositis.

The ECG abnormalities appear to be variable but conduction disease, notably left anterior hemiblock, is common, occurring in 3 out of the 5 cases, as are arrhythmias and in particular paroxysmal and sustained atrial arrhythmias. In the cases described by Lynch (1971) and Schaumburg *et al.* (1971) the picture was dominated by disturbance of intraventricular conduction with patches of fibrosis in the conduction tissue at autopsy. In the 2 cases reported by Pennoit *et al.* (1969) steroids were thought to be beneficial, though in our study this did not appear to be relevant and the presence of cardiac disease

seems to be related more to the severity of the disease, the height of the serum creatine phosphokinase levels, and continuing activity of the skeletal muscle disease over long periods. In the most severely affected patient, Case 4, the cardiac course appears to have been unaffected by steroids or immunosuppressive drugs. Females appear to predominate in the group with cardiac involvement.

Cardiac involvement in polymyositis may not therefore be a rarity and appears to progress with continuing activity of the skeletal muscle disease. It should be suspected if the ECG is abnormal, particularly if there is left anterior hemiblock or atrial arrhythmias. STIs are a useful noninvasive technique for establishing and quantifying the presence of left ventricular muscle involvement in polymyositis. The technique is not difficult, it requires little equipment, and we believe it is of value in the investigation and follow-up of these patients. It may also prove to be useful in patients with other muscle diseases which are associated with cardiac abnormality, such as muscular dystrophy.

References

- Hill, D. L., and Barrows, H. S. (1968). Identical skeletal and cardiac muscle involvement in a case of fatal polymyositis. *Archives of Neurology*, **19**, 545-551.
- Lynch, P. G. (1971). Cardiac involvement in chronic polymyositis. *British Heart Journal*, **33**, 416-419.
- Pennoit, H., Bekeert S., and Barbier F. (1969). Polymyositis en cardiale symptomatologie beschrijving van twee gevallen. *Acta Clinica Belgica*, **24**, 377-385.
- Perry J. M., and Garrard C. L. (1970). Systolic time intervals—relation to severity of coronary artery disease and left ventricular dysfunction. *Circulation*, Suppl. III, **41**, **42**, 121.
- Radermeeker M. A., and Van Bogaert, L. (1955). Deux observations de polymyosite aiguë généralisée (Wagner Happ). *Revue Neurologique*, **92**, 182-187.
- Schaumburg H. H., Nielson S. L., and Yurchak P. M. (1971). Heart block in polymyositis. *New England Journal of Medicine*, **284**, 480-481.
- Walton, J. N., and Adams R. D. (1958). *Polymyositis*, p. 86. Livingstone, Edinburgh.
- Weissler A. M., and Garrard C. L. (1971). Systolic time intervals in cardiac disease. *Modern Concepts of Cardiovascular Disease*, **40**, 1-8.