

Case report

Polymyositis in Chagas's disease

W. COSSERMELLI, H. FRIEDMAN, E. H. PASTOR, M. R. NOBRE,
A. MANZIONE, M. E. CAMARGO, AND M. SHIROMA

From the Rheumatology Research Unit and Department of Pathology, Faculty of Medicine, University of São Paulo, Brazil

SUMMARY Polymyositis marked the clinical onset of Chagas's disease in a patient with rheumatoid arthritis. This is unusual, although clinically unimportant muscle involvement in trypanosomiasis has been described. The plasma cell infiltrate and vascular deposition of IgM and C3 suggest that the humoral immune system may play a role in the pathogenesis of chagasic polymyositis. It is not known whether the rheumatoid diseases predisposed to the polymyositis.

There are few reports of myositis in Chagas's disease, although this is commonly seen in experimental models (Wolf *et al.*, 1952; Andrade and Andrade, 1968). Myositis associated with the presence of parasites was demonstrated by Ponce (1972) in sequential biopsies of the gastrocnemius muscle in patients with chronic and acute Chagas's disease and cardiopathy. Cenet and Rojas (1959) observed deltoid myositis in 96.3% of 27 chagasic patients, but did not mention parasites in the muscle lesions.

Cossio *et al.* (1974a, b) described a circulating autoantibody that reacts against endocardium, as well as vessels and interstitium of skeletal muscle and myocardium and interacts with complement (EVI antibody). It was found in 95% of patients with Chagas's heart disease and in 45% of asymptomatic individuals infected with *Trypanosoma cruzi*. In the early stage of acute heart disease EVI antibody is of IgM class but one month later both IgM and IgG antibodies are found. We report a patient with definite rheumatoid arthritis who developed chagasic polymyositis.

Case report

A 43-year-old white female had suffered from rheumatoid arthritis from age 17 years. Early in the course of the disease she received gold salts with remarkable improvement. After a 15-year period without symptoms, she then started to complain of

joint pain in both hands, shoulders, and knees, with morning stiffness and fever of 38°C. Nonsteroidal anti-inflammatory drugs provided some relief. At this time she had her tonsils removed. Postoperatively she received 500 ml of fresh blood. 10 days after surgery her joint pains increased and were accompanied by muscle weakness and pain in the shoulders, thighs, and legs, fever of 40°C, and tachycardia. She was wholly incapacitated by the muscle weakness. Raised values of transaminases and LDH isoenzymes and positive antinuclear factor were recorded. Prednisone 80 mg bd was started, but 20 days later she was no better and was admitted to the Hospital das Clinicas da Universidade de São Paulo.

Her general condition was fair, blood pressure 110/70 mmHg, pulse rate 100/min, respiratory rate 30/min, and temperature 38°C. No cardiac murmurs or changes in heart sounds or rhythm disturbances were found. The lungs were normal on examination. The spleen was not palpable, but the liver was enlarged about 3 cm. There was pain on joint movement in both hands, shoulders, knees, and ankles. The left ankle was swollen without limited movement. Muscle weakness in a symmetrical, proximal distribution was the prominent feature, and the affected muscles were tender to pressure. Tendon reflexes were well preserved.

The erythrocyte sedimentation rate was 49 mm/h, RA latex fixation test 1:80, negative LE-cell test, antinuclear antibodies (ANA) positive at a 1:5000 dilution (rat liver preparation), total haemolytic complement 15 U (normal: 166-333), C3 0.6 g/l (normal 0.8-1.2 g/l). Total protein measured 102 g/l, gammaglobulin 44 g/l. Serum muscle enzymes were markedly raised: creatine phosphokinase (CPK)

Accepted for publication September 5, 1977
Correspondence to Dr W. Cossermelli, Faculdade de Medicina, Universidade de São Paulo, SP 2921, São Paulo-SP Brazil.

176 IU/l (normal 0–50 IU/l), latic dehydrogenase (LDH) 746 IU/l (normal 80–240 IU/l), and SGOT 207 Frankel U/ml (normal 8–40 U/ml). Electromyography suggested primary myopathy with some signs of denervation. X-ray showed erosions and joint-space loss in metacarpophalangeal and proximal interphalangeal joints in both hands.

The diagnosis of American trypanosomiasis was suggested by specific serological reactions and confirmed by the histopathological findings. The former included the complement fixation test, positive at 1:64; the immunofluorescent indirect reaction for *T. cruzi* showed IgM and IgG antibodies at 1:160 and 1:320 respectively, and haemagglutination test with red cells coated with protein and polysaccharide extracts of *T. cruzi* were both positive at 1:320.

Rectal biopsy showed leishmania parasites within smooth muscle fibres and ganglion cells (Fig. 1). Two skeletal muscle biopsies were performed, one before and one after the introduction of specific therapy for acute Chagas's disease. Both showed myositis with hyalin focal necrosis in muscle fibres (Figs. 2, 3), but parasites were found only in the former. Lymphocytes, plasma cells, and macrophages were present, predominantly arranged in large perivascular collections (Fig. 4).

In the chagasic muscle, direct immunofluorescent reactions showed granular deposits of IgM and C3 in the walls of small arteries (Fig. 5), while the reaction for IgG had a linear sarcolemmal pattern. IgA and fibrinogen were not found. In the normal control muscle all reactions were negative, including the indirect immunofluorescent reaction for EVI antibody, using the patient's serum.

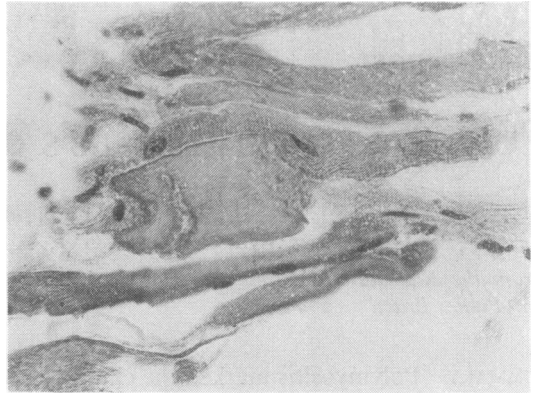


Fig. 2 Segmental necrosis of skeletal muscle fibre. Haematoxylin and eosin. $\times 275$.

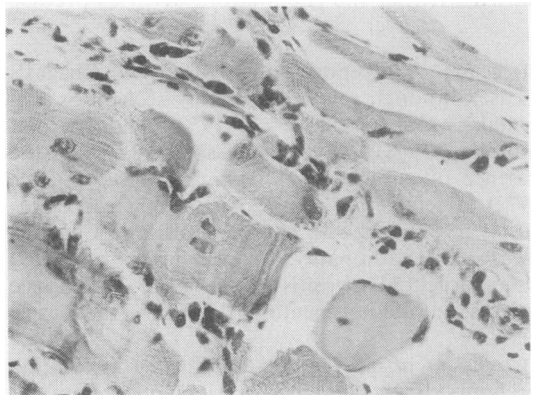


Fig. 3 Diffuse infiltrate of plasma cells in muscle biopsy. Note incipient and segmental hyalin degeneration of fibre. Haematoxylin and eosin. $\times 260$.

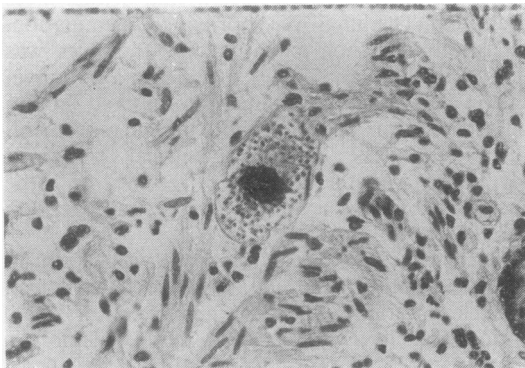


Fig. 1 Rectal biopsy showing a pseudocyst of leishmaniasis within a smooth muscle fibre of *muscularis mucosae*. Haematoxylin and eosin. $\times 230$.

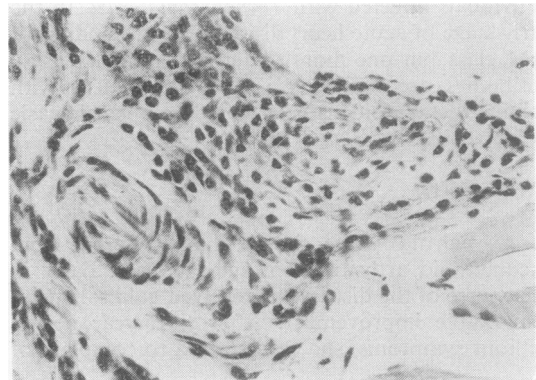


Fig. 4 Muscle biopsy showing perivascular collection of mononuclear inflammatory cells. Haematoxylin and eosin. $\times 260$.

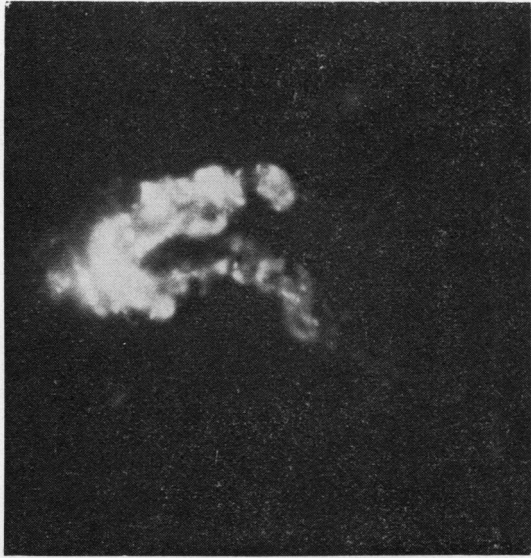

Fig. 5 IgM segmental deposition in vascular wall (fluorescence microscopy. $\times 400$).

One month after admission she developed cardiac failure which was difficult to control. She was discharged during specific therapy for acute Chagas's disease, without corticosteroids. Her general condition and the muscle weakness were moderately improved.

Discussion

The earlier diagnosis of rheumatoid arthritis was accepted when the patient was admitted to this hospital, despite her symptomatology and the laboratory findings at admission. At this stage it was thought that she was starting to develop an overlap syndrome of connective tissue disease with prominent features of polymyositis, besides her underlying rheumatoid arthritis. The typical clinical features of polymyositis were confirmed by the raised serum LDH, CPK, and SGOT and by the characteristic findings in the electromyography.

It is difficult to explain the presence of antinuclear antibody in such high titres since this is uncommon in disease other than systemic lupus erythematosus. However, she had no other evidence to support this diagnosis. 'Corticosteroid myopathy' was ruled out since we observed clinical impairment and further rises in serum enzyme concentrations after corticosteroids were withdrawn. Furthermore, the myopathy induced by corticosteroids is not inflammatory, but is an atrophic process (Adams, 1975).

The clinical and laboratory evidence of polymyositis was out of proportion to that which has been recorded as occasionally accompanying rheumatoid arthritis. The finding of parasites in the muscle lesions suggests a chagasic aetiology for the polymyositis. The parasite presumably gained access to the body through the blood transfused one month before. No other mode of transmission can be invoked since she had not been in an endemic zone for several years. These data, together with the results of the haemagglutination and immunofluorescent reactions, strongly suggest acute Chagas's disease and rule out the possibility of a chronic subclinical form of Chagas's disease reactivated by the corticosteroid therapy.

In the acute stage of Chagas's disease, the clinical picture is generally unimpressive but there may be general and cardiac manifestations. Polymyositis has not been reported as a clinical manifestation of any stage of Chagas's disease although histopathological studies of skeletal muscle have often shown conspicuous myositis (Cenget and Rojas, 1959; Ponce, 1972). It seems likely that minor degrees of clinical skeletal muscle involvement may pass unnoticed in the presence of more dramatic cardiac or other features.

The occurrence of synovitis in association with dermatomyositis and the presence of myositis in rheumatoid arthritis raises the possibility that the skeletal muscles in a patient with rheumatoid arthritis may be more vulnerable to damage from other causes. As far as the pathogenesis of polymyositis is concerned, there is evidence that cell-mediated reaction to skeletal muscle and concomitant humoral immunodeficiency are involved (Dawkins, 1975). The vascular deposition of IgM and C3 seen in this case suggest that humoral immune factors may have played a pathological role here. Whitaker and Engel (1972) noted granular deposit of IgG, IgM, and C3 in skeletal muscle blood vessel walls and suggested that the vasculitis may be one of the mechanisms of muscle injury, particularly in dermatomyositis of children.

In our case, the significant findings were the deposition of IgM and C3 in arterial wall and the perivascular mononuclear infiltrate. Necrotising vasculitis, which was frequently found in Ponce's series, was not observed and the EVI factor described by Cossio was not found. We believe that the clinical polymyositis resulted from vascular involvement besides the myositis itself. Our observations also suggest that in Chagas's disease the humoral immune system must play an important role in the pathogenesis of polymyositis.

We are very grateful to Professor H. L. F. Currey for help and advice in completing this paper.

References

- Adams, R. (1975). *Diseases of Muscle*, 3rd ed., pp. 335-337. Harper and Row, Maryland.
- Andrade, S. G., and Andrade, Z. (1968). Patologia da doença de Chagas experimental de larga duração. *Revista do Instituto de Medicina Tropical de Sao Paulo*, **10**, 180-187.
- Cenget, D. D., and Rojas, R. (1959). La biopsia de músculo deltóides en la enfermedad de Chagas. *Revista da Facultad de Medicina de Tucuman*, **2**, 27-37.
- Cossio, P. M., Diez, C., Szarfman, A., Kreutzer, E., Candiolo, B., and Arana, R. M. (1974a). Chagasic cardiopathy. Demonstration of a serum gammaglobulin factor which reacts with endocardium and vascular structures. *Circulation*, **49**, 13-21.
- Cossio, P. M., Languens, R. P., Diez, C., Szarfman, A., Segal, A., and Arana, R. M. (1974b). Chagasic cardiopathy. Antibodies reacting with plasma membrane of striated muscle and endothelial cells. *Circulation*, **50**, 1252-1259.
- Dawkins, R. L. (1975). Experimental autoallergic myositis, polymyositis and myasthenia gravis. Autoimmune muscle disease associated with immunodeficiency and neoplasia. *Clinical and Experimental Immunology*, **21**, 185-201.
- Ponce, L. A. F. Z. (1972). Miopatia chagásica esquelética. Thesis, Universidad Nacional Mayor de San Marcos, Lima, Peru.
- Whitaker, J. N., and Engel, W. K. (1972). Vascular deposits of immunoglobulin and complement in idiopathic inflammatory myopathy. *New England Journal of Medicine*, **286**, 333-338.
- Wolf, A., Kabat, E. A., Bezer, A. E., and Fonseca, J. R. C. (1952). The effect of cortisone in activating trypanosomal encephalitis and myocarditis in rhesus monkeys. *Journal of Neuropathology and Experimental Neurology*, **11**, 84-85.