

Behçet's syndrome: a family study and the elucidation of a genetic role

LOUIS BERMAN, BRIAN TRAPPLER, AND TREFOR JENKINS

From the Johannesburg General Hospital and University of the Witwatersrand Medical School, and Department of Human Genetics, School of Pathology, the South African Institute for Medical Research and University of the Witwatersrand, Johannesburg, South Africa

SUMMARY A family with features of the mucocutaneous ocular syndrome is described. A 4-generation study reveals that the condition has been inherited as an autosomal dominant trait with variable expressivity. Psychiatric symptoms and myalgia have been prominent features peculiar to our patients.

The aetiology of Behçet's syndrome has been disputed ever since Behçet's description (Behçet, 1937; Behçet, 1940). Both viral (Behçet, 1937; Sezer, 1952, 1953, 1956; Evans *et al.*, 1957; Dudgeon, 1961) and autoimmune (Jensen, 1941; Shimizu *et al.*, 1965) mechanisms have been postulated and familial occurrence has been reported (Fadli and Youssef, 1973; Fowler *et al.*, 1968; Mason and Barnes, 1969; Sezer, 1956). Goolamali *et al.* (1976) presented a 4-generation family study of Behçet's syndrome associated with psychiatric disorders, and a genetic transmission was postulated.

Patients

We present a 4-generation family study, 15 of whose members fulfil Curth's (1946a, b) criteria of Behçet's

syndrome. Five additional members, all under 10 years of age, exhibit mild expression of the symptom complex. Some of the patients presented with the more unusual manifestations of the syndrome, myalgia and psychiatric symptoms.

A pedigree of the family is presented in Fig. 1, from which it can be seen that of 42 family members personally examined, 15 fulfilled Curth's criteria for the diagnosis of Behçet's syndrome, namely 2 of the 3 principal lesions of the triple symptom complex: aphthous stomatitis, genital ulceration and ocular inflammation. Ten of the 15 affected individuals are female and the age at onset of the disease varied between $2\frac{1}{2}$ years and 50 years. Five additional members (3 males, 2 females), all aged 10 years or younger, have oral ulceration only, which is probably the earliest manifestation of the symptom complex. The affected mother of the index patient (I-5) was of Huguenot descent. There was no consanguinity and no history of any obvious

Accepted for publication 31 May 1978

Correspondence to Dr Louis Berman, c/o Department of Human Genetics, South African Institute for Medical Research, PO Box 1038, Johannesburg, South Africa.

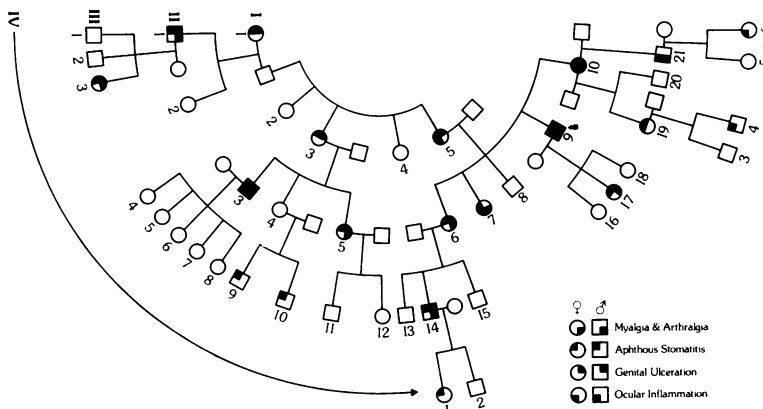


Fig. 1. Pedigree of the family.

Table 1 Clinical findings encountered among 20 affected family members

Patient	Sex	Age	Clinical features			
			Aphthous Stomatitis	Genital Ulceration	Ocular Inflammation	Myalgia + Arthralgia
I	1	F	65†	+		
	3	F	56†	+	+	
	5	F	70†	+	+	
II	1*	M	43	+		
	3	M	36	+	+	
	5	F	33	+		+
	6**	F	31	+		+
	7	F	24†	+	+	+
	9**	M	42	+	+	+
	10	F	50	+	+	+
III	3	F	7	+	+	
	9	M	10	+		
	10	M	7	+		
	14	M	22	+		
	17	F	11	+		+
	19	F	24	+		+
	21	M	30	+		
IV	1	F	2½	+		
	4	M	5	+		
	6	F	4	+		

*Pericarditis. **Billowing posterior mitral leaflet. †Died.

environmental agents operating to produce the clinical findings in the family.

ORAL LESIONS

Painful recurrent oral ulcers were recorded in all patients (Table 1). These occurred singly or in crops on the oral mucosa, lips, tongue, pharynx, soft palate, larynx, and in the nasal mucosa. They persisted for days to months, and their size varied from pinhead to 2 cm diameter. Emotional stress was implicated as a precipitating factor in 8 patients.

GENITAL ULCERS

Eight females and 4 males had painful single or multiple genital ulcers which resembled the oral ulcers both in appearance and in course.

OCULAR LESIONS

Four females and 3 males had ocular problems. All had evidence of iridocyclitis. Corneal ulcers were reported in 4. Patient III-3 is unusual in being affected at the early age of 7 years.

SKIN LESIONS

The index patient (II-9), 42 years, has severe acne and numerous generalised skin pustules. Two children aged 2½ years (VI-I) and 4 years (IV-6) have eczema.

MYALGIA AND ARTHRALGIA

Myalgia and arthralgia were prominent in 9 patients. The pain was described as deep-seated and gnawing in all muscles, but more particularly in the arms and chest wall. Movement and pressure did not aggravate

the discomfort, and rest did not ease the pain. Simple analgesics and anti-inflammatory agents were ineffective. The pain could last for weeks. The severity and duration of the pain induced the index patient (II-9) to become dependent on habit-forming drugs. Colchicine, however, was discovered to produce a dramatic improvement of the myalgia within 24 hours of taking the drug. Relapse would occur immediately after stopping the drug. The other symptoms were marginally improved by Colchicine. Arthritis was not a prominent manifestation in any of the patients.

PSYCHOLOGICAL DISTURBANCES

Ten patients had mental depression requiring therapy. The index patient (II-9) was committed to a mental institution. A woman aged 24 years (II-7) committed suicide.

CARDIOVASCULAR SYSTEM

A man (II-I) aged 43 years had an unexplained pericarditis, and patient IV-4, a boy of 5 years, had recurrent attacks of paroxysmal atrial tachycardia. Patients II-6 and II-9 have Barlow's syndrome (billowing posterior mitral leaflets).

Discussion

Arthritis, although well described in Behçet's syndrome (Mason and Barnes, 1969) was not present in our patients. However, 9 patients presented with severe muscle pain, incapacitating them and lasting for intervals of weeks before remission. This symptom has not previously been described. Colchicine

was found to have a dramatic effect on the alleviation of the pain. Since the basic pathological lesion is considered to be a vasculitis of small vessels (Nazzaro 1966; O'Duffy and Carney, 1971; Shikano, 1966, Lehner, 1969; Saito *et al.*, 1971), with a perivascular lymphomononuclear cell infiltration and an exaggerated chemotactic polymorphonuclear response (Mizushima *et al.*, 1977), it is possible that this may be explained by its inhibition of polymorph chemotaxis (Mizushima *et al.*, 1977).

Psychological symptoms of depression requiring therapy were found in 10 patients. One patient committed suicide. Neurological signs were absent. Dementia has been described in patients with neurological signs, but there have been few reports of psychiatric manifestations of Behçet's syndrome. Schotland *et al.* (1963) referred to 9 patients in whom signs of confusion and emotional lability were present. In a psychiatric study of Behçet's syndrome (Epstein *et al.*, 1970) submissiveness, depression, and neuroses were observed. Goolamali *et al.* (1976) described the development of acute schizophrenia with affective features in one of their patients.

Two patients were found to have Barlow's syndrome. The unaffected members were examined but not found to have this entity. As this condition is relatively common, it is likely to be independent of Behçet's syndrome.

Chajek and Fainaru (1975) reviewed Behçet's syndrome and emphasised the male preponderance. Ten of our patients were female. Our youngest patient (III-3) was 7 years and our oldest died at the age of 70 years (I-5). Five children (Table 1), all younger than 10 years, have aphthous ulcers.

Published reports of genetic transmission of Behçet's syndrome are rare. Sezer (1956) diagnosed the syndrome in 3 brothers and Fowler *et al.* (1968) described neurological manifestations in 2 sisters with Behçet's syndrome.

Mason and Barnes (1969) reported 28 cases, and 4 of these had affected family members: a man had 1 brother who was definitely affected and another who was possibly affected; a woman's father and 2 siblings had buccal ulcerations (while her mother possibly had Behçet's syndrome); another woman's mother was possibly affected; and an affected woman had 1 daughter definitely and another possibly affected. In the discussion which followed the presentation of Mason and Barnes's paper, D. A. Pitkeathly of Wigan, described a family in which brother and sister had Behçet's syndrome, while their mother had atypical arthritis with iritis, 'But one couldn't make the diagnosis of Behçet's syndrome definitely; she, however, has unilateral sacroiliitis'. Chajek and Fainaru (1975) encountered

among their 34 predominantly Jewish patients 2 pairs of brothers with Behçet's syndrome; 1 pair had an affected sister and a nephew with recurrent aphthous stomatitis. Chajek *et al.* (1977) again referred to these 2 families and in addition reported a significant association between Behçet's syndrome and HLA B5. Fadli and Youssef (1973) reviewed 45 cases with Behçet's syndrome in the United Arab Republic and showed that in 3 instances, 2 siblings had the disorder. Goolamali *et al.* (1976) have reported a family in which 1 individual has been involved in each of 3 generations, and 2 individuals in 1 generation, compatible with autosomal dominant inheritance. The HLA haplotype 1-17 was present in all 4 affected persons.

It appears that the condition we have described is inherited as an autosomal dominant condition with variable expressivity, even though there is no male to male transmission. There is 1 patient (II-4) (Fig. 1) in whom the gene would appear to be nonpenetrant.

If one postulates that Behçet's syndrome is inherited as an autosomal dominant with variable expressivity (and even occasional nonpenetrance) then the few previous family reports would lend support to this theory. There may, in fact, be nothing unique about the family reported here, and if this is so it may be expected that, as clinicians specifically search for affected relatives, more families will be reported.

References

- Behçet, H. (1937). Über rezidivierende, aphthöse, durch ein Virus verursachte Geschwüre am Mund, am Auge, und an den Genitalien. *Dermatologische Wochenschrift*, **105**, 1151-1157.
- Behçet, H. (1940). Some observations on the clinical picture of the so-called triple symptom complex. *Dermatologica*, **81**, 73-83.
- Chajek, T., Brautbar, C., Cohen, T., Lamm, L. V. (1977). A Study of Genetic factors in patients with Behçet's disease in Israel. Abstracts from XIV International Congress of Rheumatology, San Francisco. 26 June-1 July, p. 208.
- Chajek, T., and Fainaru, M. (1975). Behçet's disease: report of 41 cases and review of the literature. *Medicine*, **54**, 179-196.
- Curth, H. O. (1946a). Recurrent genito-oral aphthosis and uveitis with hypopyon (Behçet syndrome). *Archives of Dermatology and Syphilology*, **54**, 179-196.
- Curth, H. O. (1946b). Behçet's syndrome, abortive form of recurrent aphthous oral lesions and recurrent genital ulcerations. *Archives of Dermatology and Syphilology*, **54**, 481-484.
- Dudgeon, J. A. (1961). Virological aspects of Behçet Disease. *Proceedings of the Royal Society of Medicine*, **54**, 104-107.
- Epstein, R. S., Cummings, N. A., Sherwood, E. B., and Bergsma, D. R. (1970). Psychiatric aspects of Behçet's syndrome. *Journal of Psychosomatic Research*, **14**, 161-172.

- Evans, A. D., Pallis, G. A., and Spillane, J. D. (1957). Involvement of the nervous system in Behçet's syndrome. *Lancet*, **2**, 349-353.
- Fadli, M. E., and Youssef, M. M. (1973). Neuro-Behçet's syndrome in the United Arab Republic. *European Neurology*, **9**, 76-89.
- Fowler, T. J., Humpston, D. J., Nussey, A. M., and Small, M. (1968). Behçet's syndrome with neurological manifestations in two sisters. *British Medical Journal*, **2**, 473-474.
- Goolamali, S. K., Comaish, J. S., Hassanyek, F., and Stephens, A. (1976). Familial Behçet's syndrome. *British Journal of Dermatology*, **95**, 637-642.
- Jensen, T. (1941). Röchfällige aphthöse Geschwürsbildung an Mundschleim haut und Geschlechtsteilen nebst Regenbogenhautenzündung und Schnervenschwund (Behçet's syndrome) (Abstract). *Zentrablatt für die gesamte Ophthalmologie*, **46**, 446.
- Lehner, T. (1969). Characterisation of mucosal antibodies in recurrent aphthous ulceration and Behçet's syndrome. *Archives of Oral Biology*, **14**, 843-853.
- Mason, R. M., and Barnes, C. G. (1969). Behçet's syndrome with arthritis *Annals of the Rheumatic Diseases*, **28**, 95-103.
- Mizushima, T., Matsumura, N., Morito, T., and Matsumura, T. (1977). Chemotaxis of leucocytes and use of colchicine in Behçet's disease. XIV International Congress of Rheumatology (Abstract), p. 210. San Francisco.
- Nazzaro, P. (1966). Cutaneous manifestations of Behçet's disease: clinical and histopathological findings. International Symposium on Behçet's Disease, Rome. 1965, p. 15. Karger: Basel/New York.
- O'Duffy, J. D., and Carney, J. A. (1971). Report of 10 cases, 3 with new manifestations. *Annals of Internal Medicine*, **75**, 561-569.
- Saito, T., Homma, T., Sato, T., and Fujioka, Y. (1971). Auto-immune mechanisms as a probable aetiology of Behçet's syndrome, an electron-microscopic study of the oral mucosa. *Virchows Archiv, für Anatomie, Pathologische Ser.A*, **353**, 261-272.
- Schotland, D. L., Wolf, S. M., White, H. H., and Dubin, H. V. (1963). Neurological aspects of Behçet's disease. Case report and review of the literature. *American Journal of Medicine*, **34**, 544-553.
- Sezer, N. F. (1952). Culture et identification du virus de la maladie de Behçet. *Bulletin et Mémoires de la Société Française d'Ophthalmologie*, **65**, 158-178.
- Sezer, N. F. (1953). The isolation of a virus as the cause of Behçet's diseases. *American Journal of Ophthalmology*, **36**, 301-315.
- Sezer, N. F. (1956). Further investigation of the virus of Behçet's disease. *American Journal of Ophthalmology*, **41**, 41-55.
- Shikano, S. (1966). *International Symposium on Behçet's disease, Rome 1965*, p. 111. Karger: Basel/New York.
- Shimizu, T., Katsota, Y., and Oshimo, Y. (1965). Immunological studies on Behçet's syndrome. *Annals of the Rheumatic Diseases*, **24**, 494-450.