

Pyrophosphate arthropathy in hypophosphatasia

A. W. T. EADE,¹ A. J. SWANNELL,² AND N. WILLIAMSON³

From the ¹*Coventry and Warwickshire Hospital, Coventry; the* ²*City Hospital, Nottingham; and the* ³*Department of Investigative Pathology, Rheumatism Research Wing, University of Birmingham*

SUMMARY The association of hypophosphatasia and pyrophosphate arthropathy in an adult patient has been described on 1 previous occasion. We report a further 2 patients with this disease combination. One patient suffers from the type of hypophosphatasia that presents in adult life, with fractures that are either spontaneous or the result of minimal trauma. The other patient suffered from the severe type of hypophosphatasia that presents in infancy but survived longer than is usual; the necropsy findings on this patient are reported.

Hypophosphatasia is a rare inherited disorder associated with a low level of tissue and serum alkaline phosphatase. Diagnosis is established by the low level of serum alkaline phosphatase, abnormal mineralisation of bone, and excess of phosphoethanolamine in the urine.

Macey¹ described 2 brothers with unduly fragile bones and an extremely low serum alkaline phosphatase, and they may well have been the first 2 adult cases of hypophosphatasia to be reported. The rarity of the condition is confirmed by Birtwell *et al.*² and Jordan *et al.*³ who, when they reviewed the world literature, found the total number of recorded cases to reach only just double figures.

Rathbun⁴ was the first to report a case of hypophosphatasia occurring in a child. McCance *et al.*⁵ and Fraser⁶ reviewed the information then existing concerning this condition, and the latter noted that the presenting clinical features relate to the time of development of the bone lesions and that on this basis there are 3 main disease patterns.

Infants in whom bone lesions are present at birth or within the first 6 months of life usually present with systemic upset. Anaemia, irritability, persistent vomiting, and dehydration are common, and the more severely affected suffer unexplained convulsions and repeated attacks of cyanosis and pneumonia.

Skeletal abnormalities may include costochondral beading, enlargement of the epiphyses, and cranial deformities. The general appearance may stimulate that of rickets, but, apart from the differing general

features that have been mentioned, in hypophosphatasia the serum alkaline phosphatase is low rather than high. In this group hypercalcaemia and renal failure are common. Few survive beyond 1 year, and renal failure is the usual cause of death.

The second group consists of children in whom the bony defects gradually become apparent after the age of 6 months. These children are much less severely affected than those of the first group and usually present with orthopaedic difficulties, such as genu valgum, or with early loss of primary teeth.

The third group of patients suffering from hypophosphatasia present in adult life with repeated fractures due to unduly fragile bones, and there may or may not be history of bony deformities and dental problems in childhood.

Pyrophosphate arthropathy is a well recognised condition that has been described under many different names such as pseudogout,⁷ chondrocalcinosis,⁸ and calcium pyrophosphate dihydrate crystal deposition disease.⁹ This condition may be associated with other disorders and is sometimes recognised to be secondary to them.

In 1970 O'Duffy¹⁰ described a patient with the adult type of hypophosphatasia who also suffered from arthritis affecting the knees and small joints and in whom there was x-ray evidence of chondrocalcinosis. Calcium pyrophosphate dihydrate crystals were demonstrated in a specimen of cartilage of the symphysis pubis obtained by biopsy. This appears to be the only published report of hypophosphatasia and pyrophosphate arthritis occurring in the same patient, but O'Duffy mentions that the x-rays of a previously reported case of hypophosphatasia² showed evidence of calcification of both hip and knee cartilage.

Accepted for publication 18 March 1980

Correspondence to Dr A. W. T. Eade, Coventry and Warwickshire Hospital, Stoney Stanton Road, Coventry CV1 4FH.

We now report 2 cases of hypophosphatasia belonging to opposite ends of the spectrum of this disease both of whom have suffered repeated attacks of arthritis and have chondrocalcinosis.

Case reports

CASE 1

This female patient presented in infancy with a history of recurrent vomiting, failure to thrive, and left-sided convulsions, and she died in renal failure at the age of 23 years.

At the time of the first admission to hospital the principal clinical findings were dehydration, bulging fontanelles, a rickety rosary, and enlarged epiphyses. The radiographs were grossly abnormal and showed changes suggestive of severe rickets, but the serum alkaline phosphatase was very low at 3.9 King-Armstrong units (normal range for this age was quoted as 10 to 35 K-A units).

The serum urea was 80mg/100 ml (13.3 mmol/l) and the serum calcium 14.8 mg/100 ml (3.7 mmol/l). Histological examination of a bone biopsy showed defective ossification of an imperfectly formed calcified matrix, and by a histochemical staining technique the alkaline phosphatase activity was judged to be about 25% of normal. The diagnosis of hypophosphatasia was made, and, at a later time when the laboratory facility had become available, this clinical diagnosis was confirmed by the demonstration of an excess of phosphoethanolamine in the urine.

Throughout childhood she continued to suffer from fits, which gradually became less frequent and less severe. At the age of 2 years papilloedema occurred, and was not relieved by craniotomy. The papilloedema later resolved spontaneously but did recur from time to time.

At the age of 3 years severe genu valgum was noted. This restricted her mobility, but her general state improved sufficiently to allow her to attend a school later for the physically handicapped.

At the age of 10 years she became subject to occasional short-lived episodes of acute pain and swelling affecting one joint at one time. At different times the knees, ankles, and shoulders were involved. These episodes usually lasted for only a few days, after which there appeared to be no residual loss of function. She also became subject to episodes of pain and swelling affecting the hands and feet. These episodes lasted for longer than those relating to the large joints, and, although it was initially thought that they were part of the arthropathy, later radiographs showed fractures and subperiosteal bone formation in relation to several of the metacarpal and metatarsal bones (Figs 1a and 1b).

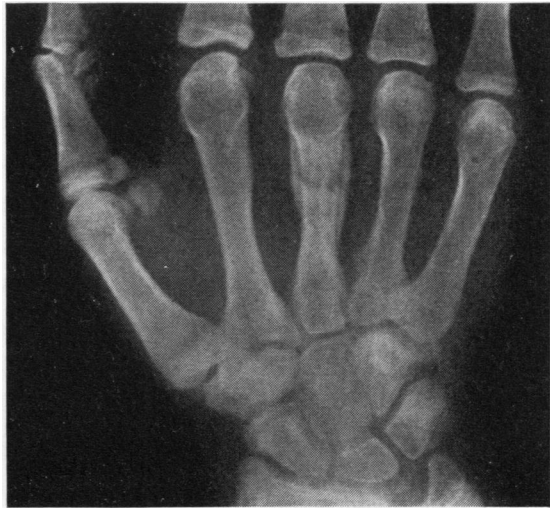

Fig. 1a Case 1. Radiograph of right hand showing a fracture of the third metacarpal.

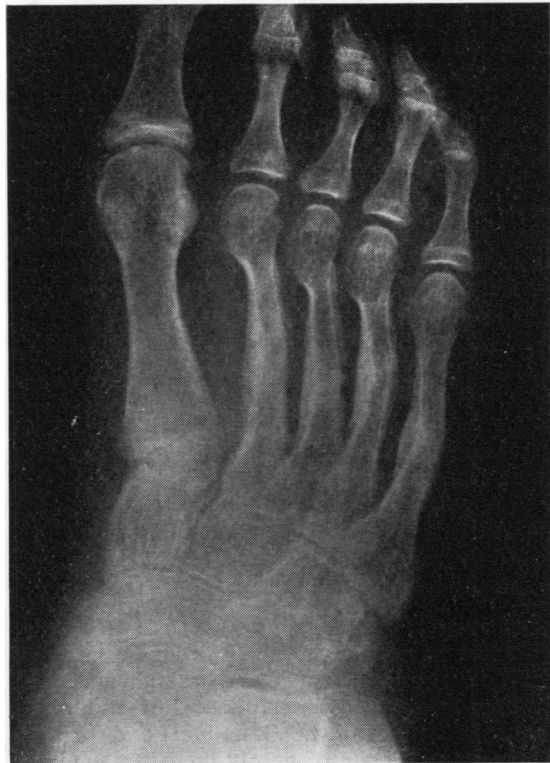

Fig. 1b Case 1. Radiograph of foot showing multiple fractures and subperiosteal bone formation in several of the metatarsal bones.

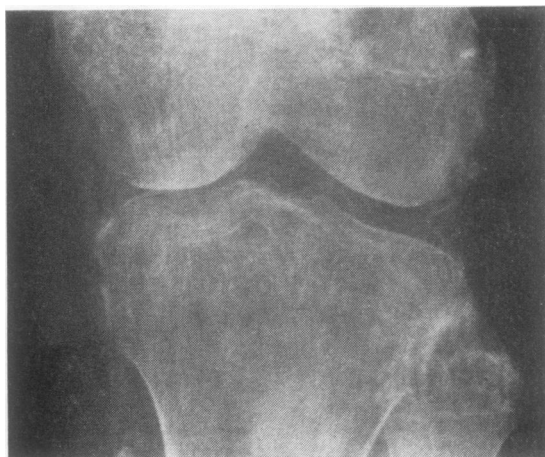

Fig. 2 Case 1. Radiograph of the left knee showing evidence of chondrocalcinosis.

At the age of 13 years she developed hypertension, which was satisfactorily controlled by the drugs that were then available.

In 1971, at the age of 19 years, she experienced acute pain of sudden onset affecting one knee. A spontaneous fracture of the tibial plateau was suspected, but the x-rays showed clear evidence of chondrocalcinosis (Fig. 2), and the symptoms settled more quickly than would be expected if they had resulted from a fracture. Some months later there was a similar acute episode involving one shoulder, and this provided opportunity to obtain some synovial fluid. The fluid contained crystals that had the characteristics of calcium pyrophosphate dihydrate.

In later years the episodes of acute joint pain became much less frequent, but renal function became more impaired. Renal biopsy was reported as follows: 'Fibrosis of glomeruli, tubular atrophy, interstitial fibrosis, patchy round cell infiltration and a few deposits of calcium.'

Her general condition gradually deteriorated. She became subject to recurrent infections, sustained a spontaneous fracture of the femur and eventually died in renal failure.

NECROPSY

Post-mortem examination confirmed the presence of skeletal abnormalities and numerous ectopic calcium deposits in many different tissues. Several bones including those of the hands and feet and the right femur, were the site of poorly united or ununited fractures. With the exception of the right knee and right shoulder, which were slightly swollen, the synovial joints were normal in external appearance.

Little fluid was obtained from the 2 named joints but both the thickened synovium and the articular cartilage were the sites of distinct white deposits. Calcium deposition in soft tissues took the form of many small discrete accumulations, barely visible macroscopically but giving a typical 'gritty' feel on cutting the tissues. This was so with respect to the heart, liver, and kidneys. Calcium deposition was more marked in the connective tissues and in the falx cerebri, and the tentorium cerebelli it was gross. There were distinct calcium deposits in the mitral valve. The renal cortex was narrowed, and there was a large single hydronephrotic cyst in the left kidney. The lungs were congested and the pleural cavities contained some clear fluid. The spleen was congested. The uterus was small and infantile. The endocrine glands appeared normal.

Microscopic examination

Changes in bone and cartilage resembled those seen in osteomalacia, the dominant abnormalities being at the osteochondral junctions, where normal architecture was considerably disrupted. There was loss of calcium in the zone of provisional calcification, and the 'tide mark', usually a prominent feature, was either absent or when present was jagged and irregular. Instead of the normal growth transition from bone to pallisaded cartilage cells there was considerable disordered growth, with tongues of uncalcified cartilage projecting toward the shaft of the bone, often as distorted irregular masses. Between these islands of cartilage cells there were spicules of bone, usually consisting of wide bands of uncalcified osteoid surrounding less prominent regions of well formed calcified bone (Fig. 3).

With respect to the long bones, thickening of the periosteum and irregular notching of the surface of the underlying bone was a common finding. The shafts appeared narrow but on sectioning showed few other abnormalities. At the site of fractures there was considerable cellularity, with a fairly well formed soft tissue callus, but no evidence to suggest that calcification was in progress. Some areas showed many osteoblasts and wide seams of uncalcified osteoid, and in other areas well developed cartilage cells were seen.

Articular cartilage contained large deposits of amorphous calcium (Fig. 4), and staining of cartilage and bone showed little alkaline phosphatase activity.

Sections of synovial membrane contained deposits of calcium. Numerous distinct crystals of calcium pyrophosphate dihydrate and calcium oxalate were identified by polarising microscopy. Few inflammatory cells were present, but there was some hypertrophy of the synovial cells.

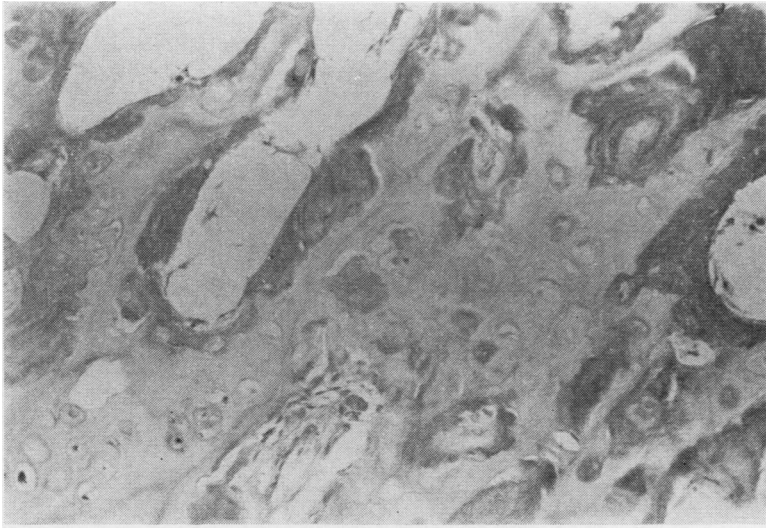


Fig. 3 *Section of articular cartilage extending into the shaft of the bone showing uncalcified osteoid and islands of cartilage cells. (H and E, $\times 45$).*

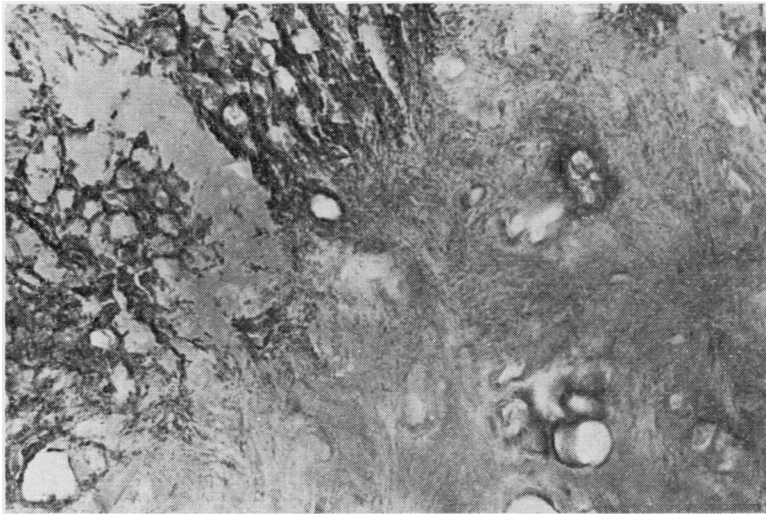


Fig. 4 *Section of articular cartilage showing deposits of amorphous calcium. (Van Kossa, $\times 115$).*

Synovial fluid contained very few cells and only occasional calcium pyrophosphate crystals but many calcium oxalate crystals (Fig. 5). This contrasted with the finding 4 years before death when there had been numerous calcium pyrophosphate dihydrate crystals but no oxalate crystals.

In the kidney deposits of calcium appeared responsible for most of the changes observed, and it seemed likely that the hydronephrotic cyst in the left kidney had resulted from a renal calculus. Microscopic deposits of calcium were found in the

interstitium, in blood vessel walls, and in the degenerate tubular cells. However, in none of the sections examined were large deposits of calcium seen. Distortion of normal architecture with considerable degree of tubular atrophy, fibrosed and hyalanised glomeruli, marked interstitial round cell infiltration, and some thickening of arterial walls were the main findings. Very little normal kidney parenchyma remained. These findings were consistent with the chronic renal failure to which the patient's death had been attributed.

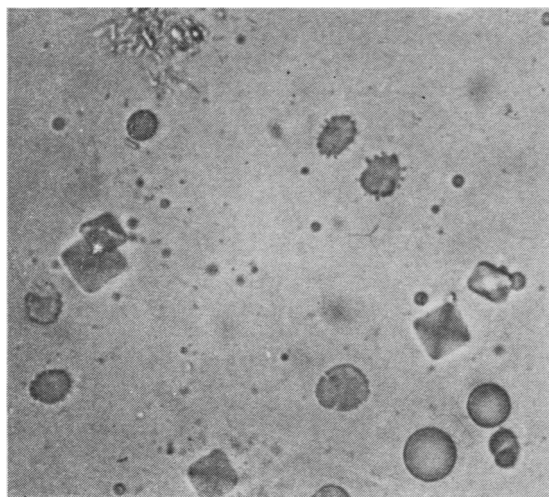


Fig. 5 Synovial fluid containing numerous calcium oxalate and occasional calcium pyrophosphate dihydrate crystals. Polarising microscopy. ($\times 275$).

CASE 2

This patient presented in adult life with repeated fractures and arthritis, and despite some loss of time from work in relation to these acute episodes continues in an active job.

At the age of 53 years he was referred to an orthopaedic surgeon with a 2-year history of episodic pain in the left foot and right great toe. The general practitioner had made a provisional diagnosis of gout and gave treatment on this basis, but x-rays taken at the time of referral to hospital showed evidence of past fractures of the left 2nd and 4th and the right 1st metatarsal bones.

About 2 years later a minor trip on the stairs resulted in a fracture of the right femur, which because of failure to unite required fixation with a Küntscher nail.

A further 2 years later he complained of pain in the left groin, and radiographs showed a partial fracture of the upper third of the left femur (Fig. 6) and evidence of a healed rib fracture that had not caused symptoms. Serum alkaline phosphatase levels were persistently low, 14–17 IU (normal adult range 32–192 IU). Hypophosphatasia was suspected, and this diagnosis was confirmed by the demonstration of an excess of phosphoethanolamine in the urine.

The fracture of the left femur extended and necessitated a pin and plate. Subsequently further fractures have occurred as the result of minimal trauma. A minor twist of the left ankle resulted in a

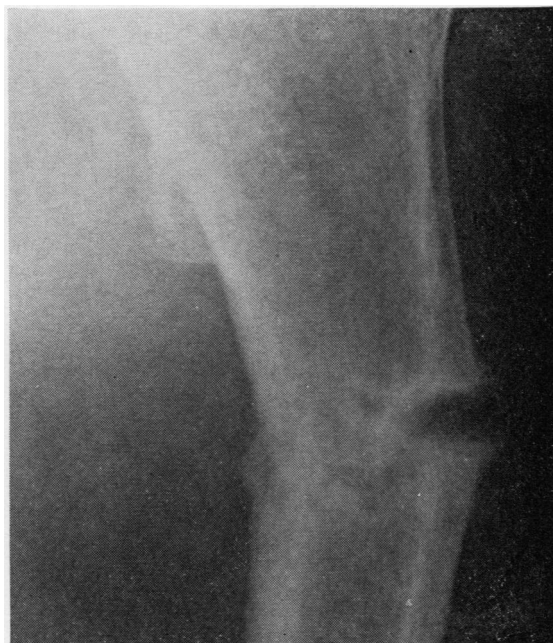

Fig. 6 Case 2. Radiograph of left femur showing partial fracture.

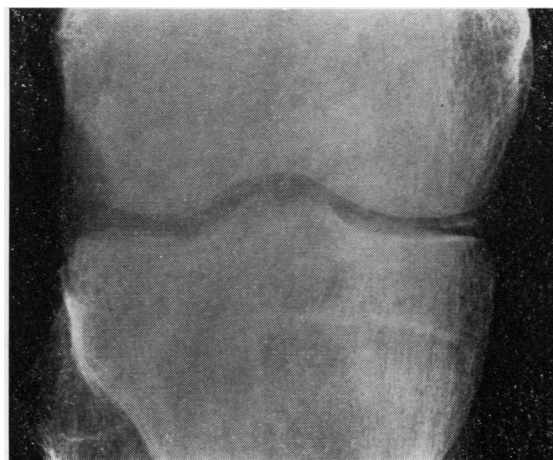

Fig. 7 Case 2. Radiograph of right knee showing clear evidence of chondrocalcinosis.

fracture of the fibula and simple home decorating in a fracture of the metacarpal of the right thumb.

In addition to the pain experienced from the fractures this patient has also experienced attacks of pain relating to the hips and knees. X-rays show changes consistent with chondrocalcinosis in his

shoulders, hips, knees (Fig. 7), and symphysis pubis. The attacks of joint pain have recently become less frequent. Hence an opportunity for joint aspiration has not occurred, and a biopsy of synovium or cartilage has not been justified.

Discussion

The first patient reported here suffered from hypophosphatasia of the severe kind that presents first in infancy. In childhood, when she had already survived much longer than is usual with this type of disease, she developed a polyarthritides associated with calcium pyrophosphate dihydrate crystals in the synovial fluid and chondrocalcinosis. At necropsy in addition to calcium pyrophosphate dihydrate crystals the synovial fluid also contained numerous calcium oxalate crystals. We are unable to offer an explanation for this unexpected finding. Heard¹¹ has reported oxalate crystals in the synovium of an adult suffering from oxalosis, but so far as we are aware they have not been reported in other conditions.

The second patient suffers from hypophosphatasia of the adult type characterised mainly by fractures occurring spontaneously or on minimal trauma. He suffers from an arthritis compatible with that described as 'pseudogout', and radiographs show clear evidence of chondrocalcinosis. Spontaneous and prolonged remission of his arthritis has denied the opportunity to examine synovial fluid for crystals.

There is good evidence that alkaline phosphatase may also act on pyrophosphate as a substrate.¹²⁻¹⁴ Thus in a disease such as hypophosphatasia, where the level of alkaline phosphatase is low, it might be expected that the level of pyrophosphate would be high. Increased levels of pyrophosphate have been demonstrated in the urine¹⁵ and plasma¹⁶ of patients with hypophosphatasia. Nevertheless a high plasma level of pyrophosphate appears unlikely to provide the complete explanation for deposition of crystals in the joints, since in other conditions where there is also a high level of plasma pyrophosphate, such as renal failure, the patients do not appear prone to develop chondrocalcinosis.¹⁷ There have been reports^{16, 18} of reduced pyrophosphatase activity due to a low alkaline phosphatase level in the synovial fluid of patients suffering from gout but possessed of normal plasma alkaline phosphatase levels. Others have not found decreased values.¹⁹

The fact that pseudogout may be associated with many different diseases²⁰ and that chondrocalcinosis may exist in a primary familial form free from disease association^{8, 21} suggests that crystal

deposition of calcium pyrophosphate may represent the end result of a variety of metabolic disturbances.

Hypophosphatasia is a rare disease. Pyrophosphate arthritis in a child is also excessively rare, and, so far as we are aware, when it does occur it is always secondary to another condition. Thus there would seem little doubt that the association between hypophosphatasia and pyrophosphate arthritis is a true one. If this is so then further study of the disease process of hypophosphatasia may provide clues to the pathogenesis of pyrophosphate arthritis. The experiments of nature are often more elegant than those of man.²²

References

- Macey H B. Multiple pseudo-fractures: report of a case. *Mayo Clin Proc* 1940; **15**: 789-91.
- Birtwell W M, Riggs B L, Peterson L F A, Jones J D. Hypophosphatasia in an adult. *Arch Intern Med* 1967; **120**: 90-3.
- Jordan O M, Burney D W, Fink R L. Hypophosphatasia in an adult. *J Bone Joint Surg* 1970; **52A**: 1477-84.
- Rathbun J C. 'Hypophosphatasia': a new developmental anomaly. *Am J Dis Child* 1948; **75**: 822-31.
- McCance R A, Fairweather D V I, Barrett A M, Morrison A B. Genetic, clinical, biochemical and pathological features of hypophosphatasia. *Q J Med* 1956; **25**: 523-37.
- Fraser D. Hypophosphatasia. *Am J Med* 1957; **22**: 730-46.
- McCarty D J, Kohn N N, Faires J S. The significance of calcium phosphate crystals in the synovial fluid of arthritic patients. 'The pseudogout syndrome' 1. Clinical aspects. *Ann Intern Med* 1962; **56**: 711-37.
- Zitnan D, Sit'aj S. Chondrocalcinosis articularis. Section I Clinical and radiological study. *Ann Rheum Dis* 1963; **22**: 142-52.
- McCarty D J. Calcium pyrophosphate dihydrate crystal deposition disease—1975. *Arthritis Rheum* 1976; **19**: 275-85.
- O'Duffy J D. Hypophosphatasia associated with calcium pyrophosphate dihydrate deposits in cartilage. *Arthritis Rheum* 1970; **13**: 381-7.
- Heard B E. Oxalosis in an adult. *Br Med J* 1961; **ii**: 637-43.
- Sussman H H, Laga E. Inorganic pyrophosphatase activity of human placental alkaline phosphatase. *Biochim Biophys Acta* 1968; **151**: 281-3.
- Nordlie R C, Arion W J. Evidence for the common identity of glucose phosphatase, inorganic pyrophosphatase and pyrophosphate-glucose phosphotransferase. *J Biol Chem* 1964; **239**: 1680-5.
- Stetten M R, Taft H L. Metabolism of inorganic pyrophosphate II. The probable identity of microsomal inorganic pyrophosphatase, pyrophosphate phosphotransferase, and glucose-6 phosphatase. *J Biol Chem* 1964; **239**: 4041-6.
- Russell R G G. Excretion of inorganic pyrophosphate in hypophosphatasia. *Lancet* 1965; **ii**: 461-4.
- Russell R G G, Bisaz S, Fleisch H. Inorganic pyrophosphate in plasma, urine and synovial fluid of patients with pyrophosphate arthropathy (chondrocalcinosis or pseudogout). *Lancet* 1970; **ii**: 899-902.

- ¹⁷ Russell R G G. Metabolism of inorganic pyrophosphate (PPi). *Arthritis Rheum* 1976; **19**: 465–78.
- ¹⁸ Yaron M, Zurkowski P, Weiser H I, Yust I, Goldschmied A, Hermann E. Pseudogout with low levels of alkaline phosphatase in the synovial fluid. *Ann Intern Med* 1970; **73**: 751–6.
- ¹⁹ McCarty D J, Solomon S D, Warnock M L, Paloyan E. Inorganic pyrophosphate concentrations in the synovial fluid of arthritic patients. *J Lab Clin Med* 1971; **78**: 216–29.
- ²⁰ Hamilton E B D. Diseases associated with C.P.P.D. deposition disease. *Arthritis Rheum* 1976; **19**: 353–7.
- ²¹ Korst J K van der, Geerards J, Driessens F C M. A hereditary type of idiopathic articular chondrocalcinosis. Survey of a pedigree. *Am J Med* 1974; **56**: 307–14.
- ²² Garrod A E. The Croonian lectures on inborn errors of metabolism. *Lancet* 1908; **ii**: 214–20.