

Proteinuria in rheumatoid arthritis—drug-induced or amyloid?

B. E. BOURKE, D. F. WOODROW, AND J. T. SCOTT

From Charing Cross Hospital, London W6

SUMMARY Over a 5-year period 325 patients with rheumatoid arthritis received treatment with gold (162) or D-penicillamine (163). Thirty-eight (11.7%) developed proteinuria, which persisted in 10 patients; renal biopsies in these 10 patients revealed 6 cases of amyloid disease. These 6 cases illustrate the importance of investigation of rheumatoid patients developing proteinuria even when they are receiving potentially nephrotoxic drugs.

Secondary amyloidosis is a well known complication of rheumatoid arthritis, usually coming to attention when proteinuria or impaired renal function are noticed. Reports of its incidence vary with the selection of patients and the methods of detection employed. Arapakis and Tribe¹ found a 5% incidence of amyloid on rectal biopsy in an unselected group of patients with rheumatoid disease of greater than 3 years' duration. Malstrom² found amyloid in 19% of specimens of periapical dental tissue from another unselected group of rheumatoid patients. Missen and Taylor,³ reviewing several collected series of necropsy studies on rheumatoid patients, found a 14% incidence of renal involvement. In all these studies the diagnosis was made by Congo red staining, with further confirmation from thioflavine T or methyl violet. The usual sites for biopsy are kidney, liver, gingiva, or rectal mucosa, while Westermark and Stenkvist⁴ have successfully used subcutaneous fat aspirates to diagnose secondary amyloidosis.

Proteinuria in rheumatoid arthritis, however, also commonly occurs as a complication of gold or D-penicillamine therapy. We report our experience over a 5-year period in patients with rheumatoid arthritis receiving antirheumatic therapy with gold or penicillamine under hospital supervision.

Patients and methods

A retrospective analysis was carried out from the records of all patients with rheumatoid arthritis

Accepted for publication 10 July 1980.
Correspondence to Dr J. T. Scott, Kennedy Institute of Rheumatology, Bute Gardens, London W6 7DW.

undergoing supervision of therapy with gold or penicillamine at Charing Cross Hospital between 1974 and 1979. During this 5-year period 162 patients received gold and 163 patients received D-penicillamine, the individual duration of therapy varying between 2 months and 5 years. Although the individual dosage schedule was controlled independently by the supervising physician, those patients receiving gold were usually treated with intramuscular injections of sodium aurothiomalate 50 mg weekly up to a total dose of 1 g or less if clinical remission was achieved earlier, and thereafter reduced to a maintenance dosage of 20 to 50 mg monthly. In the case of penicillamine therapy patients were usually started on 125 mg of the drug daily, with 125 mg increments at fortnightly intervals up to a maximum dose of 750 mg per day, although the majority received a maximal dose of 500 mg per day. All patients receiving gold or penicillamine had routine urine analysis performed at intervals varying from 1 week to 1 month. When proteinuria was detected by stick testing, quantitative estimations were performed by the standard reaction with biuret reagent (an alkaline 0.02% cupric sulphate solution). Drug therapy with gold or penicillamine was modified by the supervising clinician, but in most cases uncomplicated proteinuria of greater than 1.0 g per 24 hours was considered to be a sufficient reason in itself for withdrawal of the drug, at least temporarily.

Renal biopsies were performed under local anaesthetic with the patient in the prone position, under image intensifier control, specimens being obtained with a Tru-cut disposable biopsy needle. Biopsy specimens obtained from patients were

processed and examined by both light and electron microscopy and by direct immunofluorescence as previously described.⁵ In all cases the investigation for amyloid consisted of Congo red staining with apple green birefringence in polarised light, ultraviolet fluorescence with thioflavine T, and ultrastructural examination to demonstrate the presence of extracellular, randomly arranged, fine non-branching filaments of 8–10 nm in diameter.

At the time of biopsy serum and urinary protein, blood urea, and plasma creatinine were estimated in the routine chemical pathology laboratories by AutoAnalyzer techniques.

Results

Thirty-eight patients (11.7%) out of the total 325 patients included in the study developed proteinuria; 23 were receiving penicillamine and 15 gold. The dosage and duration of therapy were not significantly different in these patients from the group as a whole.

Initially the proteinuria was attributed to the therapy, but in the case of 10 patients it was persistent and in some associated with evidence of diminished glomerular filtration rate. Renal biopsies were therefore undertaken at periods ranging from two to 36 months after the development of proteinuria and the cessation of therapy. The clinical features of the 10 patients in whom biopsies were performed are summarised in Table 1. At the time of biopsy all but 1 had proteinuria of greater than 1 g per 24 hours, the exception being patient 4, who had considerable elevation of plasma creatinine and blood urea, and in whom there was a long history of

chronic urinary infection and impaired renal function. Two other patients at the time of biopsy had raised levels of blood urea and plasma creatinine (9 and 10).

RENAL BIOPSY FINDINGS

Six of the 10 patients were found to have amyloidosis, confirmed in all by Congo red and thioflavin T staining. In 5 of these 6 patients electron microscopy was also confirmatory (Fig. 1), while in the sixth case (patient 6), although there was increased mesangial matrix, no filamentous amyloid could be demonstrated. By light microscopy amyloid deposits were found in the glomeruli of all 6 patients and in the interstitium and arteriolar walls of 3 patients.

Of the 4 remaining patients 3 had evidence of an immune complex glomerulonephritis (1, 2, and 3) with granular deposits of IgG, C1q, and C3 along the glomerular capillary loops. In 2 of these cases (1 and 3) the electron microscopic changes of small subepithelial electron dense deposits characteristic of an early membranous glomerulonephritis (Fig. 2), while in the third (patient 2), the lesion was difficult to classify, as the glomeruli were normal by light microscopy and no glomeruli were present in samples prepared for electron microscopy. The biopsy findings in the remaining patient (4) revealed evidence of a chronic interstitial nephritis; this patient had a known history of chronic urinary infections. In one patient (1) a urate tophus was found in the renal medulla, a surprising and presumably incidental finding.

The subsequent progress of the patients with amyloid is summarised in Table 2, the maximum duration of follow-up being 4 years.

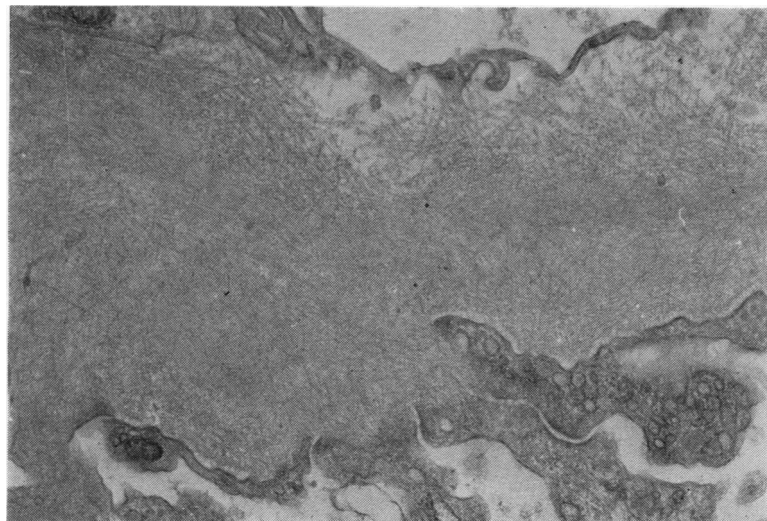


Fig. 1 Electron micrograph of thickened glomerular basement membrane showing the randomly arranged fine filaments of amyloid throughout its thickness. (Uranyl acetate, Reynolds lead citrate, $\times 16\ 700$) (patient 8).

Table 1 Details of 10 patients undergoing renal biopsy following antirheumatic therapy

Patient	Age	Duration of disease	Anti-rheumatic therapy	Duration of therapy (total dose)	Blood urea mmol/l	Plasma creatinine μ mol/l	Creatinine clearance ml/min	Proteinuria g/24 h	Duration of proteinuria	Renal biopsy findings
1	48	16 yr	D-pen	6 months	7.0	95	70	2.5	2 months	Membranous glomerulonephritis
2	59	15 yr	D-pen	12 months	5.5	59	53	7.4	3 months	Membranous glomerulonephritis
3	53	18 yr	D-pen	8 months	3.5	70	53	1.8	4 months	Membranous glomerulonephritis
4	73	18 yr	D-pen	15 months	18.1	338	11	Trace	7 months	Chronic interstitial nephritis
5	36	16 yr	Gold	(130 mg)	4.4	95	122	12.6	6 months	Amyloid
6	60	8 yr	D-pen	11 months	3.4	118	62	2.1	4 months	Amyloid
7	56	6 yr	Gold	(550 mg)	6	95	85	4.4	36 months	Amyloid
8	66	10 yr	Gold	(2380 mg)	5.6	70	52	1.6	12 months	Amyloid
9	58	26 yr	Gold	(100 mg)	14.0	225	22	8.1	2 months	Amyloid
10	69	14 yr	D-pen	3 years	14.9	296	16	1.1	18 months	Amyloid

Table 2 Details of the 6 patients at time of diagnosis of amyloid and at subsequent follow-up

Patient	Age	Sex	Duration of RA	Drug therapy	At time of renal biopsy			At follow-up		
					Creatinine clearance ml/min	Proteinuria g/24 h	Subsequent therapy	Subsequent follow-up	Creatinine clearance ml/min	Proteinuria g/24 h
5	36	M	16 yr	Gold 130 mg Prednisolone D-pen 11/12	122	12.6	Prednisolone Azathioprine	1 yr	9	32
6	60	F	8 yr	NSAIDs* Gold 550 mg	62	2.1	NSAIDs*	4 yr	10	1.9
7	56	F	6 yr	Prednisolone Gold 2380 mg	85	4.4	Prednisolone	4 yr	55	Trace
8	66	F	10 yr	NSAIDs	52	1.6	Azathioprine	1 yr	32	3 g
9	58	F	26 yr	Gold 100 mg Prednisolone	22	8.1	Azathioprine	9 months	20	6 g
10	69	F	14 yr	D-pen 3 yr	16	1.1	Azathioprine	3 months	19	1.0

*NSAID = nonsteroidal anti-inflammatory drug.

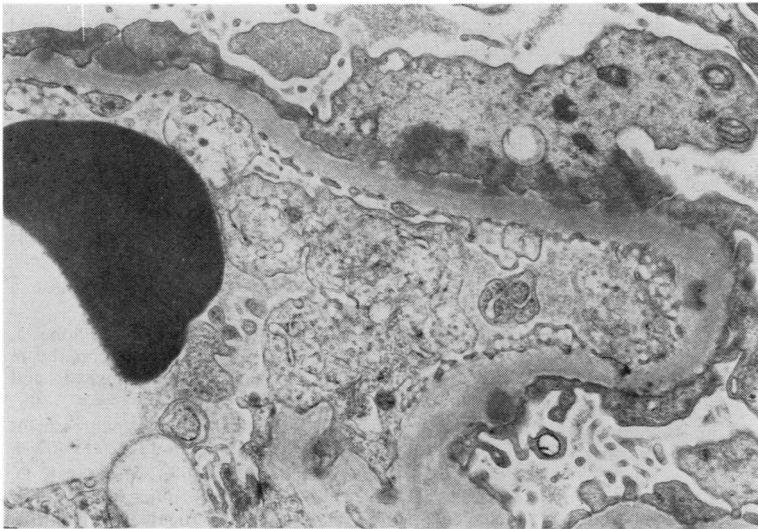


Fig. 2 Electron micrograph of a glomerular capillary loop showing small discrete subepithelial cell electron dense deposits within the basement membrane. (Uranyl acetate, Reynolds lead citrate. $\times 10\ 400$) (patient 1).

Discussion

The 6 cases of secondary amyloidosis came to light initially because frequent regular tests for proteinuria were being performed. The proteinuria was initially attributed to drug therapy, but its persistence after drug withdrawal led to subsequent investigation and ultimately to the diagnosis of amyloid. These 6 patients all had classical or definite rheumatoid arthritis without any history of tuberculous or other chronic infection apart from patient 8, who had a history of an infected hip prosthesis lasting 6 months some 5 years prior to diagnosis of amyloid.

Secondary amyloidosis is a potentially fatal complication of rheumatoid arthritis, and is more likely to occur in severe or chronic forms of the disease. The course of amyloid is variable, but may be influenced by treatment of the primary disease.⁶ Patients 6 and 7, followed up over 4 years and treated only with prednisolone and nonsteroidal anti-inflammatory drugs, have developed mild deterioration of glomerular filtration rate, while proteinuria has diminished. The other 4 patients have been treated with azathioprine, but follow-up has been short; 1 of them rapidly developed severe renal failure (patient 5), another has shown a significant fall in glomerular filtration rate (8), and the remaining 2 patients (9 and 10) have maintained their already compromised renal function.

The relationship between the development of amyloid to the drugs is uncertain and probably coincidental. There is no evidence that gold or penicillamine lead to the production or deposition of amyloid; in fact if treatment of the underlying

disease inhibits amyloid formation, it would be expected that these drugs would prevent rather than encourage secondary amyloid deposition.

In this series the incidence of proteinuria with penicillamine was 14.1%, which is similar to that in other recent series.^{7,8} The incidence with gold was 9.2%, again in accordance with other series. Three of the 10 patients with persistent proteinuria had an immune complex glomerulonephritis consistent with a penicillamine induced nephropathy. Drug induced proteinuria may persist for a variable time after cessation of gold or penicillamine, and durations of 1 year or more are reported with the latter drug.^{7,9} However, in view of the findings reported here, it is clear that the possibility of amyloid should be considered if proteinuria in these patients does not disappear within, say, 3 months. Also of importance was evidence of considerably impaired glomerular filtration rate in some of the amyloid patients when proteinuria was first noted. This feature is not normally associated with gold or D-penicillamine induced nephropathy, and therefore appears to favour the diagnosis of amyloid.

In the series of Bacon *et al.*⁸ no cases of amyloid were found on renal biopsy in 14 patients who developed proteinuria on penicillamine, but in a recent series Stockman *et al.*¹⁰ found 1 case of renal amyloid from 6 patients on penicillamine undergoing renal biopsy for proteinuria.

Over the 5-year period of this study only 1 other case of amyloidosis complicating rheumatoid arthritis came to light. It seems therefore that regular urine testing performed because of the known nephrotoxic effects of these drugs was the

most important factor leading to the ultimate diagnosis of amyloid and stresses the importance of urine testing in all severe or chronic rheumatoid patients. This study also underlies the importance of early investigation of rheumatoid patients developing proteinuria even while on treatment with nephrotoxic drugs.

We are grateful to members of the Renal Unit at Charing Cross Hospital for their collaboration in the assessment of these patients and for performing the renal biopsies, to Mrs Jill Moss for the electron microscope studies, and to Dr R N Maini for permission to report some of these patients who were under his care.

References

- ¹ Arapakis G, Tribe C R. Amyloidosis in rheumatoid arthritis investigation by means of rectal biopsy. *Ann Rheum Dis* 1963; **22**: 256-62.
- ² Malstrom M. The nature of the inflammatory process in the teeth supporting tissues of patients with rheumatoid disease. *Scand J Rheumatol* 1975; Suppl 6: 1-28.
- ³ Missen G A K, Taylor J D. Amyloidosis in rheumatoid arthritis. *J Pathol Bacteriol* 1956; **71**: 179-92.
- ⁴ Westermark P, Stenkvist B. A new method for the diagnosis of systemic amyloidosis. *Arch Intern Med* 1973; **132**: 522-3.
- ⁵ Rainford D J, Woodrow D F, Sloper J C, de Wardener H E, Griffiths I. Post meningococcal acute glomerular nephritis. *Clin Nephrol* 1978; **9**: 249-53.
- ⁶ Parkins R A, Bywaters E G L. Regression of amyloidosis secondary to rheumatoid arthritis. *Br Med J* 1959; **i**: 536-40.
- ⁷ Huskisson E C. Penicillamine and the rheumatologist: a review. *Pharmatherapeutica* 1976; **1**: 24-39.
- ⁸ Bacon P A, Tribe C R, Mackenzie J C, Verrier Jones J, Cumming R H, Amer B. Penicillamine nephropathy in rheumatoid arthritis. A clinical, pathological and immunological study. *Q J Med* 1976; **45**: 661-84.
- ⁹ Huskisson E C, Hart F D. Penicillamine in the treatment of rheumatoid arthritis. *Ann Rheum Dis* 1972; **21**: 402-4.
- ¹⁰ Stockman A, Richter D, Barraclough D, Muirden K D, Macdonald I, Kincaid-Smith P. Difficulties in the use of D-penicillamine in the treatment of rheumatoid arthritis. *Aust NZ J Med* 1979; **9**: 495-503.