



A 3D-engineered silicone stent to treat a refractory bronchopleural fistula

Copyright ©The authors 2023

This version is distributed under the terms of the Creative Commons Attribution Non-Commercial Licence 4.0. For commercial reproduction rights and permissions contact permissions@ersnet.org

Received: 5 Dec 2022
Accepted: 29 Dec 2022

To the Editor:

Bronchopleural fistula (BPF) is a rare but life-threatening event complicating lung resection in ~1.8% of cases and can be hard to manage [1]. When BPF is refractory, open-window thoracostomy (OWT) is one of the possible treatment options. OWT can have some major debilitating side-effects and sometimes never be closed [2]. Innovative endoscopic techniques have been described to aid healing the BPF [3]. Many have specificities that hinder their applicability to other BPF locations or sizes. We present here a promising case of successful insertion of a 3D-engineered silicone stent to plug a thoracostomy-treated chronic BPF causing dysphonia.

The patient was a 78-year-old man with a history of pT1N0 squamous cell lung cancer treated with a right lower lobectomy 2 years previously. Numerous infectious complications ensued and a BPF developed. Despite standard care, a residual large chronic BPF developed at the bronchus intermedius site, with a right middle lobe obstructed by the post-operative change in conformation. The patient benefited from an OWT 1 month later as salvage therapy. In part due to recurrent bronchial infections with antibiotic-resistant microorganisms, it had not yet been closed. Given the size of the fistula of ~13 mm and trouble keeping the area airtight with frequent dressing change, the patient presented with complaints of major dysphonia, with air passing through the fistula instead of through the larynx. For reasons that will be discussed below, the patient was offered the insertion of a 3D-engineered silicone stent covering the fistula.

This type of stent was previously demonstrated as feasible in a proof-of-concept study [4]. Computer-assisted modelling of the airways was performed from a fully inspired computed tomography (CT) scan to virtually correct the anomaly. A virtual Oki-like stent (Novatech, France) with an occluded distal end and corresponding mould were designed. The data were then entered in a 3D printer to manufacture the mould in Ertacetal (AnatomikModeling, France). Medical-grade silicone was injected in the mould to manufacture the stent (Novatech, France). The thickness of the stent was set to 1.5 mm, based on previous experience of the radial force needed. It was then sterilised and inserted in the airways under rigid bronchoscopy, like a usual silicone stent.

The endoscopic and radiological results were satisfying (figure 1). The dysphonia was instantly corrected and the patient suffered no immediate complication. The patient was discharged the day following the procedure. At 6-month follow-up, he was still doing well, with only one episode of bronchial infection treated with antibiotics, as he is now accustomed to. He has not needed any aspiration flexible bronchoscopy since insertion. Given the scarred OWT and recurrent infections, it is unlikely the patient will ever have it closed. The patient will be followed up regularly to assess tolerance of the stent and evolution to see if permanent closure is an option.

To our knowledge, this is the first reported case of a 3D-engineered silicone stent insertion to correct a BPF. Other endoscopic techniques have been described to successfully correct a BPF, depending on size and location. For very small BPFs, chemical agents like adhesives and sealants can be used. For small BPFs, one-way endobronchial valves have been used successfully. KESHISHYAN *et al.* [5] listed >100 patients benefitting from this procedure in mostly retrospective studies. The main limitation is size, with the largest valve covering a hole ~8 mm in diameter. Another device using a similar approach is the Watanabe spigot (EWS; Novatech, France). Shaped as a silicone barrel, it is inserted in the culprit segment to block the airflow. Unfortunately, it is also only available in sizes from 5 to 7 mm in diameter.



Shareable abstract (@ERSpublications)

A novel 3D-engineered silicone stent was successfully used to treat a refractory bronchopleural fistula of the right lower lobe in a patient with an open-window thoracostomy who complained of severe dysphonia and recurrent infections <https://bit.ly/3GrKs2p>

Cite this article as: Roy P, Héluain V, Leyx P, *et al.* A 3D-engineered silicone stent to treat a refractory bronchopleural fistula. *ERJ Open Res* 2023; 9: 00670-2022 [DOI: 10.1183/23120541.00670-2022].



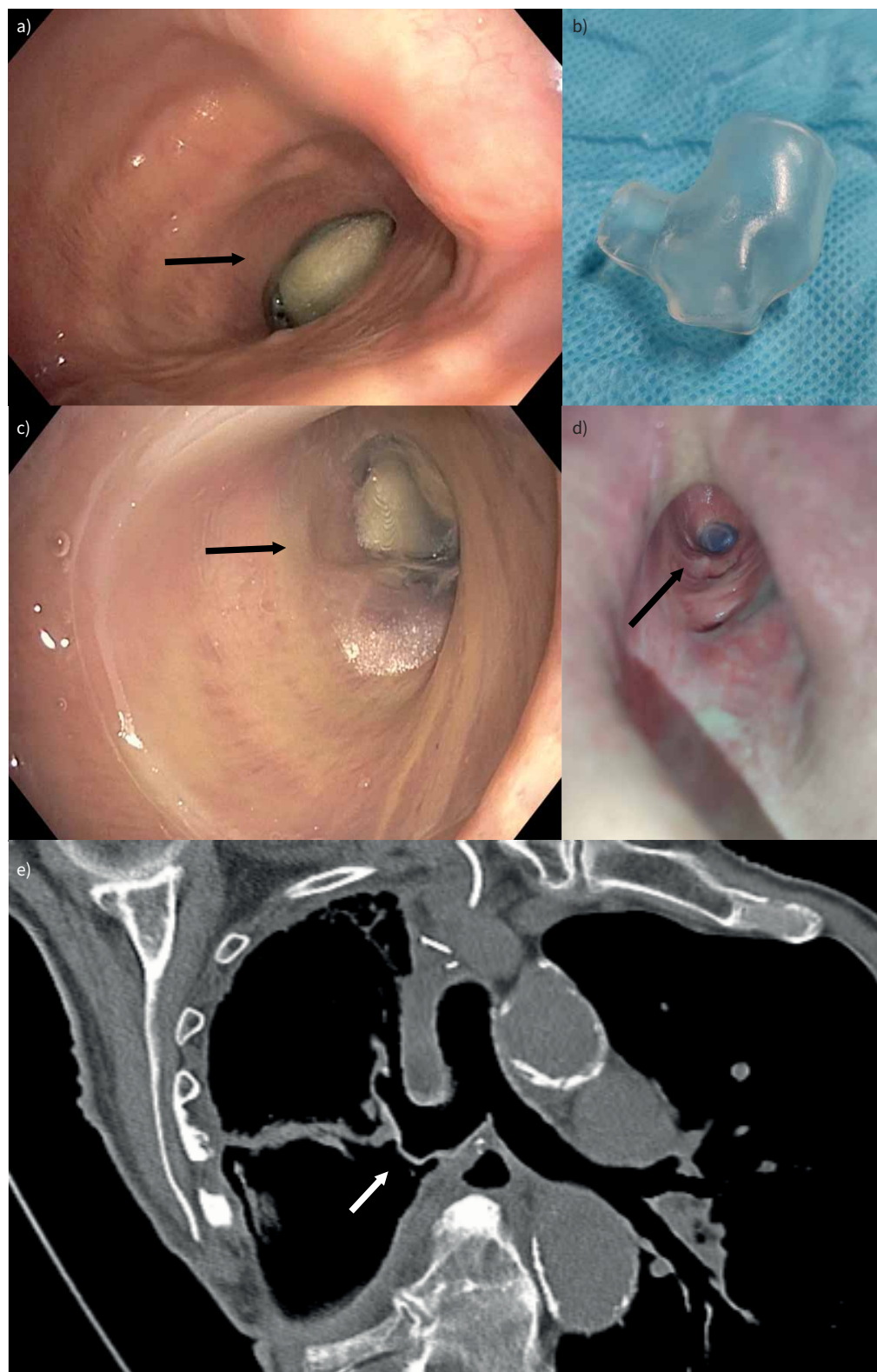


FIGURE 1 a) Endobronchial view of the fistula before stent insertion, showing a gauze in the opening. b) Customized silicone stent using 3D reconstruction of a computed tomography scan. c) Endobronchial and d) thoracostomy views of the fistula after stent insertion, covering the fistula without occluding the right upper lobe. e) Computed tomography image showing perfect fit of the customised stent, covering the fistula.

Amplatzer atrioseptal defect-occluding devices represent another technology repurposed to close BPFs. Some case series from multiple centres describe its successful use to close both small and large BPFs [6]. It was not accessible for our case but we also doubt the conformation of the bronchus and OWT would have allowed the device to hold in place properly.

Similarly to our case, other authors have described the use of stents to cover BPFs. Some bronchial locations can be intrinsically covered by commercially available stents. For the remainder, stents need to be adjusted. HAN *et al.* [7] published a case series of 148 successful insertion of modified covered metallic stents for patients with BPF. These stents were manufactured specifically for the patients' bronchial anatomy, using CT scan and bronchoscopy measurements. In about half of them, the stent was removed following cure. In ~40% of patients, the stent was removed due to granulation tissue proliferation compromising breathing or stent damage, showing room for improvement of the stent design. Given the expected long-term need for a stent in our patient, a stent prone to granulation and damage was not a proper choice. Another Chinese group showed some success after inserting 17 manually modified silicone stents for patients with early stage BPF [8]. Though very ingenious, the length of silicone tubing necessary to make sure it is stable in the airways makes it more appropriate for short-term treatment, as was the case in their patients, given the higher risk of plugging and bothersome symptoms.

In conclusion, 3D-engineered silicone stents might be a new tool of the endoscopist for BPF treatment. This unique case will allow further trials in other patients and, if successfully reproduced, could be offered more widely eventually. Its main advantages could be to fit almost any type and location of BPF, and to reduce granulation tissue proliferation risk, its easy removal and insertion, and the reduced length of silicone necessary to be stable in the airways.

Pascal Roy^{1,2}, Valentin Héluain¹, Pierre Leyx³, Thomas Villeneuve¹, Romain Vergé⁴, Laurent Brouchet^{4,5} and Nicolas Guibert^{1,5}

¹Pulmonology Department, Larrey Hospital, University Hospital of Toulouse, Toulouse, France. ²Department of Pulmonary Medicine, Institut Universitaire de Cardiologie et de Pneumologie de Québec, Québec, Canada. ³AnatomikModeling Society, Toulouse, France. ⁴Thoracic Surgery Department, Larrey Hospital, University Hospital of Toulouse, Toulouse, France. ⁵University of Toulouse III (Paul Sabatier), Toulouse, France.

Corresponding author: Nicolas Guibert (guibert.n@chu-toulouse.fr)

Provenance: Submitted article, peer reviewed.

Conflict of interest: The authors have no conflict of interest to declare.

Support statement: P. Roy received a grant from the Fondation IUCPQ, his affiliate hospital, to support his fellowship at Larrey Hospital.

References

- 1 Okuda M, Go T, Yokomise H. Risk factor of bronchopleural fistula after general thoracic surgery: review article. *Gen Thorac Cardiovasc Surg* 2017; 65: 679–685.
- 2 Shamji FM, Ginsberg RJ, Cooper JD, *et al.* Open window thoracostomy in the management of postpneumonectomy empyema with or without bronchopleural fistula. *J Thorac Cardiovasc Surg* 1983; 86: 818–822.
- 3 Bertolaccini L, Bonfanti B, Kawamukai K, *et al.* Bronchoscopic management of prolonged air leak. *J Thorac Dis* 2018; 10: Suppl. 27, S3352–S3355.
- 4 Guibert N, Didier A, Moreno B, *et al.* Treatment of complex airway stenoses using patient-specific 3D-engineered stents: a proof-of-concept study. *Thorax* 2019; 74: 810–813.
- 5 Keshishyan S, Revelo AE, Epelbaum O. Bronchoscopic management of prolonged air leak. *J Thorac Dis* 2017; 9: S1034–S1046.
- 6 Fruchter O, Kramer MR, Dagan T, *et al.* Endobronchial closure of bronchopleural fistulae using Amplatzer devices: our experience and literature review. *Chest* 2011; 139: 682–687.
- 7 Han X, Yin M, Li L, *et al.* Customized airway stenting for bronchopleural fistula after pulmonary resection by interventional technique: single-center study of 148 consecutive patients. *Surg Endosc* 2018; 32: 4116–4124.
- 8 Zeng J, Wu X, Chen Z, *et al.* Modified silicone stent for the treatment of post-surgical bronchopleural fistula: a clinical observation of 17 cases. *BMC Pulm Med* 2021; 21: 10.