

Influence of *x*-ray treatment on antigen-induced experimental arthritis

C. STEFFEN, CH. MÜLLER, K. STELLAMOR, AND J. ZEITLHOFER

From the Institute of Immunology, University of Vienna, Röntgeninstitut Krankenhaus Rudolfstiftung, and Pathologisches Institut, Kaiser-Franz-Joseph-Spital, Vienna

SUMMARY Six groups of 3 rabbits each were immunised with ovalbumin and received one intra-articular injection of antigen. The animals of 3 groups received local *x*-ray irradiation of 600 rads for 8 minutes to the right knee joint 12 days after the intra-articular challenge. Animals of the other 3 groups were not irradiated. The antigen-induced arthritis was investigated by determining the exudation in synovial fluid and by histological study of the synovium examined 48 hours, 7 days, and 4 weeks after the irradiation date. All animals in the nonirradiated groups showed a distinct chronic synovitis. Irradiated animals showed almost no synovitis 48 hours and 7 days following irradiation. In 2 rabbits synovitis had reappeared 4 weeks after irradiation with findings similar to those in the control groups. Only one animal still showed an inhibition of synovitis. *X*-ray irradiation of non-challenged knees did not induce any pathological changes. This time-limited effect of one local irradiation on antigen-induced arthritis seems to be mainly an anti-inflammatory action. Local immunological inhibition might possibly operate too. *X*-ray induced inhibition of synovitis is compared with the effect of locally injected radiocolloids.

Approaches to the local treatment of rheumatoid joints have included intra-articular injections of corticosteroids, cytostatic compounds, osmic acid, and radiocolloids. Claims have been made for the lasting benefit of intra-articular irradiation by radiocolloids such as yttrium-90.¹ The application of the latter therapy is, however, limited by possible side effects as well as leakage of radioactivity into the surrounding tissues of the joint and the need to restrict its use to older patients. Numerous reports have been published on the clinical application of synoviorthesis with radiocolloids, but only a few data relate to its effects in experimental arthritis such as antigen-induced arthritis²⁻³ or adjuvant arthritis.⁴ It seems surprising, furthermore, that intra-articular irradiation by radiocolloids has received so much attention to the relative neglect of studies on the treatment of rheumatoid arthritis⁵⁻⁷ or experimental arthritis⁸ with local *x*-ray irradiation. To obtain information about the effect of local *x*-ray irradiation on arthritis we have treated antigen-induced experimental arthritis⁹ of rabbit knee joints with locally applied *x*-rays. The effects were investigated cytologically in the synovial fluid and histologically in the synovium.

Material and methods

Animals. Random bred rabbits weighing from 2.0-2.5 kg were immunised with 1.0 ml of a mixture of identical volumes of 1 mg ovalbumin per ml phosphate-buffered saline (PBS) and complete Freund's adjuvant subcutaneously, divided between 4 sites on the back. Two weeks later 0.5 ml of 1 mg ovalbumin per ml PBS was injected intraperitoneally. This procedure was repeated after 14 days. Five days later the animals were bled and the antiovalbumin titre of the serum determined by passive haemagglutination.

Experimental procedure. Immunised rabbits showing by passive haemagglutination a titre of antiovalbumin from 1:100 000 to 1:1 000 000 were divided into 6 groups of 3 animals, and each received an intra-articular injection of 0.5 ml of 1 mg ovalbumin per ml PBS into the right knee joint and 0.5 ml PBS into the left knee.

The animals in groups 2, 4, and 6 received *x*-ray irradiation 12 days after the intra-articular challenge; animals in groups 1, 3, and 5 did not receive *x*-rays. The animals in group 1 and 2 were killed 48 hours after irradiation (14 days after challenge), those in group 3 and 4 one week after irradiation (19 days after challenge), and those in groups 5 and 6 four weeks after irradiation (40 days after challenge).

Controls. Nonimmunised rabbits were divided into 2 groups of 3 animals each (groups 7, 8) and received an identical intra-articular challenge as well as x-ray treatment. The animals in group 7 were killed 48 hours and those of group 8 one week after irradiation.

Intra-articular challenge. 0.5 ml of 1 mg ovalbumin per ml PBS or 0.5 ml PBS alone was injected lateral to the patellar tendon into the joint cavity. The area was shaved and sterilised with alcohol prior to injections. The antigen solution was centrifuged for 30 minutes at 5000 g prior to injection; its supernatant and the PBS controls were sterilised by filtration (sterile Sartorius-Membranfilter SM 1375650, 0.45 µm).

Irradiation. A deep x-ray therapy tube was used for the irradiation of the right knee. The popliteal area received a surface dose of 6 Gy (600 rads) at 0.5 mm Cu-filtration for 8 minutes 180 kV tube voltage, 12 mA tube rating, and a focus-skin-distance of 40 cm. This irradiation corresponded to 12.5 mGy/s (1.25 rads/s) or 750 mGy/min (75 rads/min). With the exception of the irradiated area the entire body of the animal was protected by lead shielding.

Investigation. Under sodium pentothal anaesthesia the joint was injected with 0.5 ml of sterile saline plus 0.05 ml Liquaemin (5000 IU heparin/ml) and as much fluid as possible was aspirated. Animals were subsequently killed with sodium pentobarbitone.

With the patellar tendon dissected and retracted distally the joint capsule was exposed and opened. Under compression of the knee joint residual joint fluid was aspirated. The 2 specimens were pooled for volume measurement, and after thorough mixing duplicate white cell counts were performed using Türk solution. From this the total number of cells in the aspirate was calculated.

Histological investigations. After aspiration of synovial fluid the synovial membranes were fixed for 3 days in 10% aqueous formaldehyde solution and embedded in paraffin. Sections 4 µm thick were stained with haematoxylin-eosin and by van Gieson's method with simultaneous elastin stain.

Results

Immunised animals. Table 1 shows the cellular exudation into the synovial fluid and the histological changes in immunised animals (groups 1-6).

PBS control joints. Animals in all groups which had received an intra-articular injection of PBS showed no cells or only a minimal number (10 000-125 000) in the synovial fluid, which corresponds to controls in earlier experiments.^{10 11} The histology of the synovial membranes in the PBS controls showed no pathological changes (Fig. 1 I) in irradiated or nonirradiated animals.

Table 1 Immunised rabbits: comparison of synovial fluid cell counts and synovial histology in antigen-injected right knee and PBS-injected left knee, at varying intervals and with or without X-ray irradiation

Group	Animal	Interval*	Left knee (PBS control)			Right knee (antigen injected)		
			Irradiation	Syn. fluid cells	Histology	Irradiation	Syn. fluid cells	Histology
1	1	48h	No x-rays	—	No pathological findings	No x-rays	100 000	Proliferation of synovial cell layer, oedema, hyperaemia, dense diffuse infiltration of granulocytes plasma cells, fewer lymphocytes, rarely eosinophils and mononuclear cells
	2		"	—		"	60 000	
	3		"	10 000		"	400 000	
2	20	48h	600 r	—	"	600 r	300 000	Synovial cell layer smooth, slight oedema, some immature fibroblasts, only slight focal infiltration with plasma cells, rarely lymphocytes
	14		"	25 000	"	"	100 000	
	15		"	125 000	"	"	180 000	
3	4	7 days	No x-rays	—	"	No x-rays	60 000	Identical to group 1
	5		"	10 000	"	"	45 000	
	6		"	—	"	"	30 000	
4	16	7 days	600 r	—	"	600 r	45 000	Identical to group 2
	18		"	—	"	"	30 000	
5	7	4 weeks	No x-rays	—	"	No x-rays	50 000	Proliferation of synovial cell layer, distinct dense infiltration with plasma cells and lymphocytes, less pronounced mononuclear cells, eosinophils
	8		"	22 500	"	"	15 000	
	9		"	—	"	"	60 000	
6	13	4 weeks	600 r	15 000	"	600 r	10 000	Identical to group 2
	19		"	40 000	"	"	140 000	
	21		"	20 000	"	"	250 000	

*Time of investigation after date of irradiation. PBS=phosphate-buffered saline.

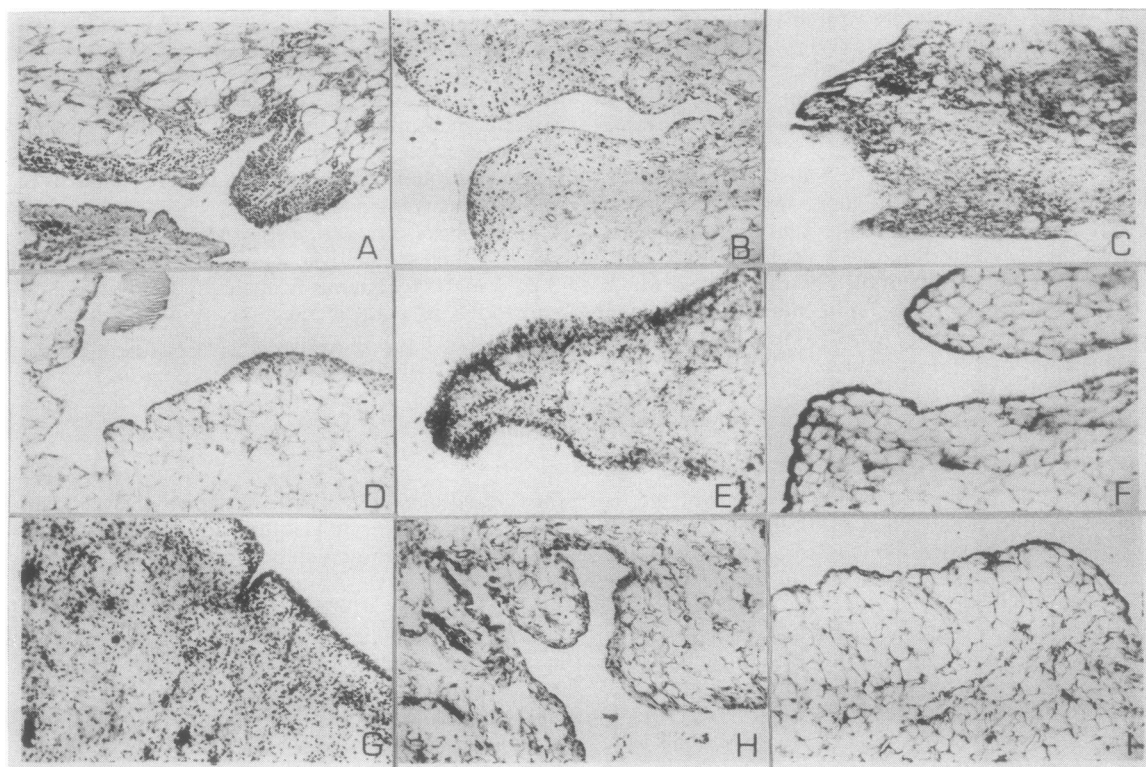


Fig. 1 Histological appearances of knee joint synovium. Following immunisation with ovalbumin all animals received an intra-articular challenge with either antigen or PBS (control) on day 0. X-ray irradiation either was or was not administered on day+12.

A: day+14. Antigen-challenged, nonirradiated right knee joint showing active arthritis (group 1). B: day+14. Antigen-challenged, irradiated right knee (48 hours after irradiation); inhibition of arthritis (group 2). C: day+19. Antigen-challenged, nonirradiated right knee; arthritis present (group 3). D: day+19. Antigen-challenged, irradiated right knee (7 days after irradiation) inhibition of arthritis (group 4). E: day+40. Antigen-challenged, nonirradiated right knee; arthritis present (group 5). F: day+40. Antigen-challenged, irradiated right knee (4 weeks after irradiation) inhibition of arthritis (group 6, no. 13). G: day+40. Antigen-challenged, irradiated right knee; reappearance of arthritis (4 weeks after irradiation) (group 6, nos. 19, 21). H: day+14. Left knee intra-articularly injected with PBS and irradiated (observed 48 hours after irradiation), group 4, no. 16. I: day+19. Left knee intra-articularly injected with PBS, not irradiated (observed 7 days after date of irradiation in experimental group), group 3, no. 4.

Antigen-injected joints in immunised animals. Immunised rabbits which received antigen intra-articularly (positive control: right knee joint, without irradiation) showed in groups 1 and 3 a diffuse chronic synovitis, manifested as a proliferation of the lining cell layer, oedema, hyperaemia, and a dense subsynovial infiltration with granulocytes, plasma cells, fewer lymphocytes, and mononuclear cells. In groups 3 and 5 there were more eosinophil granulocytes, mononuclear cells, and lymphocytes (Fig. 1 A, C). In group 5 this infiltration was particularly marked (Fig. 1E).

Challenged and irradiated joints of immunised animals. In groups 2 and 4 these animals showed a significant decrease in the synovitis compared with groups 1 and 3. The lining cell layer did not show any

proliferation and almost no infiltration (Fig. 1 B, D). Early fibrosis could be recognised by the appearance of immature connective tissue cells. The numbers of cells in the synovial fluid did not differ from those observed in the corresponding immunised and nonirradiated groups. In group 6 2 animals did not show any difference in the histological pattern of the synovial membrane compared with the corresponding positive nonirradiated control group 5 (Fig. 1 G). One animal did not show any distinct signs of arthritis as in the animals in groups 2 and 4 (Fig. 1 F).

Antigen-injected and irradiated joints in nonimmunised animals. Table 2 shows the number of cells in the synovial fluid and the histological findings in the synovial membranes of groups 7 and 8. No pathological findings were observed (Fig. 1 H).

Table 2 Nonimmunised rabbits: synovial fluid cell counts and synovial histology in antigen—injected right knee and PBS-injected left knee at 48 hours and 7 days following irradiation

Group	Animal	Interval	Left knee (PBS control)			Right knee (antigen injected)		
			Irradiation	Syn. fluid cells	Histology	Irradiation	Syn. fluid cells	Histology
7	22	48h	600 r	—	No pathological findings	600 r	50 000	No pathological findings
	23		"	—		"	—	
	24		"	10 000		"	10 000	
8	25	7 days	600 r	—	"	600 r	—	"
	26		"	15 000	"	"	—	"
	27		"	—	"	"	—	"

Discussion

While several reports describe symptomatic improvement after radiation synovectomy,¹ the problem of leakage of radioactivity outside the joint still restricts the application of this treatment. Leakage of various ⁹⁰Y preparations has been reported as 4–11 % of the injected dose 25 hours after treatment and as 15 to 25 % after 5 days.^{12,13} With ¹⁹⁸Au leakage of about 60 % of injected dose after 24 hours has been observed.¹⁴ Other side effects such as cartilage and synovial necrosis have also to be taken into consideration. The effect of intra-articular injection of radiocolloids on experimental antigen-induced arthritis has been investigated. Sledge *et al.*² studied the effect of decreasing dosages of ¹⁶⁵Dy from 8 to 1 mCi on synovia of experimental ovalbumin-induced arthritis. The results were variable. Widespread destruction of inflamed synovial membranes was seen with as little as 2 mCi of ¹⁶⁵Dy, whereas in 2 rabbits the response to 6 or 7 mCi was disappointing. It was, however, considered that examination of synovial membranes 4 weeks after irradiation seemed to be too late for the investigation of acute radionecrosis effects and too early to observe a long-term effect. Meier-Ruge *et al.*³ studied antigen-induced experimental arthritis 14 days, 2 weeks, and 4, 6, and 12 months after the intra-articular injection of 0.2–0.4 mCi ⁹⁰Y. Fourteen days after the application the inflammatory oedema had disappeared, the lining cell layer of synovial membrane had decreased, and hyalin changes were present in the subsynovial connective tissue. After 3 to 4 months this evolved into fibrosis without inflammatory changes. Six to 12 months later the previously arthritic joints showed only sclerotic changes in joint capsules. Only animals with severe forms of experimental arthritis showed inflammatory areas in the synovial membranes which lasted 12 months.

Intra-articular injection of 0.2–0.4 mCi ⁹⁰Y into the knee joint of normal rabbits caused a disappearance 2 weeks later of the cell lining layer, increasing obliterations of vessels, and an increase of fibroblasts

in the synovial villi. Four weeks later there was a distinct increase of fibroblasts as well as hyaline obliteration of vessels in the synovial tissue. Pavelka *et al.*¹⁵ have described the histological effects of small doses of ⁹⁰Y injected intra-articularly into knee joints of normal rabbits. They observed fibrosis associated with small vessel endarteritis 1 to 4 months after injection. Meier-Ruge *et al.*³ conclude that less destructive effects appear in ⁹⁰Y treated arthritic joints than in untreated arthritic joints and that intra-articular treatment with ⁹⁰Y should have a favourable therapeutic effect.

While intra-articular injection of radiocolloids induced inflammation, fibrosis, and sclerosis even in normal knee joints of rabbits, local irradiation with 600 rads (200 rads/day for 3 days) reduced the severity of adjuvant arthritis.⁸ These investigations were, however, performed 100 days and 6 months after induction of arthritis. Local irradiation, as performed in this study, used one dose of 600 rads; investigation of knee joints was performed 48 hours and one and 4 weeks later (14, 19, and 40 days after challenge). In contrast to the intra-articular injection of radiocolloids, this local irradiation of normal knee joints induced neither cellular exudation into synovial fluid nor a significant histological change in the synovium. A comparison with the effect of local irradiation (3 doses of 200 rads on consecutive days) to the paws of normal rats is not possible, since in that study⁸ normal control groups were not investigated.

Irradiation of arthritic joints 12 days after challenge with a single dose of 600 rads did not seem to have any effect on the numbers of cells in synovial fluids, since 48 hours and 1–3 weeks after irradiation no difference in the cell numbers of irradiated or nonirradiated arthritic joints was observed. However, between 48 hours and 1 week after irradiation a distinct difference occurred in the synovial membrane. The irradiated arthritic joints showed an inhibition of both lining cell proliferation and infiltration with mononuclear cells. In 2 animals this inhibition had, however, disappeared, 4 weeks after irradiation. Only one animal still showed significant

inhibition of arthritis at this time. This inhibition of inflammation observed in our model is probably an anti-inflammatory effect, not influencing the cellular exudation into the synovial fluid (induced during the 12 days between the intra-articular challenge and the time of irradiation), but suppressing the synovial inflammatory process through irradiation.

X-rays can inhibit proliferation of cells involved in immune responses. However, in these experiments there could have been only a local effect, since the entire body with the exception of the irradiated area was protected by lead shielding. A local immune response may occur in antigen-induced experimental arthritis, for Jasin and Ziff have shown the synovial membrane to be an immunologically competent tissue.¹⁶ Thus the local production of antibodies, formation of immune complexes, and inflammatory consequences might have been decreased by irradiation. It may be significant that these effects seem to be time-limited and disappear, at the latest, 4 weeks after irradiation. However, only one irradiation dose was given. Repeated irradiation might alter these results. Investigations along these lines are under way.

Comparison of the effects of one dose of local irradiation with radiocolloid injections into the healthy joint shows that 600 rads applied for 8 minutes do not induce histological alterations in normal synovium, whereas intra-articularly injected 0.2–0.4 mCi ⁹⁰Y or 2 mCi ¹⁶⁵Dy led to degenerative changes of the lining cell layer, fibrosis, and obliteration of vessels.

In arthritic joints radionucleotides produce changes, varying from disappearance of oedema, reduction of lining cells, and fibrotic and hyaline changes of the subsynovial connective tissue to sclerosis and destruction of inflamed synovium. By contrast local x-ray irradiation of arthritic joints induced during the first 2 weeks purely a reduction of synovitis. Thus, while a single dose of intra-articular radionucleotide appears to induce a type of radiation synovectomy, x-rays decrease general inflammation (and possibly also local immunological reactions). This anti-inflammatory effect appears to be time-limited. Clearly no leakage of radioactivity occurs with local x-ray irradiation, and no destructive effects on normal synovium have been observed.

The absence of these side effects may tell in favour of clinical testing of x-ray treatment of inflammatory forms of arthritis, such as rheumatoid arthritis. Further studies of experimental arthritis might clarify this type of treatment. It certainly should not cause any more destructive changes or side effects than synoviorthesis with radionucleotides.

In this connection side effects like bone necrosis can be discounted, since the effect of irradiation on bone is well known¹⁷ and a surface dose of 600 rads

transmits an absorption dose of about 300 rads to bone. This amount does not induce a demonstrable bone reaction. Recent investigations of potential radiation-induced side effects in rabbits showed osteonecrosis at a dose of 1500 rads, which is 2.5 times the dose we used. Even at this higher dose regeneration of the bone was complete after 10 weeks.¹⁷ So far as side effects on the gonads are concerned, with appropriate shielding local irradiation of limb joints produces negligible irradiation effects on gonads. Irradiation of the human shoulder joint¹⁸ transmits 0.015% of the total surface dose to the ovaries and 0.003% to the testicles. A local surface dose of 10 Gy (1000 rads) would transmit to the ovaries a dose of 150 mrad and to the testicles of 30 mrad. Since a routine stomach x-ray examination exposes the gonads of males to 35 mrad and of females to 56.5 mrad,¹⁹ the irradiation of distal limb joints would be acceptable from this point of view. Therapeutic irradiation of the hip or sacroiliac joints should not, however, be undertaken. In the light of this study and others performed in a similar way x-ray irradiation of inflammatory arthritic joints should be reconsidered.

We are grateful to Professor H. L. F. Currey for his help and suggestions in the composition of this manuscript and we are indebted to Mrs E. Höfler for her skilful assistance. This study was supported by grant 4027 of the Austrian Research Council.

References

- Gumpel J M, Roles N C. A controlled trial of intra-articular radiocolloids versus synovectomy in persistent synovitis. *Lancet* 1975; **i**: 488–9.
- Sledge C B, Noble J, Hnatowich D J, Kramer R, Shortkroff S. Experimental radiation synovectomy by ¹⁶⁵Dy ferric hydroxide macroaggregate. *Arthritis Rheum* 1977; **20**: 1334–42.
- Meier-Rüge W, Müller W, Pavelka K. Tierexperimentelle Untersuchungen über die Wirkung und Nebenwirkung von Radionukleotiden auf das normale und entzündlich veränderte Kaningelenk. *Eular Monograph Reihe* 1978; **2**: 195–202.
- Kalliomäki J L, Jalava S, Möttönen M. On the development of adjuvant arthritis in the joint, intraarticularly irradiated by radioactive yttrium-90. *Scand J Rheumatol* 1974; **3**: 25–32.
- Friedmann M, Schwartz E E. Irradiation therapy of pigmented villonodular synovitis. *Bull Hosp Joint Dis* 1957; **18**: 19–32.
- Dihlmann W. Die Behandlung rheumatischer Erkrankungen mit Röntgenstrahlen. *Therapiewoche* 1977; **14**: 42–9.
- Kotzin B J, Strober S, Calin A, Hoppe R, Kaplan H S. The treatment of rheumatoid arthritis with total lymphoid irradiation. *Arthritis Rheum* 1980; **23**: 707–8.
- Schurmann D J, Hirshman H P, Strober S. Total lymphoid and local joint irradiation in the treatment of adjuvant arthritis. *Arthritis Rheum* 1981; **24**: 38–44.
- Dumonde D K, Glynn L E. The production of arthritis by an immunological reaction to fibrin. *Br J Exp Pathol* 1962; **43**: 373–80.
- Steffen C, Ludwig H, Kovac W, Menzel J. Collagen-induced acute synovitis in collagen immunized rabbits. *Z Immunitätsforsch Immunobiol* 1975; **150**: 432–46.

- ¹¹ Chlud K. Zur Wirkung von Cyclophosphamid bei der experimentellen Arthritis des Kaninchens. *Z Rheumatol* 1978; **37**: 174–99.
- ¹² Oka M, Rekonen A, Seppela O. Intraarticular injection of ⁹⁰Y resin colloid in the treatment of rheumatoid knee joint effusion. *Acta Rheumatol Scand* 1971; **17**: 148–60.
- ¹³ Gumpel J M, Beer T C, Crawley J C W, Farran H E A. Yttrium-90 in persistent synovitis of the knee: single centre comparison of the retention and extra articular spread of four ⁹⁰Y radiocolloids. *Br J Radiol* 1975; **48**: 377–81.
- ¹⁴ Topp J R, Cross E G, Fain A G. Treatment of persistent knee effusions with intraarticular radioactive gold. *Can Med Assoc J* 1975; **112**: 1085–9.
- ¹⁵ Pavelka K, Meier-Ruge W, Müller W, Friedrich R. Histological study of effects of colloidal ⁹⁰Y on knee joint tissue of rabbits. *Ann Rheum Dis* 1975; **34**: 64–9.
- ¹⁶ Jasin H E, Ziff M. Immunoglobulin and specific antibody synthesis in a chronic inflammatory focus: antigen-induced synovitis. *J Immunol* 1969; **102**: 355–69.
- ¹⁷ Albrektsson, Jakobsson, Turesson. Irradiation injury of bone tissue: a vital microscopic method. *Acta Radiol (Stockh)* 1980; **19**: 235–9.
- ¹⁸ Nüsslein F, Hassenstein E. Gonadenbelastung bei der Strahlentherapie gutartiger Erkrankungen. *Strahl—therapie* 1976; **151**: 409–14.
- ¹⁹ Ewen K, Schmitt G, Kaufmann H. Gonadenexposition bei röntgendiagnostischen Standarduntersuchungen. *ROEFO* 1972; **116**: 808–12.