

Case report

Selective C4 deficiency, systemic lupus erythematosus, and Whipple's disease

MICHAEL EHRENFELD, MURRAY B. UROWITZ, AND M. E. PLATTS

From the Rheumatic Disease Unit, the Wellesley Hospital, University of Toronto, Canada

SUMMARY A 45-year-old female with selective deficiency of C4 and systemic lupus erythematosus developed puzzling gastrointestinal and systemic symptoms in the last 6 months of her life. Extensive investigation of the gastrointestinal tract did not yield any diagnosis, and the patient died shortly afterwards. Autopsy revealed evidence of a typical Whipple's disease of the jejunum and lymph nodes. This association has not been previously described. The disease is reviewed with emphasis on its being an opportunistic infection in an immunosuppressed host with a complement deficiency and SLE.

A 45-year-old female previously described as the 4th case of SLE developing in a patient with C4 deficiency¹ is reported on now because of the development of unexplained multiple systemic and gastrointestinal symptoms in the latter part of her life. These consisted of abdominal pain, diarrhoea, fever, anaemia, and some features of malabsorption. At autopsy she was found to have Whipple's disease.

This association between Whipple's disease, a systemic infection, and SLE has not been previously described. In view of the preceding complement deficiency and SLE in this patient the Whipple's disease could be regarded as an opportunistic infection.

Case report

This 45-year-old woman first presented to the lupus clinic in 1976 with a photosensitive malar rash and dystrophic nail changes. SLE had been diagnosed in 1955 in the Netherlands. The diagnosis was based on facial rash, fatigue, photosensitivity, proteinuria, thrombocytopenia, and a positive LE test. She was initially treated with oral prednisone for 2 years. She improved somewhat but subsequently had a splenectomy and was treated with chloroquine for 15 years. Between 1970 and 1975 she received no treatment. The malar rash persisted and became much worse in 1975, while she also developed alopecia, nail changes, arthralgias, and mucous membrane ulcers.

Laboratory investigations revealed a positive LE cell test and fluorescent antinuclear antibody test (ANA). DNA binding and C3 were normal. A lupus band test was negative. In an attempt to control the rash chloroquine therapy was reinstated in 1976. CH50 was undetectable and C4 was absent by immunochemical and haemolytic assays.² Over the past 5 years she continued to have undetectable levels of C4 and positive LE and ANA tests. She has had intermittent nail lesions, nasal septal erythema, arthralgias, photosensitivity, and pleuritic chest pain.

In 1980 she suffered from polyserositis, including pleuritis and pericarditis, and was investigated for proteinuria, which was then attributed to lupus glomerulonephritis. She suffered a deep vein thrombosis complicated by pulmonary embolism. Because of the diagnosis of lupus nephritis she was treated with 40 mg of prednisone per day. During the last 6 months of her life she developed new symptoms consisting of cramping abdominal pain, diarrhoea, nausea, and vomiting, along with increasing fatigue, chills, and fever which ranged between 38 and 40°C.

Abdominal examination revealed a slightly distended abdomen with normal bowel sounds. The hypochondrium was slightly tender, and the liver was not enlarged. Laboratory investigations at this stage revealed an anaemia of 9.3 g/dl with a bone marrow showing decreased iron stores. The Coombs test was negative, and there was no occult blood in the stool. The total protein was 62 g/l with albumin 26 g/l. The cholesterol was 85 mg/dl (2.2 mmol/l) and triglycerides 100 mg/dl (1.1 mmol/l). Liver function tests and amylase were normal. Extensive investiga-

Accepted for publication 11 January 1983.

Correspondence to Dr M. B. Urowitz, Wellesley Hospital, Room 649 N, 160 Wellesley Street East, Toronto, Canada M4Y 1J3.

tion, including 3 x-ray views of the abdomen, upper gastrointestinal studies, gastroscopy and colonoscopy, barium enema, and CT scan and ultrasound of the abdomen, revealed only signs of slight gastritis. No specific cause for the continuous abdominal pains was elucidated. The prednisone dose was brought up to 80 mg/day with a gradual tapering because of a kidney biopsy which showed evidence of diffuse proliferative glomerulonephritis.

Her final admission was necessitated because of fever, chills, abdominal pains and diarrhoea, accompanied by shortness of breath. When admitted she was cachectic and in respiratory distress. Her temperature was 39.5°C and she was hypotensive. She had a very stormy and short spell in hospital. The gastrointestinal symptoms persisted. A repeat gastroscopy revealed very extensive candidiasis of the whole upper gastrointestinal tract, and high-dose nystatin (Mycostatin) was started. She developed multiple lung infiltrates with severe hypoxaemia, hypotension, and oliguria. Despite vigorous treatment which included assisted respiration, pericardiocentesis, intensive fluid, antibiotic, and steroids, the patient became more hypoxic and acidotic. She died after ventricular asystole.

At autopsy both pericardial surfaces were covered by an organising haemorrhagic and fibrinous exudate. The pericardial cavity contained 50 ml of serous fluid. Centrilobular congestion was evidence of right heart failure and heavy congested lungs of left heart failure. The lungs also showed focal bronchopneumonia bilaterally, and there was a small recent pulmonary embolus to the right lower lobe. In addition to the pericarditis further evidence of

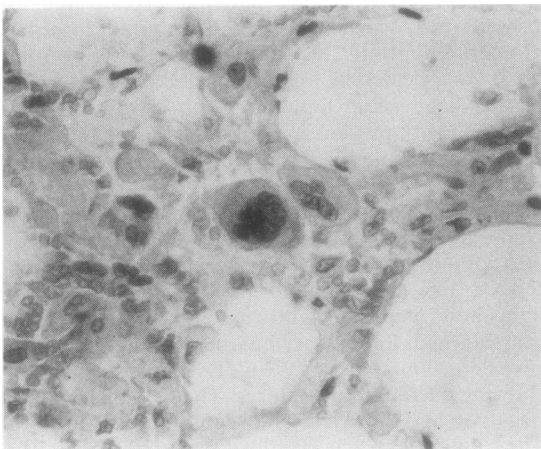


Fig. 1 Lymph node showing foamy macrophages and multinuclear giant cells separated by large fat vacuoles with little lymphoid tissue remaining. (H and E. ×203).

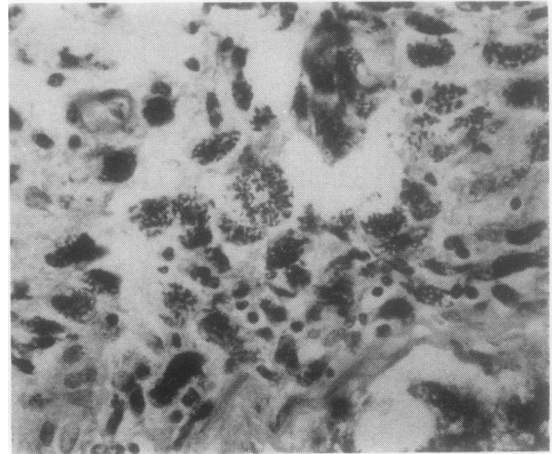


Fig. 2 Submucosa of jejunum showing PAS-positive small bodies in the cytoplasm of macrophages. (PAS, ×203).

polyserositis was noted both in the pleural cavities, which had fibrous adhesions and effusions of 200 ml, and in the peritoneal cavity with similar adhesions and ascites of 500 ml. The only evidence of lupus in the kidneys was the presence of focal basement membrane thickening of the glomeruli along with numerous proteinaceous casts in the tubules. The oesophagus was superficially ulcerated, but there was no evidence of candidiasis.

The unexpected finding was the presence of Whipple's disease. The mesenteric and para-aortic lymph nodes were enlarged, soft, and grey. Microscopically they contained large numbers of foamy macrophages and multinucleated giant cells, separated by large fat vacuoles (Fig. 1). Little lymphoid tissue remained. These macrophages were packed with small periodic acid Schiff (PAS)-positive bodies. The jejunum was erythematous grossly, and both the lamina propria and the submucosa contained large numbers of PAS-positive macrophages (Fig. 2). Electron microscopy was performed on tissue from one of the formalin-fixed nodes. It revealed that the cytoplasm of the macrophages was packed with the typical bacillary bodies of Whipple's disease (Fig. 3). None of the serous membranes contained these bacillary bodies.

Discussion

This patient, who had a hereditary C4 deficiency with SLE, developed gastrointestinal symptoms in the last few months of her life which were found to be due to Whipple's disease at autopsy. Functional studies of the patient's polymorphonuclear cells and serum done before she had developed the gastrointestinal symptoms suggested that both the chemotactic and opsonic activities in the serum were diminished²

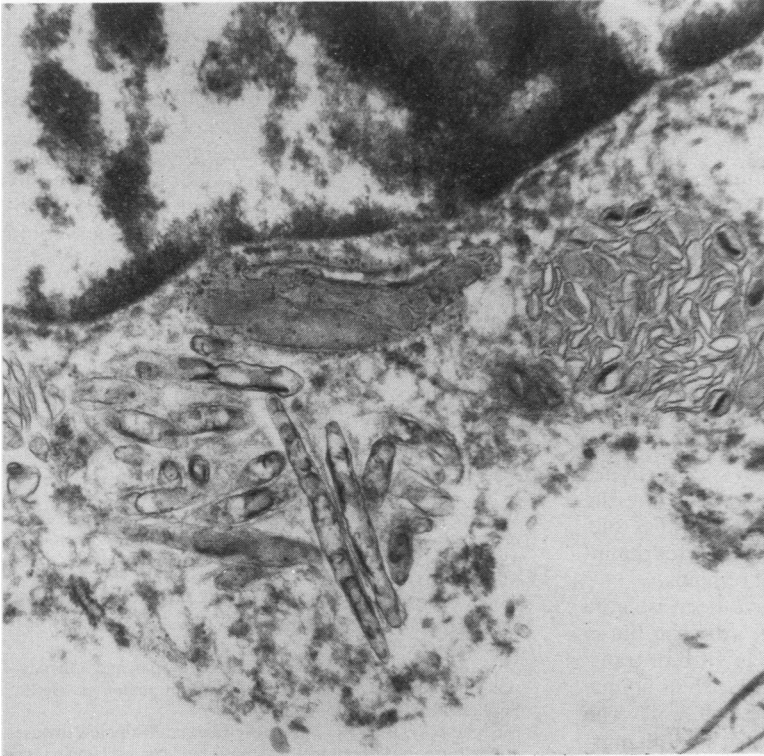


Fig. 3 *Electron microscopy of a macrophage in a mesenteric lymph node showing typical bacillary bodies of Whipple's disease. (EM, $\times 52\ 015$).*

These functions are complement mediated and could explain the abnormal host defence and increased susceptibility to opportunistic infections as expected in complement deficiency states.

Congenital complement deficiencies have been associated with a number of clinical syndromes. C3 and C3 inactivator deficiency are often found in association with severe recurrent infections. Deficiencies of the terminal complement components (from C5 to C9) may predispose to recurrent neisserial infections. Deficiencies of early complement components C1, C2, or C4, as in the case reported here, have an increased frequency of recurrent bacterial infections, vasculitis, nephritis, and SLE.³ The effects of congenital deficiencies of major complement components suggest a compromise on the host defence in patients with or without a picture of SLE. Infection is in fact a major cause of morbidity and mortality among these patients.

Whipple's disease is a systemic disease with migratory polyarthrits, polyserositis, and various CNS manifestations.^{4 5} Diarrhoea and considerable loss of weight due to malabsorption are the most frequent presenting complaints. Other presenting symptoms

are abdominal pain, lymphadenopathy, fever, hypotension, and hyperpigmentation. The symptomatology depends largely on the areas involved with the masses of foamy histiocytes. The laboratory shows all the haematological, biochemical, and stool features of malabsorption. Radiological studies of the gastrointestinal tract are usually abnormal, with thickened mucosal folds visible on small bowel barium study. Evidence of lymphadenopathy and hepatosplenomegaly can also be found. These changes are nonspecific, and the diagnosis must be established on biopsy findings.

Endoscopy shows a yellow-white granular appearance on the surface which correlates with thickened enlarged villi. Light microscopy of the small bowel shows the lamina propria to be packed with foamy macrophages, occasionally giant cells and neutrophils. These foamy macrophages contain a glycoprotein that stains strongly with PAS. This PAS positivity supports the suggestion that Whipple's disease is a systemic disease, as PAS-positive cells can be found in peripheral lymph nodes, heart, lung, spleen capsule, Kupffer cells of the liver, kidney, and interstitium of the pancreas.

The central nervous system is also involved, especially when Whipple's disease recurs after antibiotic therapy.

Electron microscopy was the one technique that demonstrated the morphology of the causative agent.⁶ Affected tissue is seen on EM to contain bacilliform bodies which have a distinct cell wall and an outer capsule. The rod-shaped bodies again confirmed the suggestion of Whipple's disease being a systemic bacterial infection, as they have been found in abundance in the lamina propria, in the central nervous system, heart, synovium, lymph node, lung, and liver. They have been found in both macrophages and polymorphonuclear leucocytes as well as lying free in the lamina propria of the bowel and they are present in smooth muscle cells, mast cells, eosinophils, and intraepithelial lymphocytes. Electron microscopy of small bowel biopsy specimens has also been shown to be important in following the response to antibiotic therapy. If treatment is successful, the bacillary bodies within phagocytes diminish until only membranous material remains.

A variety of micro-organisms have been isolated from tissues of patients with Whipple's disease, but so far no one has cultured the bacillus in vitro or transferred it into animals. This might be due to its unique outer 'membrane', external to the cell wall. The recent demonstration⁶ of the bacillus in smooth muscle, intraepithelial lymphocytes, and mast cells suggests that this bacillus is an intracellular pathogen, which unlike bacteria may survive within macrophages.

The patient described in this report developed systemic lupus erythematosus in association with a

complement deficiency state. Infection is a common and serious complication in SLE, in some series being the most frequent cause of death. Steroid therapy, as this patient had, may obviously be a contributory factor to the increased incidence of infection.

Most of the patient's puzzling gastrointestinal symptoms in the last 6 months of her life could easily be explained as being due to the complicating Whipple's disease. It is not likely that all of her illness could be explained on this basis, as she did have positive LE and ANA tests and glomerulonephritis. In addition no bacillary bodies were found in the areas of polyserositis at autopsy. This report draws attention to this previously undescribed infectious complication in a patient with a C4 complement deficiency and systemic lupus erythematosus.

References

- 1 Urowitz M B, Gladman D D, Minta J O. Systemic lupus erythematosus in a patient with C4 deficiency. *J Rheumatol* 1981; **8**: 741-6.
- 2 Minta J O, Urowitz M B, Gladman D D, *et al.* Selective deficiency of the fourth component of complement in a patient with systemic lupus erythematosus (SLE). *Clin Exp Immunol* 1981; **45**: 72-80.
- 3 Minta J O, Movat H Z. The complement system and inflammation. In: Movat H Z, ed. *Current topics in pathology*. Berlin: Springer, 1979: **68**: 136-78.
- 4 Miksche L W, Blumcke S, Fritsche D, *et al.* Whipple's disease: etiopathogenesis, treatment, diagnosis, and clinical course. *Acta Hepatogastroenterol (Stuttg)* 1974; **21**: 307-26.
- 5 Keren D F. Whipple's disease: a review emphasizing immunology and microbiology. *CRC Crit Rev Clin Lab Sci* 1981; **14**: 75-108.
- 6 Dobbins W O, Kawanishi H. Bacillary characteristics in Whipple's disease: an electron microscopic study. *Gastroenterology* 1981; **80**: 1466-75.