

Case report

Adult-onset Still's disease with an associated severe restrictive pulmonary defect: a case report

AUSTIN J. CORBETT, THOMAS M. ZIZIC, AND MARY BETTY STEVENS

From the Johns Hopkins University School of Medicine, Baltimore, Maryland, USA

SUMMARY A 21-year-old black female with an 18-month history of adult Still's disease developed symptoms and objective findings of restrictive lung disease. The pulmonary function abnormalities persisted unchanged for an additional 18 months despite moderate doses of prednisone. This complication has not been previously described in association with adult Still's disease.

In 1971 Bywaters¹ described a series of 14 adult female patients with a rash characteristic of Still's disease, high spiking quotidian fever, arthritis, and negative serological reactions for rheumatoid factor and antinuclear antibody. Subsequent reports have expanded the original description, emphasising such features as marked leucocytosis, lymphadenopathy, splenomegaly, pericarditis with effusion, and abdominal pain. Bujak *et al.*² found pulmonary involvement in 6 of their 10 patients, 2 of whom had transient pulmonary infiltrates which cleared spontaneously. There have been no reports to date of the persistent, progressive pulmonary involvement observed in the case recorded here.

Case report

The patient was a 21-year-old black female who initially presented at age 19 for evaluation of fever, pericarditis, and polyarthralgias involving the right wrist, right ankle, and both knees. Three months earlier, after a severe sore throat lasting several days which resolved spontaneously, elevated ST segments were found on the electrocardiogram and prompted admission to another hospital 'to rule out a myocardial infarction'. Lignocaine therapy was begun, and the patient developed bradycardia with seizures and had a respiratory arrest. Fever developed thereafter, which resolved on penicillin and high doses of corticosteroids, but recurred when corticosteroids were tapered, spiking as high as 106°F (41.1°C). A

pericardial friction rub was noted subsequently. The patient was transferred to the Johns Hopkins Hospital with fever unresponsive to further antibiotic therapy.

On admission she was in acute distress with blood pressure 90/50 mmHg, pulse 120/min, temperature 105.6°F (40.9°C). The skin was warm, moist, and without rashes. The right wrist was warm, swollen, and tender. Bilateral conjunctival injection and a flame-shaped haemorrhage in the left fundus were noted. The chest was dull to percussion at both bases, and bibasilar rales were heard. Cardiac examination revealed a II/VI short systolic ejection murmur. The precordium was active and no rub was detected. No lymphadenopathy or organomegaly were noted. The haematocrit was 22%, white blood cells $18 \times 10^9/l$ with a marked left shift, platelet count $400 \times 10^9/l$. The Wintrobe sedimentation rate was 48 mm per hour. The serum chemistry was normal. The anti-streptolysin O (ASO) titre was 1:240, the antinuclear antibody and latex test for rheumatoid factor were negative. The C3 level was elevated. An echocardiogram revealed a small effusion. Skin tests were negative. A muscle biopsy was normal, with no evidence of vasculitis or myositis.

On broad spectrum antibiotics the temperature remained elevated to 105°F (40.6°C) in a double quotidian pattern. Abnormal results of liver function tests developed and were thought to be secondary to aspirin in high dosage, which was discontinued. Three days after admission, the diagnosis of adult-onset Still's disease was made. Antibiotics were discontinued and high doses of methylprednisolone (Solu-Medrol) begun. The fever resolved over 36 hours on this regimen but spiked again to 102°F

Accepted for publication 16 March 1982.
Correspondence to Austin J. Corbett, MD, Office of Rheumatology, Good Samaritan Hospital, 5601 Loch Raven Boulevard, Baltimore, Maryland 21239, USA.

(38.9°C) on the sixth day in hospital, accompanied by an erythematous macular rash on the trunk and abdomen. The fever and rash resolved quickly without additional therapy. After 2½ weeks the patient was discharged on 50 mg/day of prednisone, which was rapidly tapered to 30 mg/day while she was an outpatient.

Over the subsequent 6 months the white blood cell and platelet counts, haematocrit, and sedimentation rate returned to normal. The patient complained only of intermittent swelling and pain in the right wrist and one 3-day episode of pleuritic chest pain. Twelve months after the initial illness she was taking prednisone 5 mg/day, when sore throat, pleuritic chest pain, occasional chills, and cough developed; and swelling of both wrists was detected. The haematocrit fell to 25%, white blood cell count rose to $69 \times 10^9/l$ and the platelet count, to $1400 \times 10^9/l$. The levels of C3 and C4 were normal or elevated, and the tests for antinuclear antibodies and rheumatoid factor were negative. Higher doses of prednisone were required to control these problems. Elevated liver enzymes were again noted over subsequent months, but could not always be correlated with very high levels of aspirin and appeared to accompany flares of the disease. Attempts to decrease the dose of corticosteroids repeatedly produced exacerbations characterised by polyarthritis of wrists, knees, and right ankle, pericarditis, pleuritis, and abdominal pain, with intermittent signs of peritoneal inflammation. Fever was a frequent but not invariable accompaniment. Leucocytosis and thrombocytosis recurred with activity of the disease, and the haematocrit remained between 25 and 30%. Serum complement (CH50, C3, C4) remained normal or elevated, and tests of serum chemistry remained negative. Renal function remained normal. Physical examinations showed limited flexion and extension of both wrists and frequent swelling with limited flexion of both knees. X-rays revealed early narrowing of all intercarpal joints of the right wrist.

Fourteen months after her initial illness the patient began to complain of mild dyspnoea on exertion and an intermittent cough occasionally productive of white sputum. Chest x-rays revealed hypoinflated lung fields. The echocardiogram was normal and showed an ejection fraction of 90%. Five months later the patient was admitted with fever and transient abdominal pain. Left basal rales were detected, and the chest x-ray revealed a left lower lobe infiltrate and very small pleural effusions. Pulmonary function tests disclosed a severe restrictive defect without obstruction by spirogram: FVC 0.94 l (26.5% predicted), FEV 0.92 l (30% predicted), DLco 5.9 cc/M/mmHg (30%). With exercise the PO_2 fell from 107 to 94 mmHg and the alveolar/arterial

O_2 gradients rose from 4.7 to 25.1. Lung volumes by He dilution were very low: TLC 1.91 (39%) VC 1.12 l (31.6%), FRC 1.15 l (46.7%), RV 0.8 l (58%). Phrenic nerve conduction studies were normal, and, on fluoroscopy, diaphragmatic movement was normal. Inspiratory pressure was moderately reduced. Bilateral lower extremity venograms were normal, and catheterisation revealed normal pulmonary artery pressure and normal pulmonary arteriograms. A transbronchial biopsy revealed mild, nonspecific, chronic interstitial inflammation and patchy interstitial fibrosis (Fig. 1).

Over the subsequent 5 months the patient's cough and dyspnoea diminished. Her left lower lobe infiltrate gradually cleared without specific therapy, and she was continued on prednisone 30 mg/day. Pulmonary function tests were repeated after 5 months and again revealed a severe restrictive defect with no significant improvement: FVC 1.01 (28.7% predicted), FEV 1.01 (32.9% predicted), TLC 2.19 l (44.8% predicted), VC 1.36 l (38.7% predicted), FRC 1.19 l (45.4% predicted), RV 0.83 l (60.3% predicted). The chest x-ray continued to show hypo-inflation and slight blunting of the left costophrenic angle. X-rays of the wrists obtained 26 months after onset of the disease revealed marked narrowing of the intercarpal and carpal-metacarpal joint spaces, particularly in the region of the capitate. Moderate narrowing was seen also at the radiocarpal joint space, and mild erosive changes were present (Fig. 2). At present the patient complains of moderate

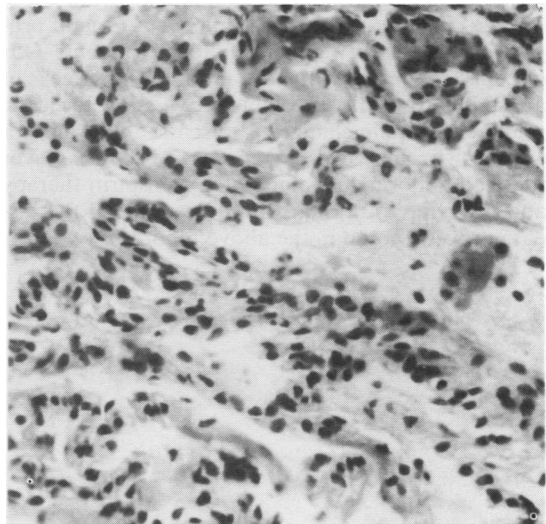


Fig. 1 Transbronchial lung biopsy showing patchy interstitial fibrosis and inflammation. (Haematoxylin and eosin, $\times 30$).

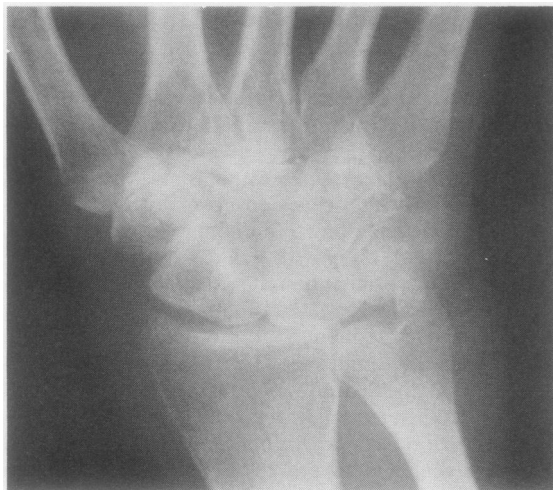

Fig. 2 Radiograph of the right wrist revealing classical changes of adult Still's disease including intercarpal and carpal-metacarpal narrowing and fusion.

dyspnoea, and pulmonary function tests revealed no significant improvement.

Discussion

This case has most of the major features of adult Still's disease. Medsger and Christy³ emphasised in addition the occurrence in their patients of a higher than expected frequency of intercarpal and carpal-metacarpal ankylosis preceded by progressive joint space narrowing over an interval ranging from 1.5 to 4 years. On the other hand Bujak *et al.*² found progressive arthritis in only one of their 10 patients. Our patient has continued to have intermittent attacks of arthritis, particularly involving the wrists, with classic roentgenographic changes as discussed by Medsger and Christy³ appearing 2 years after diagnosis. Liver function abnormalities unrelated to aspirin therapy and reverting to normal with quiescence of the disease process, noted in the above report, have occur-

red frequently enough in patients with adult Still's disease to be considered characteristic by some.²

Persistent pulmonary abnormalities represent a very unusual complication of Still's disease as well as of juvenile chronic arthritis in general. Two cases have been described of juvenile chronic arthritis in association with interstitial fibrosis and pneumo-pleuritis^{4,5} and one case in association with pulmonary hypertension without interstitial disease.⁶ No cases of persistent pulmonary abnormalities or restrictive lung disease have been reported in association with adult Still's disease. The pulmonary function abnormalities described in the above patient can be seen commonly, with or without respiratory symptoms, in adult rheumatoid arthritis, systemic lupus erythematosus, systemic sclerosis, Sjögren's syndrome, and polymyositis.⁸ The clinical course and objective data after 2 years of follow-up do not support any of these diagnoses in our patient. It therefore appears that this is the first case of adult Still's disease with a restrictive pulmonary defect.

We acknowledge the assistance of Dr Thomas W. Nygaard, former resident in medicine, the Johns Hopkins School of Medicine.

The work was supported by the Multipurpose Arthritis Centre, NIAMDD (P60-AM-20558) and the Arthritis Foundation Clinical Research Center.

References

- 1 Bywaters E G L. Still's disease in the adult. *Ann Rheum Dis* 1971; **30**: 121-33.
- 2 Bujak J S, Aptekar R G, Decker J L, Wold S M. Juvenile rheumatoid arthritis presenting in the adult as fever of unknown origin. *Medicine (Baltimore)* 1973; **52**: 431-44.
- 3 Medsger T A, Christy W C. Carpal arthritis with ankylosis in late onset Still's disease. *Arthritis Rheum* 1976; **19**: 231-42.
- 4 Martel W Abell M R, Millensen W M, Whitehouse W M. Pulmonary and pleural lesions in rheumatoid disease. *Radiology* 1968; **90**: 641-53.
- 5 Weekly Clinico-pathological Conference. *N Engl J Med* 1968; **279**: 979-83.
- 6 Jordan J D, Snyder C H. Rheumatoid disease of the lung and cor pulmonale: observations in a child. *Am J Dis Child* 1964; **108**: 174-80.
- 7 Hunninghake G W, Fauci A S. Pulmonary involvement in the collagen vascular diseases. *Am Rev Respir Dis* 1979; **119**: 471-503.