

## Case report

# Anaplastic myeloma in systemic lupus erythematosus

R. C. BUTLER, S. M. THOMAS, J. M. THOMPSON, AND A. C. S. KEAT

*From the Departments of Rheumatology and Histopathology, St Stephen's Hospital, Fulham Road, London SW10 9TH*

**SUMMARY** We describe a patient with systemic lupus erythematosus who developed an unusual form of anaplastic myeloma. Possible relationships between the two diseases, and the role played by immunosuppressive therapy, are discussed.

Patients with systemic lupus erythematosus (SLE) appear to have an increased risk of developing malignant tumours,<sup>1,2</sup> particularly lymphomas.<sup>3</sup> Despite the hyperactivity of B lymphocytes seen in SLE, multiple myeloma seems to be uncommon, there being single reports only by Canoso and Cohen<sup>1</sup> and Jordan *et al.*<sup>4</sup> Two patients with SLE who developed extramedullary plasmacytomas have been described so far.<sup>5,6</sup>

We report a third case of SLE with multiple myeloma which was unusual in that there was widespread extramedullary involvement by undifferentiated plasma cells. This is a feature of the aggressive myeloma variant recently described in five patients by Suchman *et al.*<sup>7</sup> and in two further patients by Foucar *et al.*<sup>8</sup>

### Case report

A 55-year-old Caucasian female first presented to this hospital in June 1978 with pericarditis. She had had intermittent arthralgia in the fingers and knees for several months and two years previously had been seen at another hospital for a photosensitive facial rash. Twenty years before, her sister had died of SLE. Investigation revealed anaemia (10.2 g/dl) with positive direct Coombs test, leucopenia ( $3.7 \times 10^9/l$ ), positive antinuclear factor, and raised levels of antibodies to double stranded DNA (100 U/ml: normal range <25 U/ml) (Amersham test kit). She was also hypocomplementaemic (C3 0.18

g/l; C4 0.05 g/l: normal >0.75 and >0.30 g/l respectively). Creatinine clearance was normal and 24-hour urine contained only 0.08 g protein. A diagnosis of SLE was made and she was treated with 30 mg prednisolone daily, with symptomatic improvement.

Three months later she felt generally weak, and examination revealed crepitations at both lung bases which were attributed to pulmonary involvement by her lupus. Azathioprine 150 mg daily was therefore added. She remained well on reducing doses of prednisolone until December 1979, when azathioprine was stopped, but a month later she was admitted with severe malaise, pleurisy, arthralgia, and Raynaud's phenomenon. She then had alopecia and persisting bilateral pulmonary basal crepitations, a normal chest x-ray and blood urea, but increased 24-hour urinary protein (1.1 g) and hypocomplementaemia.

The dose of prednisolone was increased to 50 mg daily and azathioprine was reintroduced at 150 mg daily. She remained well on reducing doses of prednisolone until November 1980, when she again developed leucopenia ( $3.5 \times 10^9/l$ ). At this stage the DNA-binding activity was 980 U/ml and 24-hour urinary protein 1.3 g. Azathioprine was stopped and chlorambucil 2 mg daily substituted, but two months later she was readmitted with pleurisy, chest infection, myalgia, and mouth ulcers. On this occasion there was a Coombs-positive haemolytic anaemia and hypocomplementaemia. Chlorambucil was discontinued and prednisolone increased to 40 mg daily; two months later azathioprine 150 mg daily was reintroduced. In April 1981 she became severely depressed and weak: she was found to have a

Accepted for publication 13 February 1984.  
Correspondence to Dr R. C. Butler, Department of Rheumatology, St Stephen's Hospital, Fulham Road, Chelsea, London SW10 9TH.

proximal myopathy, hypertension (200/130 mmHg), and diabetes mellitus. In addition her creatinine clearance had fallen to 27 ml/minute, blood urea was 12.7 mmol/l, and 24-hour protein excretion was 4.4 g. Levels of DNA antibodies were still elevated at 620 U/ml. The blood pressure was controlled with hydralazine, while her diabetes and myopathy responded to a reduction of the steroid dose.

In June 1982 she developed a crush fracture of one thoracic vertebra. Serum protein electrophoresis, which had been normal seven months previously, now showed an IgG kappa paraprotein (10 g/l), but a skeletal survey showed no malignant deposits. Serum calcium was 2.3 mmol/l. A coin lesion was noted in the left mid-zone on chest x-ray, but bronchoscopy was normal and the lesion decreased in size spontaneously. Lung function tests showed a restrictive defect. She continued to take prednisolone 6 mg and azathioprine 100 mg daily as well as hydralazine, but in November 1982 developed malaise and weakness and was readmitted to hospital. There was proximal muscle weakness, hypertension, and tachycardia; the liver was enlarged 4 cm below the costal margin and was tender. The serum sodium was 129 mmol/l, potassium 5.5 mmol/l, and urea 13.6 mmol/l; repeated blood cultures were negative. The paraprotein concentration was 15 g/l, with IgA 3.8 g/l and IgM 1.9 g/l; Bence Jones protein was not detected. A bone scan was normal, and sternal bone marrow examination showed only 4% plasma cells; these were of normal morphology. DNA antibodies had fallen to 60 U/ml. She responded to intravenous saline and hydrocortisone and an increase in the daily dose of prednisolone to 15 mg. Azathioprine was, however, discontinued because of leucopenia ( $2.4 \times 10^9/l$ ). She subsequently felt well and returned home but was readmitted to hospital three weeks later with pyrexia, rigors, and dyspnoea. Repeated cultures of blood, sputum, and urine were negative, and a chest x-ray showed bilaterally shrunken lungs but no inflammatory foci. The dose of prednisolone was increased but with little symptomatic improvement, and her pyrexia continued despite antibiotic therapy. She developed abdominal pain with intractable shock and died.

At post-mortem examination the right lobe of the liver contained a circumscribed, partly necrotic neoplasm, and there was considerable enlargement of all the intra-abdominal, peritracheal, and hilar lymph nodes. Microscopically the hepatic neoplasm was composed of pleomorphic, mature and immature plasma cells, including numerous binucleate and anaplastic multinucleate forms (Fig. 1). The lymph nodes and vertebral bone marrow were extensively infiltrated by similar poorly differentiated plasma cells, while both lungs showed multiple focal deposits of plasma cells. Cytoplasmic ribonucleic acid was demonstrated by the Unna Papanheim technique in most of these tumour cells. There was also extensive mucosal ulceration of the upper gastrointestinal tract due to candidiasis, bilateral pleural effusions, and a moderate pericardial effusion, with focal epicardial fibrosis, but no evidence of active serosal inflammation. The kidneys were granular and showed focal proliferative glomerulonephritis, but stains for amyloid were negative.

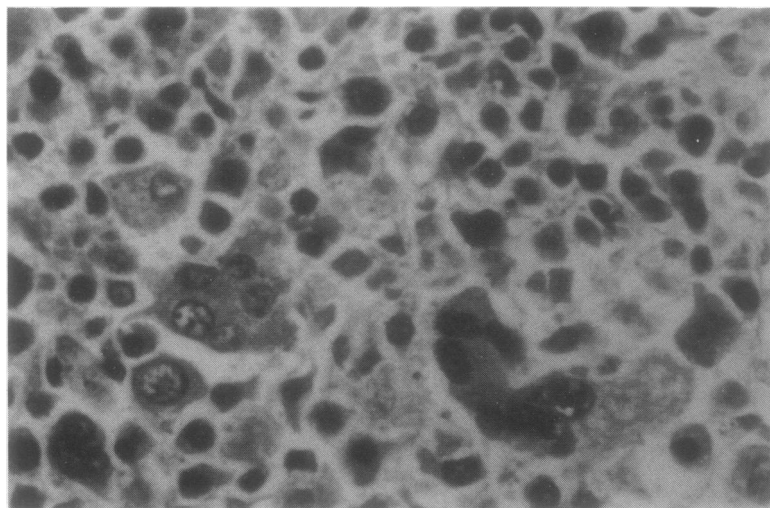


Fig. 1 *Anaplastic plasmacytoma in the liver with multinucleate giant cells.*

## Discussion

A diagnosis of multiple myeloma in this patient was based on the presence of a serum IgG kappa paraprotein and malignant proliferation of plasma cells in the liver, lymph nodes, and bone marrow as seen at necropsy. Although microscopic extramedullary deposits of myeloma may be detected at necropsy in up to 70% of cases, neoplastic deposits visible to the naked eye are detected in less than 10% of cases.<sup>9</sup> By contrast, this case resembles the recently recognised aggressive myeloma variant<sup>7,8</sup> with respect to the extent of extramedullary disease, the degree of undifferentiation of plasma cells, and the rapid clinical deterioration. Suchman *et al.*<sup>7</sup> noted that pancytopenia and unexplained fever were also features of this variant; in our case they had been attributed to active lupus.

During the four years prior to the detection of the paraprotein this patient was treated with prednisolone in doses of between 6 and 60 mg daily, and for 40 months of this period with azathioprine as well as a daily dose of 100 mg or 150 mg (1.3–2 mg/kg). In view of the increased prevalence of tumours in other groups of immunosuppressed patients<sup>10</sup> the possibility that this drug treatment and the development of multiple myeloma are related has to be considered. In this context it is of interest that Neuberger<sup>5</sup> reported a patient with an 11-year history of SLE who developed extramedullary plasmacytomas in a lymph node, the jaw, and the cervix over a four-year period during treatment with azathioprine.

Although a variety of tumours have been reported in patients with SLE,<sup>3</sup> this is only the third report of a patient with multiple myeloma. The paraprotein was first detected in this case six months before death, some six years after the onset of SLE. It is possible that both the SLE and the myeloma result from an underlying defect in immunoregulation in these patients. Alternatively, impaired cellular immune function such as decreased suppressor cell activity<sup>11</sup> and defective NK cell function,<sup>12</sup>

which are seen in SLE, or the immunosuppressive drugs used to treat the disease, may permit the emergence of a malignant clone of plasma cells.

In view of the many reports of lymphoproliferative disorders seen in SLE, the effect of immunosuppressive drugs on host defence mechanisms, such as anti-idiotypic regulation of B-cell neoplasms,<sup>13</sup> needs urgent clarification.

## References

- Canoso J J, Cohen A S. Malignancy in a series of 70 patients with systemic lupus erythematosus. *Arthritis Rheum* 1974; **17**: 383–8.
- Lewis R B, Castor C W, Kinsley R E, Bole G G. Frequency of neoplasia in systemic lupus erythematosus and rheumatoid arthritis. *Arthritis Rheum* 1976; **19**: 1256–60.
- Caldwell D S. Musculoskeletal syndromes associated with malignancy. *Semin Arthritis Rheum* 1981; **10**: 198–223.
- Jordan E, Burnstein S L, Calabro J J, Henderson E S. Multiple myeloma complicating the course of seronegative systemic lupus erythematosus. *Arthritis Rheum* 1978; **21**: 260–3.
- Neuberger R. Immunosuppression and plasmacytoma of the cervix. *J Obstet Gynaec Br Cwlth* 1974; **81**: 165–7.
- Cohen S R, Landing B H, Isaacs H, King K K, Hanson V. Solitary plasmacytoma of the larynx and upper trachea associated with systemic lupus erythematosus. *Ann Otol Rhinol Laryngol* 1978; **87** (Suppl 52): 11–4.
- Suchman A L, Coleman M, Mouradian J A, Wolf D J, Saletan S. Aggressive plasma cell myeloma. A terminal phase. *Arch Intern Med* 1981; **141**: 1315–20.
- Foucar K, Raber M, Foucar E, Barlogie B, Sandler C M, Alexanian R. Anaplastic myeloma with massive extramedullary involvement. *Cancer* 1983; **51**: 166–74.
- Hayes D W, Bennet W A, Heck F J. Extramedullary lesions in multiple myeloma. *Arch Pathol* 1952; **53**: 262–72.
- Kinlen L J, Shiell A G R, Peto J, Doll R. Collaborative United Kingdom—Australian study of cancer in patients treated with immunosuppressive drugs. *Br Med J* 1979; **ii**: 1461–6.
- Fauci A S, Steinberg A D, Haynes B F, Whalen G. Immunoregulatory aberration in systemic lupus erythematosus. *J Immunol* 1978; **121**: 1473–9.
- Kaufman D B. Natural killer augmentation in systemic lupus erythematosus via a soluble mediator derived from human lymphocytes. *Arthritis Rheum* 1982; **25**: 562–7.
- Lynch R G, Rohrer J W, Odermatt B, Gebel H M, Autry J R, Hoover R G. Immunoregulation of murine myeloma cell growth and differentiation: a monoclonal model of B cell differentiation. *Immunol Rev* 1979; **48**: 45–80.