

## Bone and joint symptoms in Paget's disease

J. WINFIELD AND T. C. B. STAMP

*From the Royal National Orthopaedic Hospital, 234 Great Portland Street, London W1*

**SUMMARY** Fifty patients with Paget's disease of bone were reviewed with regard to the basis of their symptoms and the long-term results of treatment. Twenty-four patients (48%) presented with pain localised within bone, while 17 (34%) presented with symptoms of degenerative joint disease. Three patients presented with bone pain and arthritis and the remaining six with fractures, ataxia, or painless deformity. Symptomatic osteoarthritis of the hip (OA) developed in 25 patients (50%) with approximately half developing radiological changes identical to those of idiopathic OA. Among the other patients those with coxa vara tended to show medial (rather than superior) joint space narrowing and severe Paget's disease on both sides of the joint. Arthritic pain, stiffness, and reduced mobility in other joints (knee, ankle, and wrist) were associated clinically with bone deformity adjacent to the affected joint and radiologically with distorted articular surfaces and narrowed joint spaces; sclerosis, subarticular cyst formation, and osteophytosis were usually absent. Fifteen patients were treated with calcitonin for bone pain alone; all claimed long-term 'good to complete' relief. By contrast, none of the 14 with arthritic symptoms responded to calcitonin when assessed retrospectively. Results of surgical and other medical treatment were analysed. Careful clinical evaluation is a prerequisite for optimal treatment in Paget's disease.

Paget's disease is a common bone disorder characterised by increased, disorganised bone turnover in affected areas with overgrowth of immature woven bone. It affects about 4% of the population over 40 years of age in the United Kingdom.<sup>1,2</sup> Its incidence increases with age, but only 5% of the affected patients are symptomatic.<sup>3</sup> Pain is the principal symptom<sup>4</sup> and most frequently arises from bone or associated arthritis, while fracture, nerve compression, or sarcoma are less common. When Paget's disease and arthritis are adjacent, it is easy to overlook the exact source of symptoms. Now that different therapy is available for each of these conditions, accurate evaluation is clearly important.<sup>5</sup> We therefore undertook to review the frequency, origin, and features of pain and to record the pattern of joint involvement. Since chronic, polyostotic disease may produce a variety of symptoms, we initially analysed only presenting com-

plaints. Hip arthritis was particularly common and was analysed in detail. Treatment was evaluated in circumstances which appeared to minimise placebo effects.

### **Patients and methods**

#### **PATIENTS**

Of 75 patients being followed up at medical and/or orthopaedic clinics at the Royal National Orthopaedic Hospital the first 50 who were willing and able to attend a research clinic were reviewed. All had presented with symptoms associated with radiological Paget's disease. There were 36 women and 14 men with mean ages of 67.8 years (range 46-98 years) and 66.4 (range 43-81 years) respectively. Their mean follow-up was 9.3 years (range 4 months to 18 years).

#### **METHODS OF ASSESSMENT**

Each patient and their clinical record were reviewed by one of us (J.W.) with regard to the onset and subsequent course of the disease. The patients were

Accepted for publication 16 February 1984.

Correspondence to Dr J. Winfield, Sheffield Centre for the Investigation and Treatment of Rheumatic Diseases, Nether Edge Hospital, Sheffield S11 9EL.

questioned about their bone and joint pain—its nature, severity, origin, and radiation—and about previous injury or arthritis. Conditions associated with arthritis such as psoriasis, inflammatory bowel disease, urethritis, or iritis were sought, and family histories were taken. Physical examination helped to reveal the extent of Paget's disease, and arthritis was diagnosed by pain, tenderness, and warmth or swelling of a joint, accompanied by pain and/or limitation in active or passive movement of that joint. Joint radiographs were taken, but full skeletal surveys were performed only in clinically extensive Paget's disease. Bone scans were not done routinely. Patients were finally grouped after evaluation according to the principal source of their pain.

Hips with radiological OA were further grouped into four patterns described by Roper<sup>6</sup>: *Type 1*. Degenerative hip disease and coincidental Paget's disease with narrowing of the superior joint space, bony sclerosis, subarticular cyst formation, and osteophytes. *Type 2*. Early Paget's disease of the hip joint with medial joint space narrowing rather than superior narrowing. Paget's disease was probably important in the development of these changes. *Type 3*. Type 2 with the development of protrusio acetabuli. *Type 4*. Late Paget's disease of hip joint with concentric joint space loss and protrusio acetabuli.

Response to treatment for Paget's disease and arthritis was evaluated symptomatically and biochemically.

## Results

*Referral pattern.* Of the 50 patients, general practitioners had initially referred 22 to orthopaedic surgeons (17 being later referred for consideration of medical treatment), 13 direct to a metabolic unit, 11 to physicians in other hospitals, 3 to rheumatologists, and 1 to a geriatrician. The mean duration of symptoms for the whole group before referral for specialist opinion was 4.9 years (range 2 months to 15 years). In the majority this was the time that elapsed before specific medical or surgical treatment was considered.

*Presentation.* Pain was the presenting symptom in 42 of the 50 patients (84%). Twenty-four patients presented with pain that was typically well localised to the site of clinical and radiological Paget's disease and was described as dull, nagging, or like 'toothache'. Pain was not relieved by immobilisation in any particular position. The finding of a deformed, thickened, tender long bone caused no diagnostic difficulty. The bones affected symptomatically, in order of frequency, were tibiae (7 patients), lumbar vertebrae (7 patients), pelvic bones (3 patients),

humerus (1 patient) and radius (1 patient). These patients were judged to have bone pain alone. Twelve patients (24%) presented with joint pain rather than bone pain, 11 having hip arthritis and one having knee arthritis. Five (10%) presented with difficulty in walking due to progressive hip stiffness without pain; these had marked hip OA with Paget's disease in the adjacent pelvis and/or femur. Three patients presented with girdle pain and groin and/or thigh pain. In these it was impossible to determine the exact origin of symptoms, and they were designated as symptomatic of both pelvic Paget's disease and OA of hip. In the group as a whole 19 patients (38%) had hip joint symptoms as their presenting feature and a further six developed them during follow-up.

*Hip arthritis.* Combining presentation and follow-up, we found 25 patients had symptomatic OA of hip, commonly with pain on movement, weight bearing, and walking. It was felt in the groin, buttock, outer gluteal region, or perineum and was frequently referred distally to the thigh or knee. Immobility stiffness without pain was noted by five patients. Other common symptoms were loss of mobility, leg weakness, difficulty in climbing stairs, or putting on footwear. Pain was usually relieved by rest, only two patients complaining of rest or night pain. Examination invariably revealed loss of mobility and stiffness, and the testing of hip movement, including standing and walking, usually reproduced their pain.

Twenty-four patients had Paget's disease of the pelvis, femur, or both with OA of the hip, only one having OA (bilateral) without adjacent Paget's disease. The incidence of acetabular Paget's disease alone with OA of hip (11 patients) was almost equal to that of combined acetabular and femoral disease (12 patients), and only one patient had femoral Paget's disease alone. Eight out of 12 with combined acetabular and upper femoral disease had coxa vara together with more marked medial joint space narrowing and, in four, protrusio acetabuli, a complication seen only with severe acetabular Paget's disease (Fig. 1). Fourteen of the 25 patients had bilateral radiological arthritis, giving a total of 39 radiologically arthritic hips; only four patients with OA hips were asymptomatic, an incidental finding confined to patients with Paget's disease of the whole pelvis without femoral involvement. Five patients with OA hips had other signs of primary generalised OA with Heberden's nodes and OA of the first carpometacarpal joints; two had family histories compatible with OA. By Roper's radiological classification<sup>6</sup> (see 'Methods of assessment') the present series showed the following distribution: Type 1, 19 hips; type 2, 16 hips; type 3, 3 hips; type

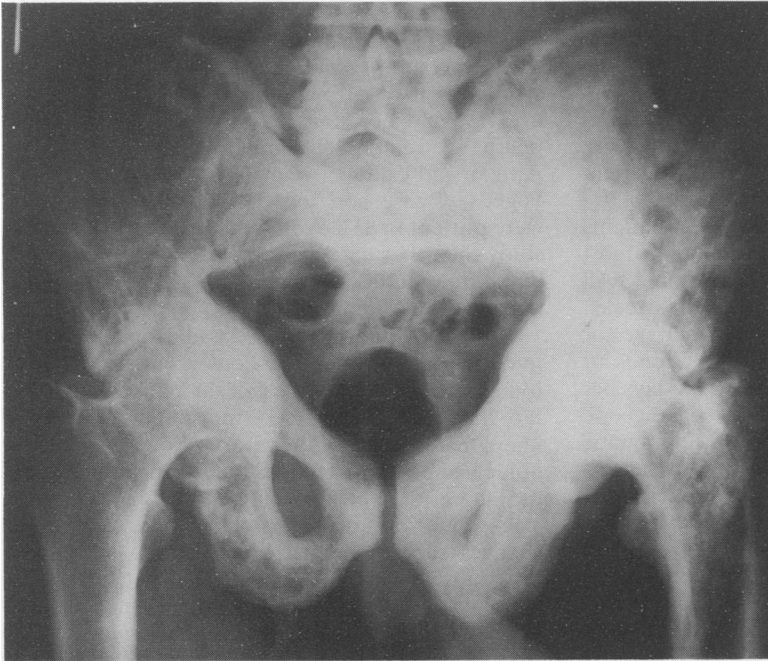


Fig. 1 Severe Paget's disease with bilateral protrusio acetabuli and concentric joint space narrowing. Signs and symptoms were of OA alone and were severe only on the right, where there was no femoral Paget's disease. As expected, the patient had had no symptomatic response to a trial of calcitonin.

4, 1 hip. Thus approximately half of the involved hips (type 1) had radiological changes indistinguishable from idiopathic OA.

*Other joint complications.* Irrespective of presenting symptoms clinical arthritis was discovered in the knee in four patients, in the ankle in five, and in the wrist in four. In each case a markedly deformed long bone had altered the alignment of articular surfaces (Fig. 2). Joints were stable, dry, and had a decreased range of movement. On *x-ray* the joint space was narrowed, but osteophytes, sclerosis and subarticular cyst formation were characteristically absent. It was difficult, however, to assess how much true cartilage loss had occurred because of frequent obliteration of normal joint outline by the distorted articular surface. Shoulder pain and stiffness (four patients) was due to supraspinatus tendinitis without adjacent Paget's disease. Two patients developed pseudogout of the knee and showed chondrocalcinosis on *x-ray*. Six patients had borderline or raised serum urate levels (0.40–0.54 mmol/l), but none developed gouty arthritis. Calcitonin appeared not to affect serum urate.

*Back pain and Paget's disease.* Eighteen patients complained of back pain and stiffness, particularly after immobility, and on *x-ray* all had degenerative disc disease characterised by disc space narrowing, sclerosis of vertebral bodies, and osteophyte formation. However, only seven had spinal Paget's

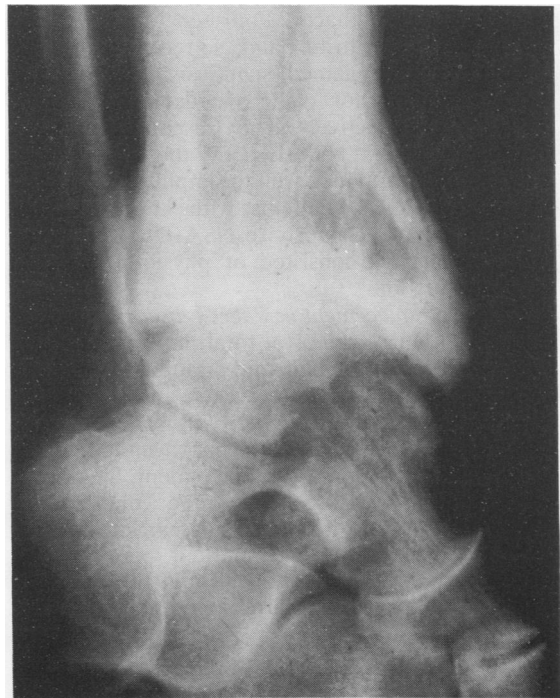

Fig. 2 Paget's disease in a tibia with arthritis of ankle.

disease. Sacral Paget's disease was frequent in this group and was associated with blurring or obliteration of the sacroiliac joints.

*Miscellaneous presentation.* Three patients presented with pain due to fracture of Pagetic bone, two with giddiness and ataxia secondary to severe skull involvement and platybasia, and one patient with painless deformity of the tibia.

*Response to medical treatment.* Of the 24 patients adjudged to have bone pain alone the 15 most severely affected were treated with calcitonin. All had a good response within three to six weeks. Normal dosage schedules for either porcine or salmon calcitonin were used (40–80 MRC units or 50–100 MRC units respectively three to six days per week). Patients with disease in a single bone responded particularly well, often with dramatic reduction in bone pain. At review nine were still receiving regular calcitonin. Six had discontinued therapy with little or no recurrence of bone pain, three on account of side effects of porcine or salmon calcitonin, of whom one was later maintained on human calcitonin (kindly donated by Ciba Laboratories). The other nine patients had milder bone pain and responded to simple analgesics, soluble aspirin, paracetamol, Distalgesic (dextropropoxyline and paracetamol), or non-steroidal anti-inflammatory drugs (NSAIDs)—ibuprofen, naproxen, or indomethacin. Fourteen of 17 patients presenting with arthritic pain also received a trial of calcitonin. None gained significant improvement with calcitonin, nor could we detect a placebo response retrospectively. They responded partially to analgesics and NSAIDs. Of the 25 with hip arthritis four responded well to simple analgesia and eight to NSAIDs. Patients with knee or ankle arthritis responded poorly to NSAIDs. Other supportive measures consisted of physiotherapy and weight reduction.

*Total hip replacement in Paget's disease.* Seven of the 50 patients came to total hip replacement because of increasing pain and disability. The mean age at operation was 68 years and the mean follow-up postoperatively 4.7 years. There was an excellent result in three, and improvement of hip mobility and pain by 70% in one patient. Significant complications were seen in three: one patient developed a loose prosthesis one year after operation; the other two had marked para-articular ectopic new bone formation around the operated hips one to three years after operation.

## Discussion

The present review, conducted exclusively among the symptomatic 5% of patients with Paget's

disease,<sup>1-3</sup> has assessed the probable origin of these symptoms, their pattern of presentation, and response to therapy. Pain was the principal presenting symptom, arising from bone in 48%, from arthritis in 24%, and occasionally from both (6%). These figures are remarkably similar to those reported by Altman and Collins,<sup>7</sup> who studied 290 patients with Paget's disease and found 'rheumatic syndromes' were present in 83%, with bone pain in 47%. In our study the other patients presented with progressive hip stiffness (10%), fracture (6%), painless deformity (2%) and ataxia (4%).

Using Roper's<sup>6</sup> suggested classification of OA hip into four patterns (see 'Methods of assessment'), we found that approximately half the patients with OA hip had changes (type 1) indistinguishable from idiopathic disease with superior joint space loss. Some had primary generalised OA, including OA of the side of the pelvis unaffected by Paget's disease. The other half of the patients had radiological changes such as medial or concentric joint space loss, more strongly suggestive that Paget's disease was contributing to its development. Indeed many of these had varus deformities of the Pagetic femoral neck, suggesting a more medially directed stress within the hip joint. Concentric joint space loss is usually associated with inflammatory disease of synovium and cartilage—for example in rheumatoid arthritis—but the possibility of such changes within arthritic joints associated with Paget's disease has not been investigated. The possible role of altered mechanics within the hip joint on the basis of bone disease also requires further study. Protrusio acetabuli was associated with the most severe changes in trabecular pattern, remodelling, and in some cases marked deformity of the femoral neck and head. This study has also shown the rarity of femoral Paget's disease alone with OA of the hip.

Total hip replacement has been carried out in patients with Paget's disease with considerable success.<sup>8,9</sup> The present small, unselected group with longer follow-up than other studies shows a less favourable outcome, with loosening of the prosthesis and/or para-articular ossification in three of seven patients. Taylor *et al.*<sup>10</sup> found significant ossification after total hip replacement in 8.5% of patients with ankylosing spondylitis, 4% in idiopathic OA, and none with rheumatoid arthritis. The frequency of para-articular ossification after total hip replacement in Paget's disease has not been previously reported, but the present incidence may be significant. None of these patients received preoperative treatment for Paget's disease to reduce bone vascularity, and excessive bleeding was not a complication. At present there does not appear to be any specific contraindication to hip replacement

in this group of patients. Marked protrusio acetabuli, however, may make adequate fixation of the acetabular component difficult when the Pagetic bone is soft or the medial pelvic wall very thin.

Pain and stiffness in other joints (knee, wrist, ankle) were associated with distorted articular surfaces on x-ray due to the adjacent bone deformity. Other signs of joint inflammation were lacking. The frequency of lumbar pain and stiffness in the present series (36%) is consistent with that found in the two American studies,<sup>7 11</sup> comparing closely with the 37% reported by Altman and Collins.<sup>7</sup> However, symptomatic lumbar spondylosis was very common in patients without vertebral Paget's disease, while spinal Paget's disease alone may be asymptomatic. The similarity of back symptoms among those with and without spinal Paget's disease therefore made it difficult to determine the cause of back pain, a problem encountered by others.<sup>7</sup> No patients had past or family histories compatible with ankylosing spondylitis, nor were syndesmophytes or bone fusions found in their lumbosacral spines. Obliteration of the sacroiliac joints in Paget's disease may be more due to bony distortion than to true inflammatory sacroiliitis, in keeping with other joint changes. The finding of Franck *et al.*<sup>11</sup> studying 55 patients with Paget's disease that hyperuricaemia, gouty arthritis, and calcific peri-arthritis were all common was not confirmed.

Multiple symptoms may plainly result from chronic polyostotic disease, and up to 60% of patients with symptomatic Paget's disease develop articular

symptoms in its course. Effective therapy may depend on accurate localisation of all symptoms, and many patients have an overlap between articular and bone symptoms. Analgesics and non-steroidal anti-inflammatory drugs remain the basis of treatment for arthritis, and there is no evidence yet that calcitonin will inhibit its development. In selected cases orthopaedic procedures may be indicated, including osteotomy for bone deformity and joint replacement for severe degenerative disease.

We are grateful to the many physicians and surgeons who referred their patients.

#### References

- 1 Collins D H. Paget's disease of bone—incidence and subclinical forms. *Lancet* 1956; **ii**: 51–7.
- 2 Pygott F. Paget's disease of bone, the radiological incidence. *Lancet* 1957; **i**: 1170–1.
- 3 Smith R. Paget's disease of bone. *Biochemical disorders of the skeleton*. 1979; London: Butterworth, 1979: 136.
- 4 Smith R. Paget's disease of bone, osteogenesis imperfecta and fibrous dysplasia. *Br Med J* 1977; **i**: 365–7.
- 5 Hosking D J. Paget's disease of bone. *Br Med J* 1981; **ii**: 685–8.
- 6 Roper B. Paget's disease involving the hip joint—a classification. *Clin Orthop* 1971; **80**: 33–8.
- 7 Altman R D, Collins B. Musculoskeletal manifestations of Paget's disease of bone. *Arthritis Rheum* 1980; **10**: 1121–7.
- 8 Milgram J W. Orthopaedic management of Paget's disease of bone. *Clin Orthop* 1977; **127**: 63–9.
- 9 Stauffer R N, Sim F H. Total hip arthroplasty in Paget's disease of the hip. *J Bone Joint Surg* 1976; **58A**: 476–8.
- 10 Taylor A R, Kamdar B A, Arden G P. Ectopic calcification following total hip replacement. *J Bone Joint Surg* 1976; **58B**: 134.
- 11 Franck W, Bress N, Singer F, Krane S. Rheumatic manifestations of Paget's disease of bone. *Am J Med* 1974; **56**: 592–603.