

Studies on the interaction of rheumatoid factor with monosodium urate crystals and case report of coexistent tophaceous gout and rheumatoid arthritis

T P GORDON, M J AHERN, C REID, AND P J ROBERTS-THOMSON

From the Department of Clinical Immunology, Flinders Medical Centre, Bedford Park, South Australia 5042

SUMMARY Gout and classical rheumatoid arthritis rarely coexist. We report a patient with strong evidence for both these diseases. Possible reasons for the negative correlation between these diseases are summarised. One hypothesis suggests inhibition of surface activity of monosodium urate crystals (MSU) by binding of rheumatoid factor (RF). This was studied with a purified monoclonal rheumatoid factor (mRF) with specificity for IgG. The mRF bound preferentially to MSU coated with IgG in contrast with the IgM control. Inhibition of the neutrophil chemiluminescence (CL) response to IgG-coated MSU was observed at concentrations of mRF that had no effect on the CL response to uncoated crystals. Neutrophil activation was not altered by coating crystals with an IgM control at the same concentration. These data suggest that RF may bind to antigenic determinants on exposed Fc of adsorbed IgG and block the interaction of crystal-bound IgG with Fc receptors. Although crystal coating by RF may modify the expression of gouty arthritis, it is unlikely to be the sole explanation for the dissociation between gout and RA.

The negative correlation between gout and rheumatoid arthritis (RA) is widely accepted, but the reason(s) are unclear.¹ Since synovial thickening,² symmetrical joint involvement,³ a low titre rheumatoid factor⁴ (RF), joint erosions,⁵ and similar histopathological changes in the synovial membrane⁶ can occur in both conditions, proof of the coexistence of gout and RA requires the demonstration of monosodium urate crystals (MSU), a high titre RF, and histological evidence of a rheumatoid nodule in an alcohol-fixed specimen.⁷⁻⁹

Possible reasons for the mutual exclusion between these diseases have been reviewed elsewhere.^{1 10} and include an anti-inflammatory or immunosuppressive effect of hyperuricaemia,¹¹⁻¹⁴ inhibition of crystal deposition by possible connective tissue alterations in RA,¹⁵ diagnostic difficulty, synovial hypocomplementaemia,¹⁶ and impaired phagocytic function of neutrophils in rheumatoid joint fluid.^{16 17} It has also been proposed that coating of MSU by RF may inhibit the activation of cellular or fluid-phase mediators of inflammation by the crystal surface.^{1 3 18}

We report the fourth recorded case of coexistent gout with MSU and RA with high-titre RF and a biopsy-proved rheumatoid nodule. With in-vitro techniques and a purified monoclonal rheumatoid factor (mRF) with specificity for IgG we have tested the hypothesis that binding of RF to adsorbed IgG on the MSU surface might modify gouty inflammation in patients with RA.

Case report

A 60-year-old man had a history from 1958 of episodic acute attacks involving the feet, ankles, and wrists, which responded to treatment with colchicine or indomethacin. In 1960 he developed persistent pain and stiffness of multiple joints and synovitis of the proximal interphalangeal (PIP), metacarpophalangeal (MCP), wrist, and elbow joints bilaterally and symmetrically and a positive RF titre of 1/2048 (Rose-Waaler). In 1968 needle aspiration of nodules over the pinnae of the ears, olecranon bursa, and right tibia showed MSU by compensated polarised light microscopy (CPLM). The serum uric acid level was 0.5 mmol/l (range 0.15-0.42 mmol/l). Allopurinol 300 mg daily was started but ceased in 1979

Accepted for publication 7 December 1984.
Correspondence to Dr T P Gordon.

because of a rash. Over this period he experienced no further 'gout-like' episodes, but the symmetrical polyarthritis persisted.

In 1981 bilateral synovial thickening of the PIP, MCP, wrist, and elbow joints, large knee effusions, and flexor tenosynovitis of the fingers were all noted. Tophi from which MSU crystals were recovered were present over the olecranon and dorsum of the right wrist. Investigations showed a haemoglobin of 11.7 g/dl, ESR 60 mm/h, serum uric acid 0.74 mmol/l, RF titre 1/2048. Joint fluid of low viscosity was aspirated from the right knee and showed a white blood cell count of $12 \times 10^9/l$ with 89% neutrophils and 11% mononuclear leucocytes, and a RF titre of 1/16 384. No urate crystals were detected in knee joint fluid on this or subsequent aspirations. Radiographs of the hand showed erosive changes in the radiocarpal, intercarpal, and MCP joints. Erosions were present in the first metatarsophalangeal joints, right interphalangeal joint of the big toe, and the heads of the metatarsal bones. During admission both intra- and extracellular urate crystals were recovered from an acutely inflamed ankle joint. After resolution of the attack allopurinol 300 mg/day was reinstated.

The patient was readmitted for bilateral knee joint replacement in June 1984. Tophi in the pinnae of the ears and over the olecranon and right wrist had disappeared. Serum uric acid was 0.37 mmol/l and RF titre 1/256. Excisional biopsy of a nodule over the extensor aspect of the left forearm, fixed in absolute alcohol, showed several rheumatoid nodules each consisting of a central area of necrosis surrounded by palisading mononuclear cells (Fig. 1). Examination of the unstained, alcohol-fixed specimens by CPLM was negative for MSU. Syno-

vial membrane from the knee joint showed synovial lining cell hyperplasia and infiltration with mononuclear and polymorphonuclear leucocytes, changes compatible with but not pathognomonic of RA.⁶ No urate crystals were detected in the synovial specimens. Treatment was continued with indomethacin and allopurinol and he was started on D-penicillamine.

Materials and methods

NEUTROPHILS

Human peripheral neutrophils were obtained from heparinised blood by Hypaque-Ficoll separation followed by dextran sedimentation as described previously.¹⁹ Contaminating red cells were lysed by a five minute incubation in Gey's solution and the preparation adjusted to 5×10^9 neutrophils/l in Eagle's minimal essential medium (MEM, Flow Laboratories) containing 1% fetal calf serum.

CRYSTALS

MSU crystals were prepared under sterile conditions by the method of Denko and Whitehouse²⁰ and the supersaturated solution autoclaved before crystallisation. Crystals were washed twice in distilled water, dried under UV light for 72 hours, and resuspended in urate-saturated Dulbecco's phosphate-buffered saline (PBS) at a concentration of 10 g/l. After sonication at 1500 cycles per second for one minute a stock suspension with crystals ranging from 1 to 20 μm in length was stored at 4°C.

Crystals were coated with IgG by incubation with Cohn fraction 11 (CSL) in a ratio of 10 mg crystals per 1 ml of protein solution (5 g/l) for 30 minutes at room temperature, then washed three times in urate-saturated PBS, and resuspended at a concentration of 10 g/l. When comparisons were made between IgG-coated and uncoated crystals, both preparations were washed equally.²¹

PURIFICATION AND RADIOLABELLING OF mRF AND IgM

The mRF was purified from the serum cryoglobulin of a patient with a lymphoproliferative disorder as described previously (mRF(A)).²²

The IgM control was prepared from the serum of a patient with Waldenström's macroglobulinaemia whose IgM level was 55 g/l, IgG 0.35 g/l, and IgA <0.07 g/l. The serum was fractionated on a Sepharose 6B column, and the fractions containing IgM were pooled and concentrated in an Amicon concentration unit. The final concentrations of the mRF and IgM were determined spectrophotometrically; both were adjusted to 0.5 g/l in PBS and stored at -80°C before use. Aliquots of mRF and

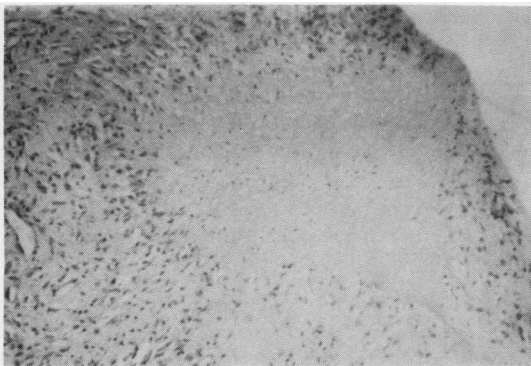


Fig. 1 Haematoxylin and eosin stain of a rheumatoid nodule from the extensor aspect of the forearm showing central area of necrosis surrounded by palisading mononuclear cells. No urate crystals were seen in the unstained alcohol-fixed specimen. ($\times 100$).

IgM were radiolabelled with ^{125}I by a modification of the lactoperoxidase method with $500\ \mu\text{g}$ protein and $200\ \text{mCi } ^{125}\text{I}$.²³ Non-protein iodine was removed by passing through a Sephadex G25 column. The percentage precipitations of ^{125}I -mRF and ^{125}I -IgM in 10% trichloroacetic acid were greater than 95%.

BINDING OF ^{125}I -mRF AND ^{125}I -IgM TO MSU
 100 μl of tracer amounts of ^{125}I -labelled protein were incubated with MSU for 60 minutes at room temperature with frequent vortexing. Unbound protein was removed by a modification of the method of Terkeltaub *et al.*²⁴ Crystals were washed through 1.0 ml of 40% sucrose in urate-saturated PBS and then washed once in urate-saturated PBS. The washed crystal pellet was resuspended in 0.5 ml PBS and counted separately from the supernatant and tube. The percentage binding of ^{125}I -mRF and ^{125}I -IgM to MSU was calculated from the formula $\text{cpm pellet}/(\text{cpm pellet} + \text{cpm supernatant} + \text{cpm tube}) \times 100\%$.

LUMINOL

A stock solution of 0.056 M 3-aminophthal-

hydrazide (Koch Light Laboratories) in dimethyl sulphoxide was diluted 1:40 in MEM before use.

CHEMILUMINESCENCE (CL) ASSAY

In order to measure the interaction between MSU and neutrophils a CL assay was used. CL is an integral part of the respiratory burst of stimulated neutrophils and an indirect measure of oxygen free radical generation. Thus CL reflects early membrane activation of the neutrophil.²⁵ The CL response of human neutrophils was measured as described earlier.¹⁹ All reagents were prewarmed to 37°C before use. 400 μl of neutrophil suspension was mixed with 600 μl luminol solution and 200 μl crystal suspension and immediately placed in an LKB luminometer (model 1250). Light output in millivolts was recorded on a chart recorder and digital printout set to 10-second recording integrals. Temperature was kept at 37°C by a water jacketed sample holder.

PREINCUBATION WITH mRF

IgG-coated and uncoated MSU (10 g/l) were preincubated with a 1% v/v solution of purified

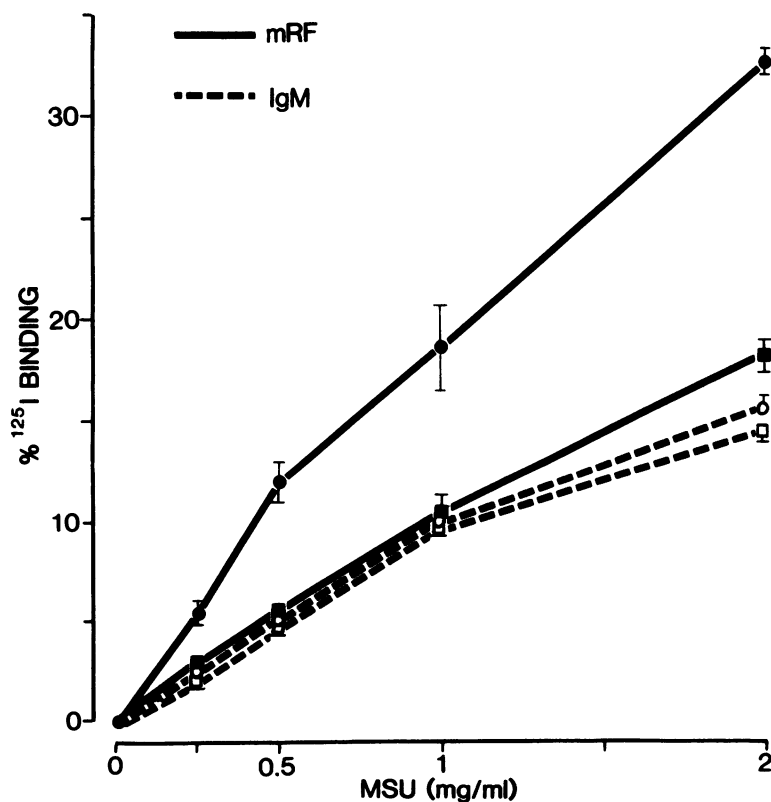


Fig. 2 Binding of trace amounts of ^{125}I -labelled mRF and IgM to uncoated MSU (squares) and IgG-coated MSU (circles). Mean \pm SD; $n=3$.

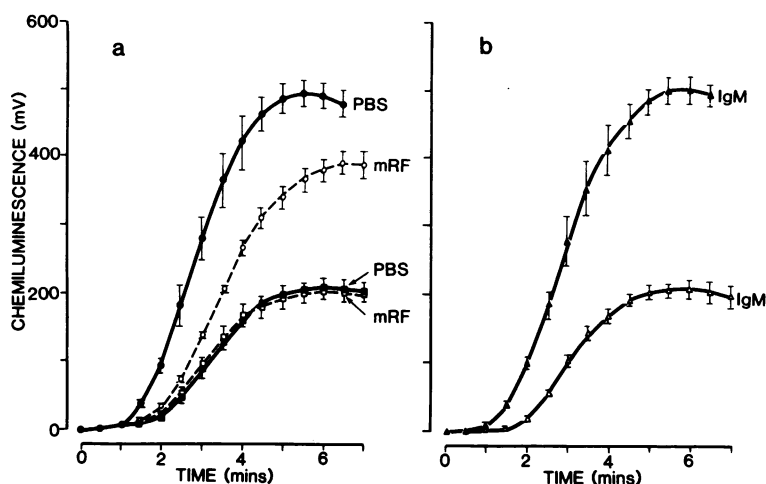


Fig. 3 The initial CL responses of 2×10^6 neutrophils on addition of $600 \mu\text{l}$ luminol and $200 \mu\text{l}$ MSU suspension. (a) The solid lines indicate the CL response to uncoated MSU (\blacksquare) and IgG-coated MSU (\bullet) both preincubated with PBS. The dashed lines indicate the CL responses after incubation of uncoated MSU (\square) and IgG-coated MSU (\circ) with mRF. (b) Activation of neutrophils by uncoated MSU (\triangle) and IgG-coated MSU (\blacktriangle) both preincubated with an IgM control. Mean \pm SD; $n=4$.

mRF (0.5 g/l) and IgM control (0.5 g/l) for 60 minutes at room temperature and washed before testing for neutrophil activation by CL. Control crystals were preincubated with PBS alone.

Results

BINDING OF mRF AND IgM TO MSU

Precoating of MSU with human IgG enhanced the binding of mRF by approximately twofold over a range of crystal concentrations, whereas IgM bound with similar affinity to both crystal preparations (Fig. 2). This suggests that the mRF can bind to the crystal surface via previously adsorbed IgG.

EFFECT OF BINDING OF mRF AND IgM TO MSU ON CL

The possible functional consequences of mRF and IgM binding on crystal-neutrophil interactions were studied by a CL assay. The CL response was enhanced two- to threefold by coating the crystal with IgG (Fig. 3a), confirming the observation of Platt *et al.*²⁶ Preincubation with mRF (1% v/v of a 0.5 g/l solution) significantly reduced the maximum CL response with IgG-coated MSU ($p < 0.01$; two-tailed Student's *t* test) without inhibiting the response with uncoated crystals (Fig. 3a). The same concentration of the IgM control had no effect on uncoated or IgG-coated MSU (Fig. 3b).

Discussion

Our patient is an example of one of the few convincing cases of coexistent gout and RA and only the fourth case of gout with documented MSU and RA with a rheumatoid nodule. Some reports of

supposed coexistence can be viewed critically, since the diagnosis of RA was based on the presence of morning stiffness, symmetrical synovitis, and a positive RF titre, features that can be mimicked by polyarticular gout.²⁷⁻²⁹ We cannot explain the association between the two diseases in our patient. In particular there appeared to be no correlation between the degree of hyperuricaemia, the RF titre, and the clinical expression of his gout and RA.

The pathogenesis of gouty inflammation is complex and not fully understood, but the interaction between MSU and neutrophils appears central.³⁰ Binding isotherms of IgG to urate crystals have suggested monomolecular adsorption at concentrations of IgG found in joint fluid, and studies with molecular probes have shown that the Fc fragments of the IgG molecules are fully exposed.^{31, 32} Bardin *et al.*³³ have confirmed the functional availability of the Fc fragment by immunoelectron microscopy. Crystals coated with IgG have been shown to enhance non-cytolytic secretion of lysosomal enzymes and superoxide anion, presumably due to interaction of crystal-bound IgG with Fc receptors on the neutrophil membrane.^{21, 34} Thus IgG crystal coating may have an important role in triggering acute gouty arthritis. RF binds to epitopes on the Fc portion of IgG.³⁵ We propose that adsorption of IgG to the crystal surface increases the density of Fc antigenic determinants, favouring multivalent binding of RF. This is supported by the enhanced binding of mRF to IgG-coated MSU (Fig. 2). Similarly the preferential reactivity of RF with aggregated or complexed IgG is possibly due to the increased number of exposed IgG Fc antigenic determinants in the complexed state.²² We postulate a masking of the specific IgG Fc/Fc receptor

interaction by mRF. This is suggested by our findings that mRF inhibited neutrophil activation by IgG-coated MSU in a dose that had no effect on uncoated crystals (Fig. 3a). In contrast, coating with the IgM control did not alter the response to either crystal preparation (Fig. 3b). We have shown a similar inhibition by mRF of neutrophil activation by large immune complexes (IC), which raises the speculation that IgG-coated urate crystals in vivo may have some properties similar to IC.¹⁹

The present in-vitro studies suggest a role for RF in modulation of crystal-neutrophil interactions mediated by adsorbed IgG. The effect of RF on MSU activation of other cellular and humoral mediators of inflammation requires further study. Whether RF plays a significant role in modifying gouty arthritis in vivo is not clear. With a neutrophil monolayer system to study neutrophil responses to urate crystals Turner *et al.*¹⁸ reported no effect of RF on adherence, phagocytosis, or enzyme release, but the RF used was polyclonal and unpurified. Doherty *et al.*³⁶ showed that patients with seropositive RA mount normal inflammatory responses to intradermal injection of MSU, but this model of crystal-induced inflammation may not allow participation of RF during induction of the inflammatory response. It seems unlikely that crystal coating by RF alone can explain the mutual exclusion of gout and RA. For example, RF would not be expected to prevent the development of tophaceous deposits. A combination of genetic, biochemical, and immunological factors may account for the apparent dissociation between these two diseases.

We gratefully thank Dr S Neoh and Mr T Nikoloutsopoulos for technical assistance and Ms L Koh for purifying the proteins. T P Gordon was supported by an NH and MRC postgraduate scholarship.

References

- Wallace D J, Klinenberg J R, Morhaim D, Berlanstein B, Biren P C, Callis G. Coexistent gout and rheumatoid arthritis. Case report and literature review. *Arthritis Rheum* 1979; **22**: 81-6.
- Trentham D E, Masi A T. Chronic synovitis in gout simulating rheumatoid arthritis. Demonstration of bilateral popliteal cysts and wrist synovial corrugation. *JAMA* 1976; **235**: 1358-60.
- Talbot J H, Altman R D, Yu T F. Gouty arthritis masquerading as rheumatoid arthritis or vice versa. *Semin Arthritis Rheum* 1978; **8**: 77-114.
- Kozin F, McCarty D J. Rheumatoid factors in the serum of gouty patients. *Arthritis Rheum* 1977; **20**: 1559-60.
- Rappoport A S, Susman J L, Weissman B N. Lesions resembling gout in patients with rheumatoid arthritis. *Am J Roentgenol* 1976; **126**: 41-5.
- Goldenberg D L, Cohen A S. Synovial membrane histopathology in the differential diagnosis of rheumatoid arthritis, gout, pseudogout, systemic lupus erythematosus, infectious arthritis and degenerative joint disease. *Medicine (Baltimore)* 1978; **57**: 239-52.
- McCarty D J. The pendulum of progress in gout with crystals to hyperuricaemia and back. *Arthritis Rheum* 1964; **7**: 534-41.
- Owen D S, Toone E, Irby R. Coexistent rheumatoid arthritis and chronic tophaceous gout. *JAMA* 1966; **197**: 123-6.
- Jesee E F, Toone E, Owen D S, Irby R. Coexistent rheumatoid arthritis and chronic tophaceous gout. *Arthritis Rheum* 1980; **23**: 244-7.
- Agudelo C A, Turner R A, Panetti M, Pisko E. Does hyperuricaemia protect from rheumatoid inflammation? *Arthritis Rheum* 1984; **27**: 443-8.
- Lussier A, DeMedicis R. Inhibition of adjuvant-induced arthritis in the hyperuricaemic rat. *Agents Actions* 1978; **8**: 536-42.
- Schwartz M L, Malawista S E. Dosage-dependent inhibition of phagocytosis by human leukocytes exposed to urate in solution (abstract) *Arthritis Rheum* 1975; **18**: 424.
- Turner R A, Pisko E J, Agudelo C A, Counts G B, Foster S L. Uric acid effects on in vitro models of rheumatoid inflammatory and autoimmune processes. *Ann Rheum Dis* 1983; **42**: 338-42.
- Ames B N, Cathcart R, Schwiers E, Hochstein P. Uric acid provides an antioxidant defense in humans against oxidant- and radical-caused aging and cancer: a hypothesis. *Proc Natl Acad Sci USA* 1981; **78**: 6858-62.
- Schumacher H R. Pathogenesis of crystal-induced synovitis. *Clin Rheum Dis* 1977; **3**: 105-31.
- Scott J T. Gout. *Ann Rheum Dis* 1983; **42** (suppl): 16-8.
- Turner R A, Schumacher H R, Myers A R. Phagocytic function of polymorphonuclear leukocytes in rheumatic diseases. *J Clin Invest* 1973; **52**: 1632-5.
- Turner R A, Counts G B, Treadway W J, Holt D A, Agudelo C A. Rheumatoid factor and monosodium urate crystal-neutrophil interactions in gouty inflammation. *Inflammation* 1981; **5**: 353-61.
- Gale R, Bertouch J V, Gordon T P, Bradley J, Roberts-Thomson P J. Neutrophil activation by immune complexes and the role of rheumatoid factor. *Ann Rheum Dis* 1984; **43**: 34-9.
- Denko C W, Whitehouse M W. Experimental inflammation induced by naturally occurring microcrystalline calcium salts. *J Rheumatol* 1976; **3**: 54-62.
- Abramson S, Hoffstein S T, Weissman G. Superoxide anion generation by human neutrophils exposed to monosodium urate. Effect of protein adsorption and complement activation. *Arthritis Rheum* 1982; **25**: 174-80.
- Roberts-Thomson P J. A reappraisal of the monoclonal rheumatoid factor test for circulating immune complexes: a comparison of two monoclonal rheumatoid factor reagents. *Clin Exp Immunol* 1982; **48**: 52-62.
- Hesser C, Boesman M, Nordin J H, Isliker H. Effect of chemical and enzymatic radioiodination on in vitro human C1q activities. *J Immunol* 1973; **110**: 820-8.
- Terkeltaub R, Curtiss L K, Tenner A J, Ginsberg M H. Lipoproteins containing apoprotein B are a major regulator of neutrophil responses to monosodium urate crystals. *J Clin Invest* 1984; **73**: 1719-30.
- Allen R C, Stjernholm R L, Steele R H. Evidence for the generation of an electronic excitation state(s) in human polymorphonuclear leukocytes and its participation in bactericidal activity. *Biochem Biophys Res Commun* 1972; **47**: 679-84.
- Platt P N, Jeffery S, Wilson I D, Griffith I D. The interactions of crystals and polymorphonuclear leukocytes monitored by luminol dependent chemiluminescence. *Ann Rheum Dis* 1981; **40**: 615.
- Schwartzberg M, Lieberman D H, Gupta V P, Ehrlich G E. Rheumatoid arthritis and chronic gouty arthropathy. *JAMA* 1978; **240**: 2658-9.
- Rizzoli A J, Trujeque L, Bankhurst A D. The coexistence of gout and rheumatoid arthritis: case report and a review of the literature. *J Rheumatol* 1980; **7**: 316-24.
- Pistiner M, Pitlik S, Rosenfeld J B. Gout, pseudogout and

- rheumatoid arthritis in an elderly patient. *Med Interne* 1982; **20**: 55-8.
- 30 Phelps P, McCarty D J. Crystal-induced inflammation in canine joints. II. Importance of polymorphonuclear leucocytes. *J Exp Med* 1966; **124**: 115-25.
- 31 Kozin F, McCarty D J. Protein binding to monosodium urate monohydrate, calcium pyrophosphate dihydrate and silicon dioxide crystals. I. Physical characteristics. *J Lab Clin Med* 1977; **89**: 1314-25.
- 32 Kozin F, McCarty D J. Molecular orientation of immunoglobulin G adsorbed to microcrystalline monosodium urate monohydrate. *J Lab Clin Med* 1980; **95**: 49-58.
- 33 Bardin T, Cherian P V, Schumacher H R. Immunoglobulins on the surface of monosodium urate crystals: an immunoelectron microscopic study. *J Rheumatol* 1984; **11**: 339-41.
- 34 Kozin F, Ginsberg M, Skosey J. Polymorphonuclear leukocyte responses to monosodium urate crystals: modification by adsorbed serum proteins. *J Rheumatol* 1979; **6**: 519-26.
- 35 Johnson P M. Molecular nature and cross-reactions of rheumatoid factor. In: Holborow E J, ed. *Clinics in immunology and allergy*. London: Saunders, 1981: 103-15.
- 36 Doherty M, Hornby J, Dieppe P A. Normal response to monosodium urate crystals by patients with rheumatoid arthritis. *Ann Rheum Dis* 1983; **42** (suppl): 95-6.