

HLA-DR expression by labial minor salivary gland tissues in Sjögren's syndrome

H M MOUTSOPOULOS,¹ J J HOOKS,² C C CHAN,² Y A DALAVANGA,¹
F N SKOPOULI,¹ AND B DETRICK²

From the ¹Department of Medicine, Medical School, University of Ioannina, 453 32 Ioannina, Greece; and the ²Immunology and Virology Section, National Eye Institute, NIH, Bethesda, Maryland, USA

SUMMARY Minor salivary gland biopsy specimens from patients with Sjögren's syndrome (primary and secondary) and from normal controls were examined with the four step biotin-avidin-immunoperoxidase assay. The composition of the infiltrating cells was similar in patients with both primary and secondary Sjögren's syndrome, consisting primarily of T lymphocytes with predominance of T helper/inducer cells. B lymphocytes (Leu-14) were approximately 20-35% of the infiltrating lymphocytes, while only a few OKM₁ (monocytes/macrophages) cells and Leu-7⁺ (natural killer; NK) cells were observed. The majority of infiltrating lymphocytes expressed HLA-DR antigens. In the biopsy specimens of the controls there were no infiltrates; the scattered lymphocytes, however, were also predominantly T lymphocytes. Finally, the glandular epithelial cells (ducts and acini) were inappropriately expressing HLA-DR antigens, in contrast with controls where minimal HLA-DR expression was found.

Key words: T lymphocytes, epithelial cells.

Sjögren's syndrome (SS) is the result of a chronic, persistent, lymphocytic infiltrate of exocrine glands, which leads to diminished glandular secretions and mucosal dryness.

Two major phenomena characterise this disease as autoimmune: the chronic focal or diffuse lymphocytic infiltrate and B lymphocyte hyper-reactivity expressed as hypergammaglobulinaemia, autoantibodies, and immune complexes.¹ Initial studies have shown that this infiltrate consists of T and B lymphocytes. Using monoclonal antibodies, however, it was shown that the cell which predominates in the infiltrate of the exocrine glands is the T helper/inducer cell.² The triggering factor of this infiltrate remains obscure.

Class II major histocompatibility antigens have a key role in antigen presentation and regulation of the immune response. Sjögren's syndrome is one of the autoimmune diseases which is highly associated with class II HLA antigens.³ These antigens are normally expressed on macrophages, B lympho-

cytes, activated T lymphocytes, and capillary endothelium.⁴⁻⁸ Recently, inappropriate HLA-DR expression was noticed in thyrocytes and epithelial or endothelial cells of affected tissues in inflammatory and autoimmune states.⁹⁻¹⁶

In the present report we show that minor salivary gland tissues from patients with Sjögren's syndrome inappropriately express HLA-DR antigens; a finding which suggests that the altered glandular tissue in Sjögren's syndrome may have a role in the pathogenesis of the disease.

Patients and methods

PATIENTS

Sixteen minor labial salivary gland biopsy specimens were obtained from seven patients with primary Sjögren's syndrome (pSS),¹ three patients with rheumatoid arthritis (RA) and clinical and histological evidence of SS,¹⁷ two patients with RA without clinical or histological manifestations of SS, one patient with systemic lupus erythematosus (SLE) and SS, and three normal volunteers. The specimens were immediately embedded in OCT (Miles Lab., Naperville, Ill), snap frozen in a

Accepted for publication 24 January 1986.

Correspondence to Dr H M Moutsopoulos, Department of Medicine, Medical School, University of Ioannina, 453 32 Ioannina, Greece.

mixture of dry ice/2-methylbutane (-75°C), and stored at -70°C until processed. The biopsy specimens from patients with SS had different degrees of histopathological lesion according to Tarpley's classification¹⁷ (Table 1). Three biopsy specimens from the normal volunteers and the two specimens from the RA patients did not have the classical histopathological lesion of SS but only scattered

Table 1 *Tarpley's classification of the labial minor salivary gland histopathological lesion*


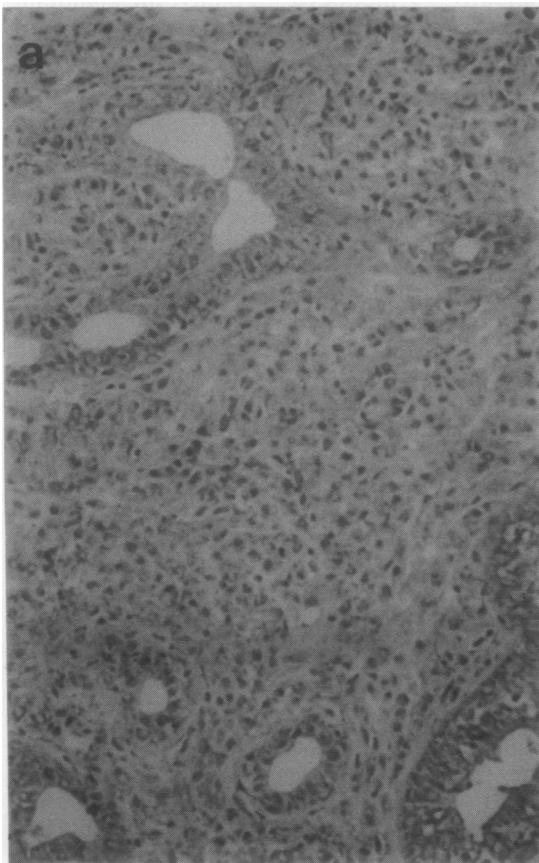
Class	Histopathological lesion
0	Normal salivary tissue
I (1+)	Round cell aggregates* (one or two) of lymphocytes, plasma cells, and histiocytes per lobule
II (2+)	More than three aggregates of round cells per lobule
III (3+)	Diffuse lobular round cell infiltrates with partial destruction of acinar tissue, with or without fibrosis
IV (4+)	Diffuse round cell infiltrate with fibrosis destroying completely the lobular architecture

*Aggregate=approximately 50 round cells.

Table 2 *Clinical profile of individuals participating in the study*

No	Diagnosis	Age (years)	Sex	Disease duration (years)	Minor labial salivary gland histopathology (Tarpley's classification)
1	Normal	50	F	NA*	0
2	Normal	58	F	NA	0
3	Normal	42	F	NA	0
4	RA	48	F	3	0
5	RA	33	F	5	0
6	SS	53	F	4	4+
7	SS	48	F	7	2+ (fibrosis)
8	SS	57	F	12	2+ (fibrosis)
9	SS	49	F	2	4+ (severe fibrosis)
10	SS	38	F	5	4+
11	SS	70	F	10	1+
12	SS	50	F	12	2+
13	RA+SS	52	M	7	3+ (fibrosis)
14	RA+SS	59	F	1	3+
15	RA+SS	56	F	8	1+
16	SLE+SS	48	F	6	2+

*NA=not applicable.



lymphocytes throughout the gland. Table 2 summarises the clinical data of these patients and the histological findings in the minor salivary gland biopsy specimens.

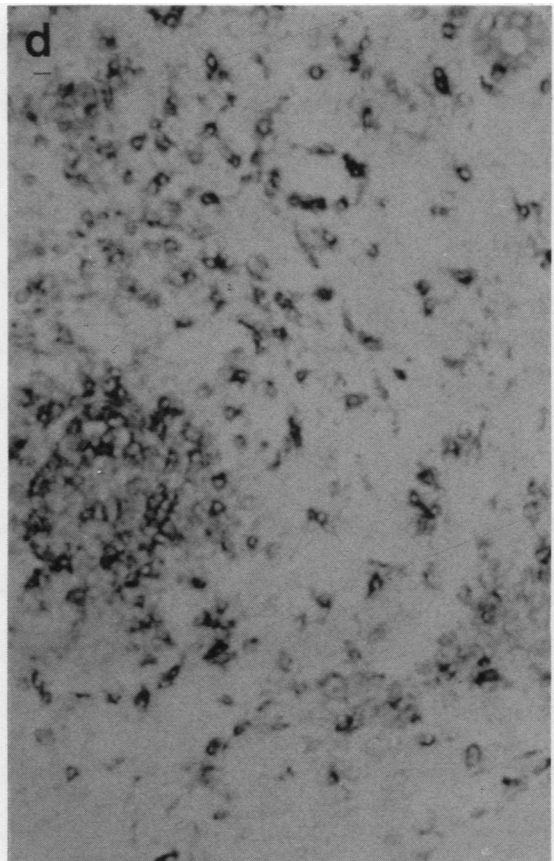
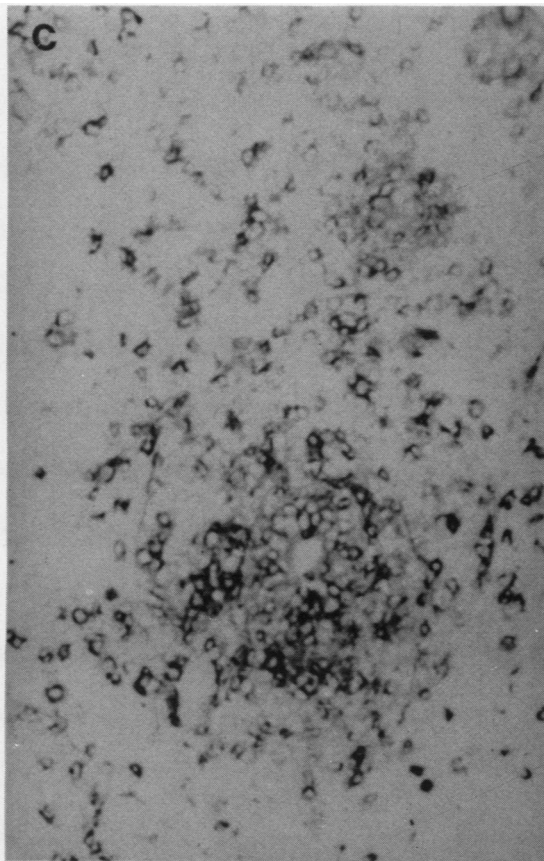
STAINING PROCEDURE

Serial frozen sections (4 µm) were cut and placed on gelatinised slides, which were stored at -70°C. Before staining, the slides were air dried for 20 min at room temperature and fixed in acetone. Mouse hybridoma derived monoclonal antibodies against human T lymphocytes (Leu-4), T helper cells (Leu-3a), T helper/inducer cells (Leu-8), T suppressor/cytotoxic cells (Leu-2a), B lymphocytes (Leu-14), NK cells (Leu-7) (Becton-Dickinson Monoclonal Center, Inc., Mountain View, California), macrophages/monocytes (OKM₁), and HLA-DR antigen (OKIa), (Ortho Diagnostic Systems Inc., Raritan, New Jersey) were used as primary antibody at a dilution of 1:40. Mouse ascites protein was also used

as a control protein. After incubation in a moist chamber at room temperature for one hour the slides were washed in TRIS (trometamol) buffered saline, and the secondary antibody, biotin labelled horse antimouse IgG (ABC kit, Vectastain, Vector Lab., Burlingame, Ca) 1:200 was added. The slides were incubated in the moist chamber at room temperature for another hour. After washing in TRIS buffered saline avidin-biotin-peroxidase complex (Vector Lab.) 1:100 was applied for 45 min. The slides were then washed in TRIS buffered saline, allowed to react with the substrate of diaminobenzidine 8%, Ni₂SO₄ 3%, H₂O₂ solution, counterstained with methyl green, dehydrated, cleared, mounted, and a coverslip added as in routine processing.

DATA COLLECTION

The minor salivary gland frozen sections were read in a blind fashion and scored independently by two



observers, using 40× magnification. The number of cells labelled with each monoclonal antibody was counted for at least 10 different fields and averaged. Special attention was paid to the staining by the different antibodies of the glandular tissue (acini and ducts). Cells were considered positive if they showed a dense, dark black-bluish ring on the cellular membrane. After the cells were counted the results from the two observers were averaged. The variability between the two observers was less than 5%. The mean ratios of T cells to B cells, T cell subsets (Leu-3a to Leu-2a, Leu-3a to Leu-8), T cells to NK cells, T cells to macrophages, and HLA-DR positive to HLA-DR negative acini and ducts were calculated and recorded.

Results

Eleven out of the 16 biopsy specimens showed lymphocytic infiltration ranging from 1+ to 4+ according to Tarpley's classification.¹⁷ Four of these

biopsy specimens showed moderate to severe fibrosis (Table 2). The other five biopsy specimens showed normal salivary tissues with scattered lymphocytes.

In the biopsy specimens from SS patients with and without RA and SLE the predominant cells (55–75%) among either the focal or diffuse infiltrates were cells bearing the pan T lymphocyte marker (Leu-4⁺). Approximately 20–35% of the infiltrating lymphocytes displayed the B cell marker (Leu-14⁺). The majority of T lymphocytes expressed the T helper/inducer phenotype (Leu-3a⁺/Leu-8⁺). The ratio of Leu-3a⁺/Leu-2a⁺ varied from case to case, ranging from 5/1 to 10/1. Among T helper/inducer cells 30–60% also expressed a T inducer phenotype (Leu-8a⁺). Only a few OKM₁⁺ cells were observed and NK cells (Leu-7⁺) were rarely detected (Table 3).

Specimens from normal individuals or patients with RA without SS contained scattered lymphocytes which expressed the pan T marker, with a ratio

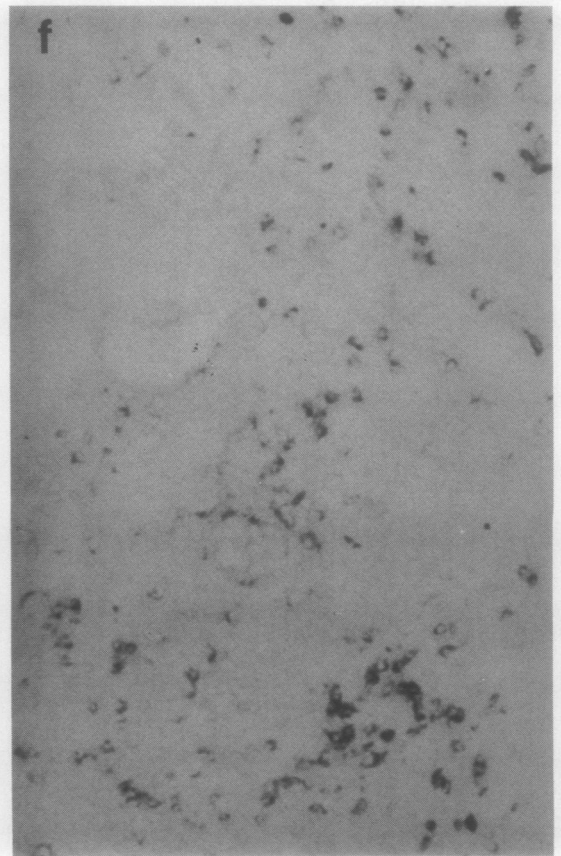
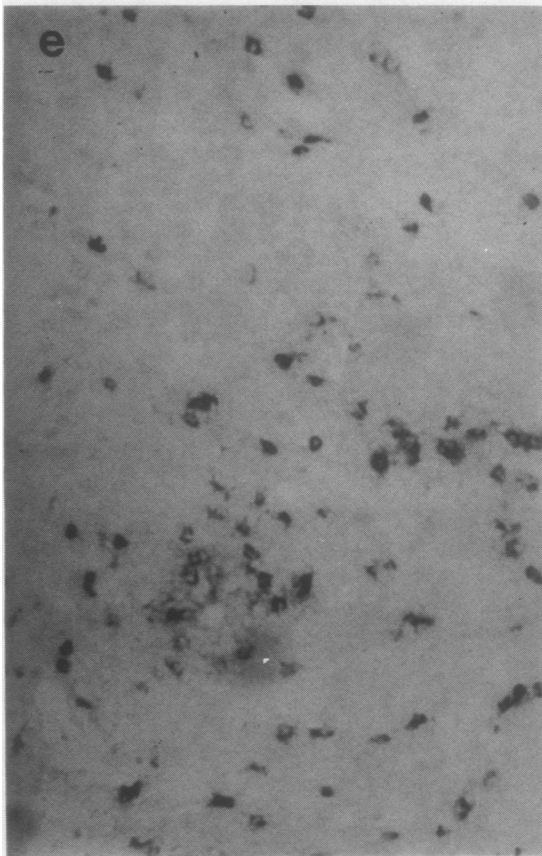


Table 3 Reactivity of the lymphocytes in the infiltrates of the labial minor salivary glands with monoclonal antibodies

Monoclonal antibodies		Stained cells (%)
Leu-4	pan T lymphocytes	55-75
Leu-3a	T helper cells	45-55
Leu-2a	T suppressor/cytotoxic cells	10-20
Leu-14	pan B lymphocytes	20-35
Leu-7	NK cells	<5
OKM ₁	macrophages/monocytes	<5
OKIa	HLA-DR	70-100

of T to B cells of 5/1. In all of the specimens from SS patients more than 70% of the total infiltrating cells expressed HLA-DR antigen (70-100%) (Table 4). In eight specimens 70-90% of the glandular cells expressed HLA-DR antigen. In the remaining three specimens 30-45% of glandular cells expressed HLA-DR antigens. The staining intensity and the incidence of the staining were similar in both ducts and acini. Minimal HLA-DR antigen expression was noted in the glandular ductal and acinar cells of normal individuals of RA patients without SS. The composition of the lymphocytic infiltrate and the epithelial HLA-DR expression in a patient with SS are shown in Figs 1a-1h.

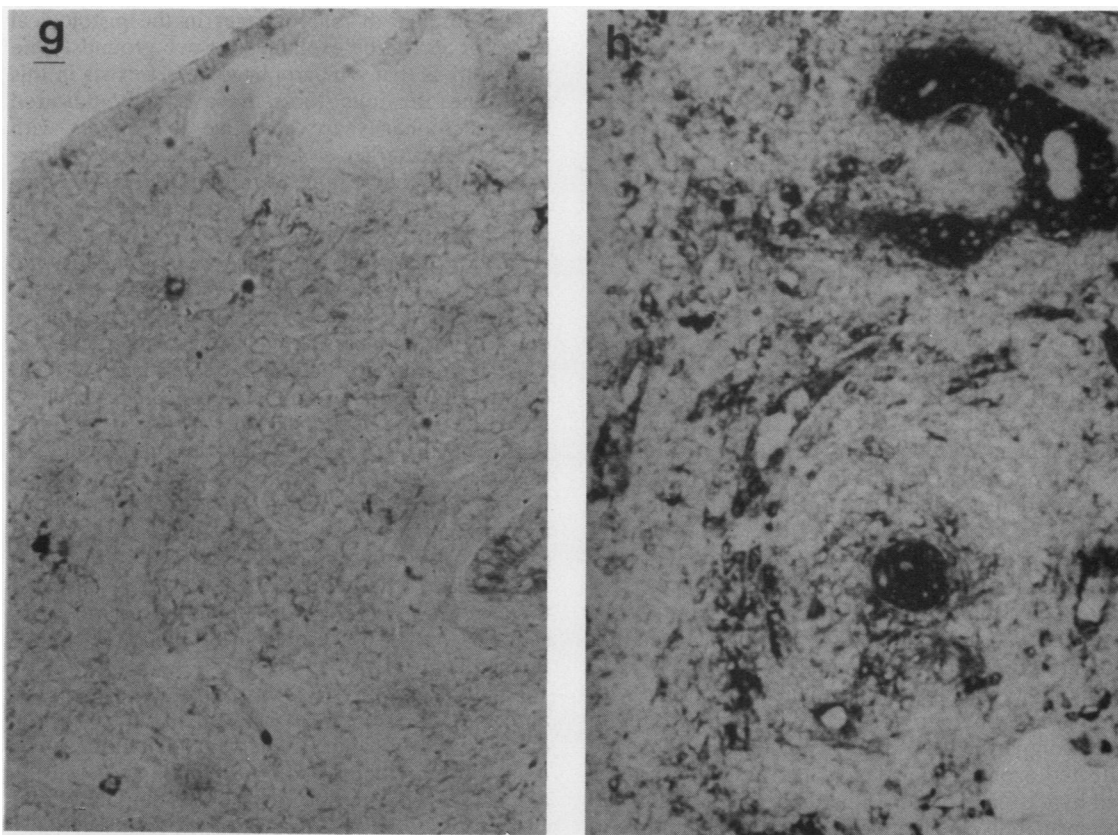


Fig. 1 Minor salivary gland biopsy specimen from SS patient (No 6). (a) Heavy periductal lymphocytic infiltrate destroying the acini (haematoxylin and eosin stain, $\times 10$). Cryostat section of the above biopsy stained with: (b) Mouse ascites protein as a negative control. No staining is observed ($\times 10$). (c) Anti-T lymphocyte antibody (Leu-4); 70% of the infiltrating cells are stained ($\times 10$). (d) Anti-T helper lymphocyte antibody (Leu-3a); 50% of the infiltrating cells are stained ($\times 10$). (e) Anti-T suppressor lymphocyte antibody (Leu-2a); 20% of infiltrating cells are stained ($\times 10$). (f) Anti-B lymphocyte antibody (Leu-14); 25% of the infiltrating cells are stained ($\times 10$). (g) Antimonocyte/macrophage antibody (OKM₁). A few scattered cells are stained ($\times 10$). (h) Anti-HLA-DR antibody (OKIa). Intensive staining of the epithelial (ducts and acini) and infiltrating cells is shown ($\times 10$).

Table 4 DR expression in lymphocytic infiltrates and glandular tissues (ducts and acini)

Subjects	Stained cells with OKIa (%)	
	Lymphocytic infiltrates	Glandular cells
Normal controls		
1	—	<5
2	—	<5
3	—	<5
RA patients		
4	—	<5
5	—	<20
SS patients		
6	100	90
7	80	90
8	40	40
9	90	45
10	90	90
11	90	30
12	95	95
RA+SS patients		
13	90	90
14	95	90
15	50	70
SLE+SS patients		
16	60	75

Discussion

Several investigators have studied the circulating lymphocytes and their immunoregulatory subsets in patients with SS in an attempt to determine the aetiology of the B lymphocyte hyper-reactivity in this syndrome. None of these studies, however, could adequately explain this aberration. Moutsopoulos and Fauci described a reversible T suppressor cell defect which did not interfere with the suppressive function of these cells.¹⁸ Fox *et al* using monoclonal antibodies showed a decreased T suppressor cell population and normal T helper cells.² Fauci and Moutsopoulos studying the spontaneous B cell activation in SS and SLE patients showed that activated B cells do not circulate and are not found in the bone marrow of SS patients, in contrast with SLE where the activated B cells were present in both compartments.¹⁹ Lane *et al* suggested that the affected exocrine glands are one site of localised B cell hyper-reactivity in SS patients.²⁰ This study and the availability of monoclonal immunoglobulins to lymphocyte surface markers stimulated investigators in this field to study the cell composition in the minor salivary glands of SS patients.

As has been previously shown,² and confirmed in our study, the majority of the infiltrating cells in the minor salivary glands were T lymphocytes of the helper/inducer subset and approximately 25% were B lymphocytes. Almost all infiltrating cells dis-

played the HLA-DR antigen. HLA-DR antigens are expressed mainly by B lymphocytes, monocytes/macrophages, and in vitro by activated T lymphocytes.^{5-7 21} Most of the infiltrating cells in the minor salivary gland lesion of SS express HLA-DR antigen. Since the majority of these cells are T lymphocytes we suggest that they are activated T lymphocytes. This finding could explain the previously described localised B lymphocyte hyper-reactivity in SS patients.²⁰

With the monoclonal antibodies OKM₁ and Leu-7 less than 5% of the infiltrating cells were stained. In the haematoxylin and eosin stained slides from SS patients polymorphonuclear leucocytes were not observed. Thus the small numbers of cells stained with OKM₁ most probably represent monocytes/macrophages.

The absence of macrophages in the histological lesion of SS can be explained on two grounds. One possibility is that a macrophage defect exists in this syndrome. Previous studies have actually indicated that macrophages are defective in patients with SS.²²⁻²⁴ Hamburger *et al* showed a defective clearance of immune complexes through the Fc receptor of the cells of the reticuloendothelial system in patients with extraglandular SS.²² Miyasaka *et al* reported a deficient response in autologous and allogeneic mixed lymphocyte reactions in some patients with SS.^{23 24} This finding suggested a defective T lymphocyte/macrophage interaction in these patients. Alternatively, it could be that the B cells or the glandular epithelial cells of SS patients have the role of macrophages in SS. Thus macrophages are not needed for this immunological response.

No definite differences in the cell composition of the inflammatory lesion were observed between patients with primary SS and SS in association with RA or SLE. Whether this points towards a common tissue reaction with a different clinical or serologic sequelae¹ in the two groups of SS patients deserves further study.

Finally, in our study inappropriate HLA-DR antigen expression was observed in the acini and ducts of minor labial salivary gland biopsy specimens from patients with SS. This finding is in agreement with the recent study of Lindhal *et al*.²⁵ Inappropriate HLA-DR antigen expression has also been noted in epithelial cells of the gut, skin, liver, kidney, thyroid, eye, and bronchi in a variety of immunologically mediated conditions such as graft versus host disease and autoimmune states.⁹⁻¹⁶ Whether this is the result or the triggering factor of the inflammatory process is not clear at present. Activated T lymphocytes are present in abundance in the salivary gland lesion of SS. These cells are

probably able to produce γ -interferon, which has been shown to augment HLA-DR antigen expression.⁶ Therefore, one might conclude that this HLA-DR expression is the result of the T mediated inflammatory process in SS patients. Alternatively, one can speculate that the absence of macrophages observed in these patients converts epithelial cells into antigen presenting cells, thus inappropriately expressing class II molecules on their surface. This inappropriate HLA-DR expression attracts immunocytes, which in turn, through γ -interferon, augment the HLA-DR expression and thus a vicious circle operates leading to autoimmunity.

We wish to thank Ms E E Papanikolaou for excellent secretarial assistance.

References

- Moutsopoulos H M, Chused T M, Mann D L, *et al.* Sjögren's syndrome: current issues. *Ann Intern Med* 1980; **92**: 212-6.
- Fox R, Carstens S, Fong S, Robinson CA, Howell F, Vaughan J H. Use of monoclonal antibodies to analyze peripheral blood and salivary gland lymphocyte subsets in Sjögren's syndrome. *Arthritis Rheum* 1982; **25**: 419-22.
- Moutsopoulos H M, Mann D L, Johnson A, Chused T M. Genetic differences between primary and secondary sicca syndrome. *N Engl J Med* 1975; **301**: 761-3.
- Winchester R J, Kunkel H G. The human Ia system. *Adv Immunol* 1979; **28**: 222-92.
- Yu D, McCune S M, Fu R J, Winchester R J, Kunkel H G. Two types of Ia-positive T-cells. Synthesis and exchange of Ia antigens. *J Exp Med* 1980; **152**: 895-903.
- Collins T, Karman A J, Wake C T, *et al.* Immune interferon activates multiple class II MHC genes and the associated invariant chain gene in human endothelial cells and dermal fibroblasts. *Proc Natl Acad Sci USA* 1984; **81**: 4917-21.
- Natali P G, de Martino G, Quaranta V, *et al.* Expression of Ia-like antigens in normal non-lymphoid tissues. *Transplantation* 1981; **31**: 75-8.
- Rowden G, Lewis M C, Sullivan A L. Ia antigen expression on human epidermal Langerhans' cells. *Nature* 1977; **268**: 247-8.
- Aichinger G, Fill H, Wick G. In situ immune complexes, lymphocyte subpopulations and HLA-DR positive epithelial cells in Hashimoto thyroiditis. *Lab Invest* 1985; **52**: 132-40.
- Barclay A N, Mason D W. Induction of Ia antigen in rat epidermal cells and gut epithelium by immunological stimuli. *J Exp Med* 1982; **156**: 1665-76.
- Volc-Platzer B, Majdic O, Knapp W, *et al.* Evidence of HLA-DR antigen biosynthesis by human keratinocytes in disease. *J Exp Med* 1984; **159**: 1784-8.
- Hart D N J, Fungge S V, Williams K A, *et al.* Localization of HLA-ABC and DR antigens in human kidney. *Transplantation* 1981; **31**: 428-33.
- Hall B M, Duggin G G, Philips J, *et al.* Increased expression of HLA-DR antigens on renal tubular cells in renal transplants: relevance to the rejection response. *Lancet* 1984; **ii**: 247-51.
- Lampert I A, Janossy G, Suitters A J, *et al.* Immunological analysis of the skin in graft-versus-host disease. *Clin Exp Immunol* 1982; **50**: 123-31.
- Bottazzo G F, Pujol-Borrell R, Hanafusa T, Feldmann R. Role of aberrant HLA-DR expression and antigen presentation in induction of endocrine autoimmunity. *Lancet* 1983; **ii**: 1115-8.
- Detrick B, Newsome D A, Percopo C, Hooks J J. Class II antigen expression and gamma interferon modulation of monocytes and retinal pigment epithelial cells from patients with retinitis pigmentosa. *Clin Immunol Immunopathol* 1985; **36**: 201-11.
- Tarpley T M, Anderson L G, White C L. Minor salivary gland involvement in Sjögren's syndrome. *Oral Surg* 1974; **37**: 64-74.
- Moutsopoulos H, Fauci A. Immunoregulation in Sjögren's syndrome. Influence of serum factors on T-cell subpopulations. *J Clin Invest* 1980; **65**: 519-28.
- Fauci A, Moutsopoulos H. Polyclonally triggered B-cells in the peripheral blood of normal individuals and in patients with SLE and primary Sjögren's syndrome. *Arthritis Rheum* 1982; **24**: 557-84.
- Lane H C, Callihan T R, Jaffe R S, Fauci A S, Moutsopoulos H M. Presence of intracytoplasmic IgG in the lymphocyte infiltrates of the minor salivary glands of patients with primary Sjögren's syndrome. *Clin Exp Rheumatol* 1983; **1**: 237-9.
- Lampson L, Levy R. Two populations of Ia-like molecules on human B-cell line. *J Immunol* 1980; **125**: 293-9.
- Hamburger M I, Moutsopoulos H M, Lawley T J, Frank M M. Sjögren's syndrome: a defect in reticuloendothelial systems Fc-receptor-specific clearance. *Ann Intern Med* 1979; **91**: 534-8.
- Miyasaka N, Sauvezie B, Pierce D, *et al.* Decreased autologous mixed lymphocyte reaction in Sjögren's syndrome. *J Clin Invest* 1981; **66**: 928-33.
- Miyasaka N, Sauvezie B, Raff H, *et al.* T-cell macrophage subset interactions and decreased autologous mixed lymphocyte reaction in Sjögren's syndrome. *Rheumatol Int* 1983; **3**: 13-7.
- Lindhal G, Hedfors E, Klareskog L, Forsum U. Epithelial HLA-DR expression and T-lymphocyte subsets in salivary glands in Sjögren's syndrome. *Clin Exp Immunol* 1985; **61**: 475-82.