

## Lymphadenopathy in rheumatic patients

C A KELLY, A J MALCOLM, AND I GRIFFITHS

*From the Departments of Rheumatology and Pathology, Royal Victoria Infirmary, Newcastle upon Tyne*

**SUMMARY** Lymph node biopsy specimens from 22 patients with chronic inflammatory joint disease have been studied. The histology has been reviewed and immunoperoxidase staining carried out for the major immunoglobulin heavy and light chains, macrophage markers, and MT1, MB1 surface markers. Although two of these patients had been initially diagnosed and treated for malignant lymphoma, the clinical course has not substantiated the diagnosis, and on review malignancy could not be identified in any of the biopsy specimens. Careful attention to specific histological features, together with adequate clinical information, is therefore essential if the true nature of the lymph node enlargement is to be recognised. Clinical review of the 22 patients suggested that lymphadenopathy may, in some cases, be an early feature of inflammatory polyarthritis, and this was supported by the observation that 20% of patients with otherwise unexplained reactive lymphadenopathy developed an inflammatory polyarthropathy within one year of biopsy.

**Key words:** lymphoma, rheumatoid arthritis, immunoglobulins.

Lymph node enlargement often causes clinical concern, especially when it is associated with systemic symptoms such as weight loss, anaemia, and malaise. The anatomical site, e.g., supraclavicular fossa, may enhance the suspicion of malignancy. Although lymphadenopathy in association with chronic inflammatory joint disease is well described,<sup>1,2</sup> there may be a strong indication for biopsy, especially if lymph node enlargement occurs before clinical, radiological, or serological stigmata of joint disease are present. These indications may be further strengthened by the described association between rheumatoid arthritis and malignant lymphoma.<sup>3</sup> Resolution of the problem may be difficult histologically as the lymph node in rheumatoid disease may mimic lymphoma.<sup>4</sup> This report emphasises the clinical and pathological features of lymphadenopathy in 22 patients with inflammatory joint disease.

### Patients and methods

Twenty two patients with chronic inflammatory joint disease and significant lymphadenopathy were identified. Sixteen of these had classical seropositive rheumatoid arthritis.<sup>5</sup> Half of these were male, and

the mean age of the group was 54 years (range 38–75 years), with a mean disease duration of seven years (range one month to 20 years). Two patients had adult Still's disease and two had Sjögren's syndrome with a non-destructive polyarthritis. Both these patients had a monoclonal gammopathy with a normal bone marrow. One patient had an asymmetrical seronegative polyarthritis and one was considered to have palindromic rheumatism.

Lymph node biopsies were performed on all patients because various clinical features raised the possibility of coexistent malignant disease. Indications for biopsy are shown in Table 1.

Two patients with rheumatoid arthritis were considered to have malignant lymphoma from the histology of their node biopsy. Brief case histories are presented below:

One of the patients was a 47 year old woman with a 13 year history of classical rheumatoid arthritis who presented to her family doctor with right axillary lymphadenopathy. She was referred to a surgical unit at a hospital not involved in the management of her rheumatoid disease. Biopsy was undertaken, and the histology was initially interpreted as showing lymphoma, and she consequently received a course of radiotherapy.

The other patient was a 65 year old man with an 11 year history of classical rheumatoid arthritis, admitted with a perforated gastric ulcer. Again the

Accepted for publication 15 August 1986.

Correspondence to Dr A J Malcolm, Dept of Pathology, Royal Victoria Infirmary, Newcastle upon Tyne NE1 4LP.

Table 1 Indications for lymph node biopsy in 22 patients with rheumatic disease

	No of patients	Weight loss	Gammopathy	Organomegaly	Marked lymphadenopathy
Rheumatoid arthritis	16	4	0	3	9
Still's disease	2	0	0	2	0
Seronegative arthritis	1	0	0	0	1
Sjögren's syndrome	2	0	2	0	0
Palindromic rheumatism	1	0	0	0	1

hospital was not involved with the management of his rheumatoid disease. He underwent partial gastrectomy, and at laparotomy mesenteric lymphadenopathy was noted and a biopsy specimen taken. This was initially interpreted as showing lymphoma, and he received a course of radiotherapy.

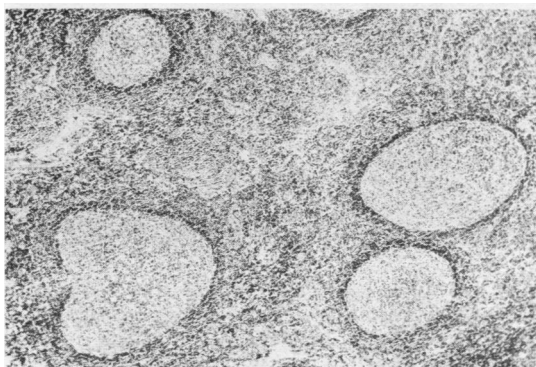


Fig. 1 Follicular hyperplasia within a rheumatoid lymph node. (Haematoxylin and eosin).

The majority of the biopsy specimens were taken from the supraclavicular and cervical areas (13 patients) and most of the others from the axilla (six patients). Five of the patients (23%) underwent biopsy within one year of the onset of joint symptoms. Sections from all blocks of the biopsy specimens were recut from each case and stained with haematoxylin and eosin, periodic acid-Schiff reagent after treatment with diastase, and Perls' stain for iron and reticulin silver impregnation. A standard peroxidase-antiperoxidase technique<sup>6</sup> was performed to assess the distribution of immunoglobulin and macrophages. The distribution of MT1 and MB1 positive cells (Eurodiagnostics-T and B cell antibodies for fixed tissue preparations) was also assessed on a representative block for each case. All sections were examined by two independent observers. The criteria assessed are well standardised.<sup>7</sup> No fresh tissue was available to allow T cell subsets to be examined.

### Results

The commonly encountered histological features of the nodes were capsular thickening and marked

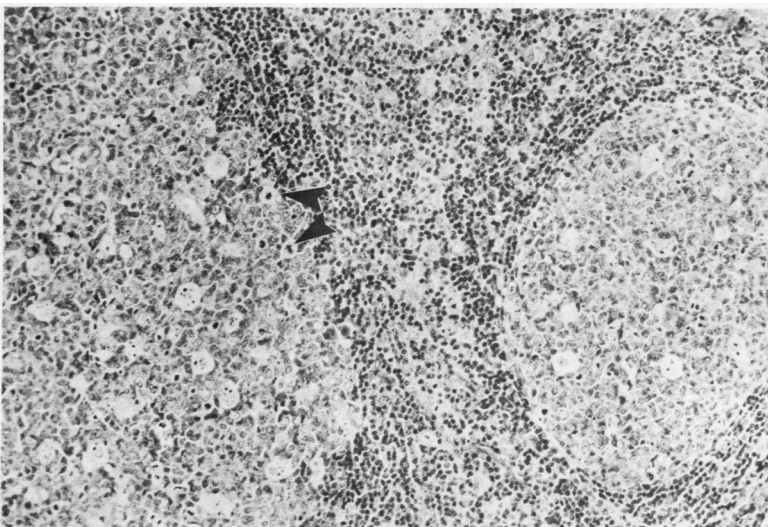


Fig. 2 Two large germinal centres with tingible body macrophages, mitoses (arrow), and some prominent interfollicular blood vessels. (Haematoxylin and eosin).

follicular hyperplasia with large, sometimes irregular follicles but retention of the normal follicular architecture of the lymph node (Fig. 1). There were many mitoses, which were confined to the germinal centres, and there was a polymorphous cell population with tingible body macrophages within the centres. Interfollicular areas showed prominent vascularity with many plasma cells and only occasional mitotic figures (Fig. 2). There was no compression of reticulin fibres within the node. All these latter features helped to separate a reactive follicular hyperplasia from a follicular lymphoma because in lymphoma the follicles have a more uniform population of cells, show mitoses in the interfollicular area in addition to those within the follicles, and plasma cells are scarce.<sup>8</sup> The reticulin fibres in lymphoma tend to be compressed.<sup>9</sup>

The distribution of MT1 positive cells (all non-B lymphoid cells) within the interfollicular areas and MB1 positive cells (B lymphoid cells) in the germinal centres with diffuse extrafollicular scatter was as expected in a reactive node (Figs 3a and b). The

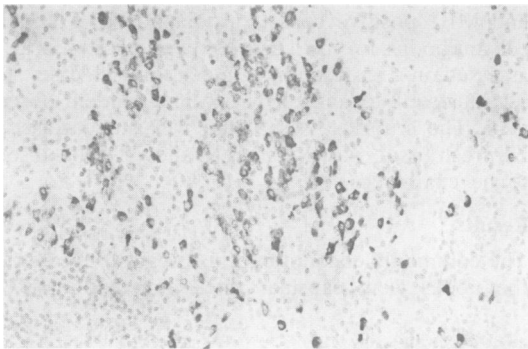


Fig. 3a

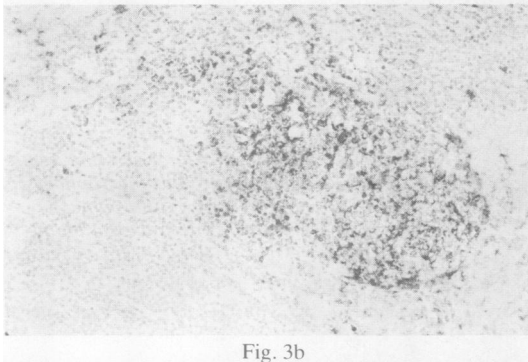


Fig. 3b

Fig. 3 (a) Scattered darkly staining T cells in an interfollicular area. MT1 using peroxidase-antiperoxidase (PAP) technique. (b) Darkly staining B cells in a follicle. MB1 using PAP technique.

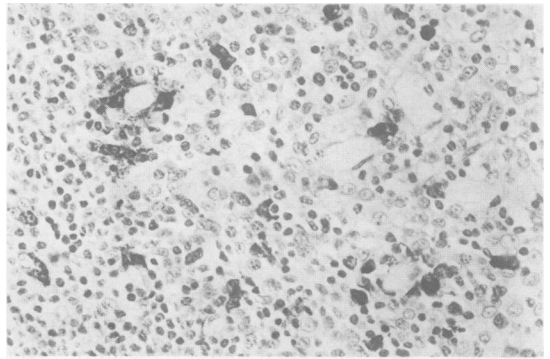


Fig. 4a

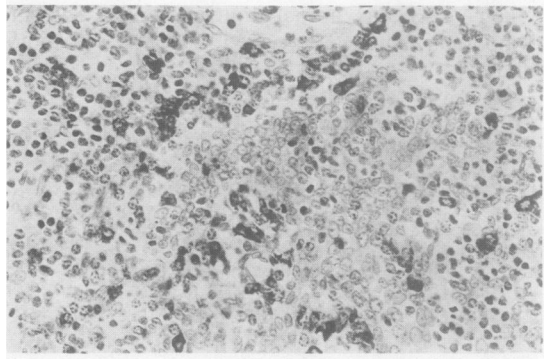


Fig. 4b

Fig 4 (a) Kappa light chains in lymphoid cells (darkly staining). PAP technique. (b) Lambda light chains in lymphoid cells (darkly staining). PAP technique.

distribution of light and heavy chains of the major immunoglobulin classes was easily shown and had a polyclonal distribution in every case, including those patients with gammopathy (Figs 4a and b). This is a helpful feature in that follicular lymphoma tends either to have little or no immunoglobulin production within the follicles and, when present, it is usually monoclonal.<sup>10</sup> Malignancy was not identified in any of the cases despite the original diagnosis of lymphoma in two patients. The confidence of this statement relies to some extent on the immunohistochemistry. Clinical follow up for four years after completion of radiotherapy could not substantiate the original diagnosis of lymphoma. It was disappointing that there were no histological or immunohistochemical features in the lymph nodes that could be used to separate the different rheumatological conditions causing the lymphadenopathy.

### Discussion

Clinically detectable lymphadenopathy has been described in the majority of patients with rheuma-

toid arthritis.<sup>1</sup> Robertson *et al* have shown the observed incidence of lymphadenopathy in rheumatoid patients to be significantly higher than that in a matched hospital control group.<sup>2</sup> The increased incidence was almost entirely due to axillary lymphadenopathy. Therefore clinical concern remains regarding the aetiology of cervical and supraclavicular lymph node enlargement in patients with rheumatoid arthritis, and this is reflected in the fact that 59% of our patients had their biopsies for lymphadenopathy at these sites.

There is conflicting evidence about the association of rheumatoid arthritis and lymphoma.<sup>11 12</sup> Despite the initial diagnosis of lymphoma in two of our patients with rheumatoid arthritis, there was no evidence of malignant disease on review of the histology. The increased risk of lymphoma in patients with Sjögren's syndrome is well documented,<sup>13</sup> but the histological features of our patients with this condition were indistinguishable from the other cases. The lymph nodes showed a polyclonal distribution of immunoglobulin which did not reflect the serum monoclonal gammopathies. Predominance of either  $\kappa$  or  $\lambda$  light chains would support the diagnosis of well differentiated malignant lymphoma, and this may be a useful means of discrimination between benign and malignant causes of monoclonal gammopathy.

The difficulty in distinguishing the histology of florid reactive hyperplasia in some patients with rheumatoid disease from follicle centre or immunoblastic lymphoma has been stressed previously.<sup>4</sup> In both our cases where lymphoma was originally diagnosed the reporting pathologist was unaware of the rheumatic condition and was presented with a clinical history suggestive of malignancy.

The situation may be complicated by the development of lymphadenopathy before the onset of joint symptoms. A complementary study was set up to study 72 patients who had previously had lymph node biopsies for unexplained lymphadenopathy, the histology of which had shown pure reactive hyperplasia. Spontaneous remission occurred in seven patients and no cause was determined for the lymphadenopathy in another 11. Of the 54 patients who did develop a related disease, 16 had or

developed an inflammatory polyarthropathy, this being classical rheumatoid arthritis in nine and an inflammatory polyarthropathy in another four. Although the diagnosis of arthropathy had been previously established in half the patients with joint disease, there remained sufficient clinical concern to justify node biopsy. In the cases where lymphadenopathy predated other symptoms the arthropathy became apparent within one year of biopsy.

It is important that the clinician appreciates the relation between lymphadenopathy and early joint disease, and it is clearly mandatory that the reporting pathologist is made aware of any coexistent rheumatic disease so that detailed attention to the histological features already noted may prevent a serious misdiagnosis of lymphoma.

#### References

- 1 Cruikshank B. Lesions of lymph nodes in rheumatoid arthritis and in disseminated lupus erythematosus. *Scott Med J* 1958; **3**: 110-9.
- 2 Robertson M D J, Dudley Hart F, White W F, Nuki G, Boardman P L. Rheumatoid lymphadenopathy. *Ann Rheum Dis* 1968; **27**: 253.
- 3 Lea A J. An association between the rheumatic diseases and the reticuloses. *Ann Rheum Dis* 1964; **23**: 480-4.
- 4 Motulsky A G, Weinburg S, Saphir O, Rosenberg E. Lymph nodes in rheumatoid arthritis. *Arch Intern Med* 1952; **90**: 660.
- 5 A committee of the American Rheumatism Association. Diagnostic criteria for rheumatoid arthritis 1958 revision. *Ann Rheum Dis* 1959; **18**: 49-51.
- 6 Burns J. Immunohistochemical methods and their application in the routine laboratory. In: Anthony P P, Woolf N, eds. *Recent advances in histopathology*. No 10. Edinburgh, London and New York: Churchill Livingstone, 1978.
- 7 Rappaport H, Winter W J, Hicks E B. Follicular lymphoma: a re-evaluation of its position in the scheme of malignant lymphoma, based on a survey of 253 cases. *Cancer* 1956; **9**: 792-821.
- 8 Dorfman R F, Warnke R. Lymphadenopathy simulating the malignant lymphomas. *Hum Pathol* 1974; **5**: 519-50.
- 9 Robb-Smith A H T, Taylor C R. *Lymph node biopsy* London: Heyden, 1981: 56-60.
- 10 Wright D H, Isaacson P G. *Biopsy pathology of the lymphoreticular system*. London: Chapman and Hall, 1983: 171-4.
- 11 Cammarata R J, Rodnan G P, Jensen W N. Systemic rheumatic diseases and malignant lymphoma. *Arch Intern Med* 1963; **111**: 330-7.
- 12 Nosanchuk J S, Schnitzer B. Follicular hyperplasia in lymph nodes from patients with rheumatoid arthritis: a clinicopathological study. *Cancer* 1969; **24**: 343-54.
- 13 Azzopardi J D, Evans D J. Malignant lymphoma of parotid associated with Mikulicz disease (benign lymphoepithelial lesion). *J Clin Pathol* 1971; **24**: 744-52.