

Case report

Evolution of benign rheumatoid nodules into rheumatoid arthritis after 50 years

ALEJANDRO OLIVÉ,¹ JUAN MAYMO,¹ JOSÉ LLORETA,²
JOSÉ COROMINAS,² AND JORGE CARBONELL¹

From the ¹Department of Rheumatology and the ²Department of Pathology, Hospital General Mare de Dèu de l'Esperança, Barcelona, Spain

SUMMARY A patient with benign rheumatoid nodules who developed rheumatoid arthritis after 50 years is described.

Benign rheumatoid nodules of childhood were described in 1959 as an entity characterised by development of nodules, histologically indistinguishable from rheumatoid nodules, in children, without development of rheumatoid arthritis in a long term follow up.¹ In the past few years, however, several examples of patients who developed rheumatoid arthritis many years after being diagnosed as having benign rheumatoid nodules in childhood have been reported.

We describe a patient who we believe illustrates this atypical evolution of benign rheumatoid nodules of childhood.

Case report

At the age of 10 a boy developed nodules over the elbows. These were non-tender, not mobile, and remained unchanged until the patient was 55, when he developed new nodules over the dorsum of his feet.

The patient presented to us, aged 60, with symmetrical polyarthritis which had begun six months earlier, involving wrists, metacarpophalangeal, proximal interphalangeal, and distal interphalangeal joints, and with morning stiffness lasting an hour. Physical examination showed synovitis of these joints and nodules over the elbows, the dorsum of his feet, and the anterior tibia. Laboratory data were: erythrocyte sedimentation rate 26

mm/h (Westergren); haemoglobin 141 g/l; rheumatoid factor 2100 IU/ml; C reactive protein 7.3 mg/l; antinuclear antibodies were positive with homogeneous pattern. Radiographic examination did not show erosions.

Biopsy specimens were obtained from the old nodules (elbows) and from the new ones (dorsum of the feet). The recent nodules (Fig. 1) demonstrated dense connective tissue surrounding palisading granulomas with central fibrinoid necrosis and prominent perivascular infiltrate of lymphoplasmocytic cells (Fig. 1). The old nodules showed denser connective tissue surrounding necrotic nodular areas without peripheral palisading, irregular collections

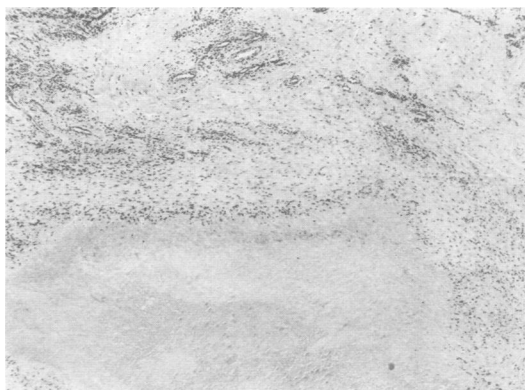

Fig. 1 *Foot nodules. Palisading histiocytes surrounding foci of necrosis and perivascular lymphoplasmocytic infiltration are evident. (Haematoxylin and eosin.)*

Accepted for publication 2 March 1987.

Correspondence to Dr Alejandro Olivé, Department of Rheumatology, Hospital General Mare de Dèu de l'Esperança, St Josep de la Muntanya 12, 08024 Barcelona, Spain.

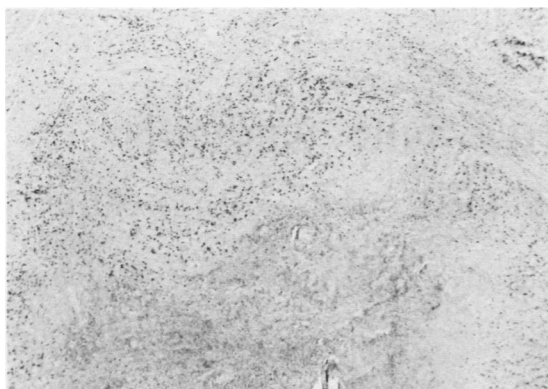


Fig. 2 Elbow nodules. Necrotic foci are surrounded by fibrotic tissue with interspersed histiocytes. There is no palisading around the necrotic tissue. (Haematoxylin and eosin.)

of histiocytes and similar perivascular infiltrate of lymphoplasmocytic cells (Fig. 2).

In conclusion, nodules from the dorsum of his feet were typical of active rheumatoid nodules, while histological features of nodules from the elbows suggested longstanding rheumatoid nodules.

When all the findings were considered the patient was diagnosed as seropositive nodular rheumatoid arthritis.

Discussion

In 1959 Draheim reported 54 children who developed subcutaneous nodules, histologically indistinguishable from rheumatoid nodules, but who did not demonstrate any evidence of rheumatic disease. These patients were followed up for periods of one to 14 years and only one case of rheumatic fever was diagnosed.¹

Subsequent reports with follow ups of between one and 12 years have confirmed the lack of association between benign nodules and rheumatoid arthritis.²⁻⁶

Initial reports do not mention positivity for rheumatoid factor, and in the few cases in which it was determined, positivity was rare. Berardinelli described 10 children with benign nodulosis in whom rheumatoid factor became positive between two and 16 years after developing nodules without evolving into rheumatoid disease.⁷

In 1985 Rush reported two cases of children with benign nodules who developed joint disease seven and 15 years after their initial presentation with nodules.⁸

Our patient presented with nodules without associated disease at the age of 10. These nodules remained localised and unchanged until 50 years later when he presented with seropositive symmetrical arthritis and developed new nodules, fulfilling the diagnosis of classic rheumatoid arthritis.

Therefore we conclude that development of nodules, histologically typical of rheumatoid nodules, in children otherwise healthy, can be diagnosed as benign rheumatoid nodulosis of childhood, an entity that bears an excellent prognosis, though some of the affected children, after a free interval of up to 50 years, may develop rheumatoid arthritis.

References

- 1 Draheim J H, Johnson L C, Helwig E B. A clinicopathologic analysis of rheumatoid nodules occurring in 54 children. *Am J Pathol* 1959; **35**: 678.
- 2 Caughey D E, Calabro J J, Craciola A, Goldberg L S, Pearson C M. Benign rheumatoid nodules in children [Abstract]. *Arthritis Rheum* 1969; **12**: 285.
- 3 Burringon J D. Pseudorheumatoid nodules in children: report of ten cases. *Pediatrics* 1970; **45**: 473-8.
- 4 Pournaras J, Gibson A A M. 'Pseudorheumatoid' nodules in children. *J Bone Joint Surg [Br]* 1971; **53**: 724-8.
- 5 Estelle F, Schaller J G. Benign rheumatoid nodules. *Pediatrics* 1975; **56**: 29-33.
- 6 Mesara B N, Brody G L, Oberman H A. Pseudorheumatoid subcutaneous nodules. *Am J Clin Pathol* 1966; **45**: 684-91.
- 7 Berardinelli J L, Hyman C J, Campbell E E, Fireman Ph. Presence of rheumatoid factor in ten children with isolated rheumatoid like nodules. *J Pediatr* 1972; **81**: 751-6.
- 8 Rush P J, Bernstein B H, Smith C R, Shore A. Chronic arthritis following benign rheumatoid nodules of childhood. *Arthritis Rheum* 1985; **28**: 1175-8.