

## A system of canals in semilunar menisci

M D T BIRD AND M B E SWEET

*From the Bone and Joint Research Unit of the South African Medical Research Council and the University of the Witwatersrand, Johannesburg, South Africa*

**SUMMARY** Semilunar menisci of young calves, and infants and young children were examined with the scanning electron microscope and the light microscope. Canal-like structures were noted opening onto the surface of the menisci. After filling the joints with Indian ink, ink was noted within canal-like structures deep in the substance of the tissue. The canals may play a part in the transport of fluid within the meniscus, or may carry nutrients from the synovial fluid or the blood vessels to the avascular sections of the meniscus.

The semilunar menisci are fibrocartilaginous structures, which play an important part in the function of the knee: they stabilise the joint and transmit load from the femur to the tibia.<sup>1</sup> They are thought to facilitate lubrication.<sup>2</sup> It is known that developing menisci are different from those of adolescents and adults: they contain more vessels, are much more cellular, and may have greater reparative properties.<sup>3</sup>

A number of workers have studied the surface of menisci using the scanning electron microscope: the femoral and tibial surfaces are similar and show ridges and grooves running predominantly in the long axis of the tissue,<sup>4,5</sup> which may be due to shrinkage.<sup>6</sup> Humps have been observed on the surface of the menisci of children.<sup>6,7</sup>

In this study we have used the scanning electron microscope and the light microscope to examine the surface of menisci of young children and new born calves. We present evidence for the existence of a system of canaliculi linking the surface with the depths of the tissue.

### Materials and methods

Human knee joints were obtained from two stillborn individuals and after death from subjects aged 3 weeks, 1 year, 3 years, and 6 years. After examination of some of the specimens the possibility of postmortem artefactual changes was considered. Consequently, knee joints of six near term fetal

calves and of six three month old calves obtained from the abattoir immediately after slaughter were studied in parallel.

Freshly dissected menisci were fixed in 2% paraformaldehyde in 0.2 M phosphate buffer, pH 7.3, for 48 hours. After stepwise dehydration in alcohol the specimens were placed in a critical point dryer, affixed to aluminium stubs, and coated with gold. Specimens were viewed in a JOEL 25S scanning electron microscope.

The joint capsule was kept intact, and the knee joints of three calves and two infants were infused with Indian ink. The joints were extensively flexed and compressed for an hour. Thereafter the menisci were excised, fixed, and embedded in wax. Sections of 7  $\mu$ m were stained with haematoxylin and eosin or alcian blue and nuclear fast red. Some specimens were embedded in methacrylate and cut on a Jung K microtome.

### Results

The results presented refer to the superior and inferior surfaces of the semilunar menisci taken from both the medial and lateral side.

The calf menisci were about as large as adult human menisci but were about twice as thick on the attached edge. The surface was smooth and glistening when viewed with the naked eye or through the dissecting microscope at a magnification of 20 $\times$ . The inner free edge was intact. Regular concentric ridges were visible on both superior and inferior surfaces.

With the scanning electron microscope large, roughly oval shaped apertures were visible at a

Accepted for publication 31 March 1987.  
Correspondence to Dr M B E Sweet, Department of Orthopaedic Surgery, Medical School, York Road, Parktown 2193, South Africa.

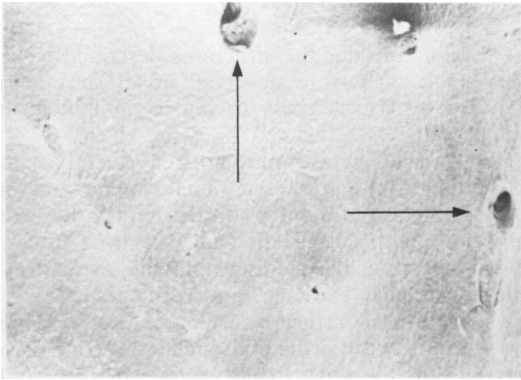


Fig. 1 *Surface of meniscus from three month old calf showing large crater-like openings.*

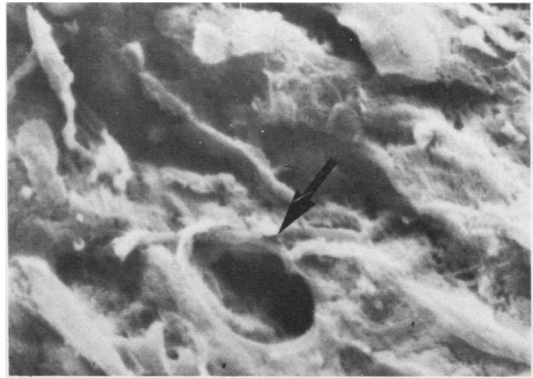

Fig. 3 *Surface of meniscus from new born infant showing a defined opening.*

magnification of 45 $\times$  (Fig. 1). At higher magnification (300 $\times$ ) the apertures appeared to resemble shafts, into the depths of which opened further apertures (Fig. 2). The narrowest diameter of these structures was approximately 200  $\mu\text{m}$ . These structures were surrounded by large numbers of smaller apparent holes with a definite limbus (15–20  $\mu\text{m}$  in diameter), giving the plateau a porous appearance (Fig. 2). There was no significant difference between the menisci of the fetal and the three month old animals.

Examination of infant human material did not show any apertures resembling the large openings of 200  $\mu\text{m}$  diameter. The general appearance of the surface of the menisci was as described by others.<sup>6</sup> At higher magnification (2000 $\times$ ), however, small

openings of between 10 and 60  $\mu\text{m}$  diameter were clearly visible (Fig. 3). These were structurally similar to those seen in the calf menisci, but more sparsely distributed. The structures were seen at all ages studied.

Calf menisci were examined in the light microscope both with and without Indian ink treatment. In a cross section canal-like structures were clearly visible between cross cut collagen bundles (Fig. 4). The structures had definite but acellular walls. They were distinguished from blood vessels as they had no muscular wall and no adventitia. Furthermore, many were of larger diameter than adjacent blood vessels. Indian ink was found to be present within the lumen of some of the canals (Fig. 5).

When the human menisci were examined in the

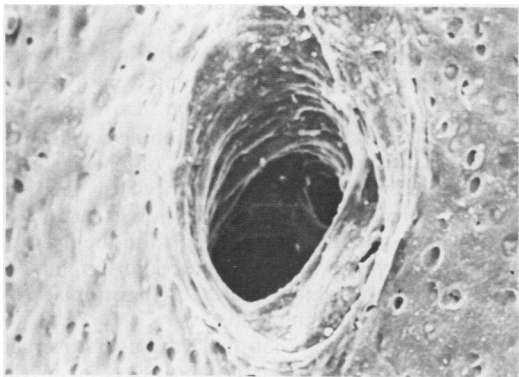


Fig. 2 *Surface of meniscus from calf showing detail of opening with further openings in its depths. Smaller openings are shown on the surrounding surface.*

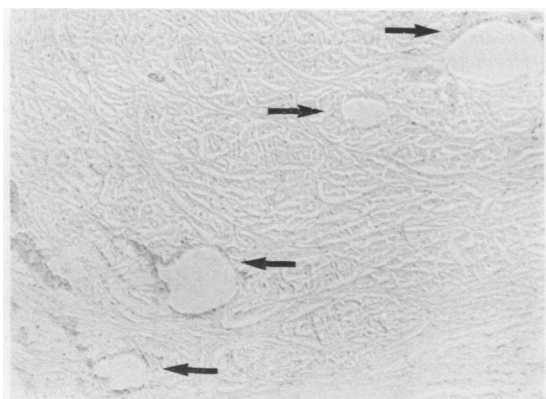


Fig. 4 *Histological section of calf meniscus showing canals in a cross section. (Haematoxylin and eosin.)*

light microscope it was appreciated that the canals would be of a very much smaller size than in the calf. Nonetheless, we did see canals opening onto the surface, which were filled with Indian ink (Fig. 6). In addition, Indian ink was noted in canals or loosely packed tissue deep within the meniscus, some of which surrounded blood vessels near the attached edge (Fig. 7).

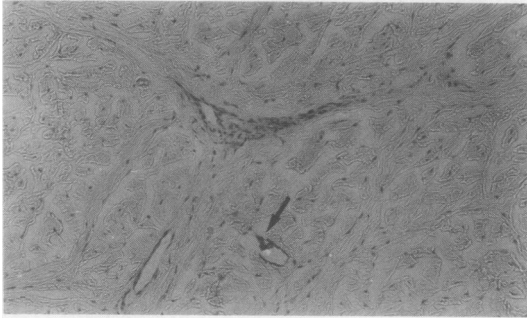


Fig. 5 Calf meniscus showing canal containing Indian ink, adjacent to blood vessels. (Haematoxylin and eosin.)




Fig. 6 Human meniscus showing canal opening onto the surface and containing Indian ink. The canal appears to be continuous with a reticular system as marked. (Haematoxylin and eosin.)

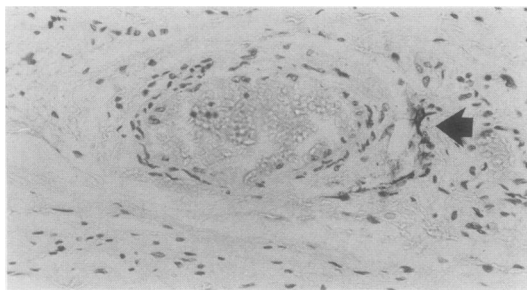


Fig. 7 Human meniscus showing arteriole close to the attached edge. The marker indicates Indian ink present within loosely packed tissue surrounding the vessel.

## Discussion

We do not consider the structures described to be artefactual: they were observed in all specimens prepared by critical point drying or embedded in methacrylate.

Because the menisci play an important part in distributing stress over the tibial plateau and in guiding rotation of the tibia on the femur, they are subject to both compressive and shearing forces. This implies that the meniscus must be as deformable as articular cartilage, and resilient.

It is known that articular cartilage is compressible and deformable by virtue of its high water content, a function of the high fixed charge density and proteoglycan content.<sup>8</sup> The menisci, too, contain proteoglycans, which are in many respects similar to those found in articular cartilage.<sup>9,10</sup> The water content of meniscus is about 68% in adults and 80% in infants (Bird and Sweet, unpublished data); a proportion of this is presumably held by the osmotic pressure generated by the ions and counterions surrounding the anionic proteoglycans. The system of canals we have described may play a part in permitting the rapid flow of water from one section of the meniscus to another during weight bearing.

The surface openings of the canals seen in the calf specimens were very much larger than those seen in human material. The menisci themselves were virtually the size of adult human menisci. Whatever the function of the canals, it seems likely that the functional demands of walking immediately after birth may call for greater efficiency of the system in the calf. At present it is not known whether such a system persists into adulthood.

In man there is a well developed vascular supply to the menisci: a perimeniscal circular vascular ring supplies the peripheral attached region and sends radial branches into the substance of the meniscus.<sup>11</sup> In the fetus vessels are to be found throughout the meniscus.<sup>3</sup> We are aware that diffusion from the synovial fluid is a commonly accepted pathway for nutrients entering both articular cartilage and meniscus. The Indian ink experiments showed that the canals within the substance of the menisci communicate with the synovial cavity. It is possible that the canals provide an additional means of transporting synovial fluid through the menisci for nutritional purposes. This system could supplement a vascular supply, which would be compromised by the pressure of normal load.

Canals containing Indian ink were also observed immediately surrounding blood vessels near the attached edge of the infant meniscus. This, on the other hand, suggests the possibility of the canals transporting a nutrient transudate of serum from

this region of the meniscus through the tissue and out into the synovial fluid.

This work was supported by the South African Medical Research Council, the Orthopaedic Research Foundation, and the Slome Orthopaedic Trust Fund. The authors thank Professor A Davies, Mr G van Sittert, and Mrs G Brunton of the National Council for Occupational Health for assistance with scanning electron microscopy.

#### References

- 1 Shrive N, O'Connor J J, Goodfellow J W. Load-bearing in the knee joint. *Clin Orthop* 1974; **131**: 279-87.
- 2 Duthie R B, Bentley G. *Mercer's orthopaedic surgery*. London: Arnold, 1983: 977-8.
- 3 Clark C R, Ogden J A. Development of the menisci of the human knee joint. *J Bone Joint Surg [Am]* 1983; **65A**: 536-47.
- 4 Cameron H U, MacNab I. The structure of the meniscus of the human knee joint. *Clin Orthop* 1972; **89**: 215-9.
- 5 Cameron H U, MacNab I. Lesions of the menisci in man: a scanning electron microscope study. *Scan Electron Microsc* 1973: 667-74.
- 6 Ghadially F N. Fine structure of joints. In: Sokoloff L, ed. *The joints and synovial fluid*. New York: Academic Press, 1978: 105-76.
- 7 Refior H J. Altersabhängige Veränderungen der Meniscusoberfläche Untersuchungen mit dem Rasterelektronenmikroskop. *Archiv für Orthopädische und Unfallchirurgie* 1971; **71**: 316-23.
- 8 Bayliss M T, Venn M. Chemistry of human articular cartilage. In: Maroudas A, Holborow E J, eds. *Studies in joint disease I*. Tunbridge Wells: Pitman Medical, 1980: 2-58.
- 9 Roughley P J, McNicol D, Santer V, Buckwalter J. The presence of a cartilage-like proteoglycan in the adult human meniscus. *Biochem J* 1981; **197**: 77-83.
- 10 Webber R J, Norby D P, Malesud C J, Goldberg V M, Moskowitz R W. Characterization of newly synthesized proteoglycans from rabbit menisci in organ culture. *Biochem J* 1984; **221**: 875-84.
- 11 Arnoczy S P, Warren R F. Microvasculature of the human meniscus. *Am J Sports Med* 1982; **10**: 90-5.