

Anterior Vertebral Body Tethering for Scoliosis Patients With and Without Skeletal Growth Remaining: A Retrospective Review With Minimum 2-Year Follow-Up

THEODOR DI PAULI VON TREUHEIM, MD¹; LILY EAKER, BA¹; JONATHAN MARKOWITZ, MD¹;
DHRUV SHANKAR, BS¹; JAMES MEYERS, BA¹; AND BARON LONNER, MD¹

¹Department of Orthopaedic Surgery, Mount Sinai Hospital, New York, NY, USA

ABSTRACT

Background: Anterior vertebral body tethering (AVBT) has been approved for skeletally immature (IM) adolescent idiopathic scoliosis patients, but the role of AVBT in patients with minimal remaining skeletal growth is controversial. The purpose of this study was to compare minimum 2-year (YR2) outcomes in skeletally IM patients vs those with minimal remaining skeletal growth.

Methods: Patients with single thoracic AVBT were grouped by their preoperative (PR) skeletal maturity: IM ($n = 16$, Risser 0–2) vs mature (M, $n = 19$, Risser 3–5). Outcomes were assessed at PR, first erect (FE), and YR2. Median (range) was compared with nonparametric tests ($P < 0.05$).

Results: The PR age was 12.5 (9–16) vs 15 (12–18) years with major Cobb 51° (36°–69°) and 49° (40°–69°) for IM and M, respectively. At FE, there was no difference in correction; however, at YR2, the IM group yielded a lower residual curve (15° [–16° to 38°] vs 29° [12°–42°], $P = 0.008$). Thoracolumbar/lumbar curves were corrected without group differences. Clinically successful correction (<35°) (15 [94%] vs 15 [79%]) and suspected cord breakages (2 [13%] vs 2 [12%]) were similar at YR2. Two overcorrections occurred, both in IM patients. Scoliosis Research Society-22 outcomes at final follow-up were similar between groups. No revision reoperations or conversions to spinal fusion were needed.

Conclusions: Skeletally IM patients benefit from greater growth-modulated curve correction than M patients, however, at the increased risk of overcorrection. M patients maintained clinically significant correction at latest follow-up. Longer-term follow-up is required to determine durability of outcomes for patients undergoing AVBT who have minimal remaining growth at the time of index surgery.

Clinical Relevance: This study is relevant to spine surgeons, spine physiotherapists, and patients with idiopathic scoliosis. It offers evidence of clinical correction of scoliosis in mature patients.

Level of Evidence: 3.

Other and Special Categories

Keywords: vertebral body tethering, scoliosis, non-fusion surgery, adolescent idiopathic scoliosis

INTRODUCTION

Adolescent idiopathic scoliosis (AIS) is the most common pediatric spinal deformity.^{1–3} Posterior spinal fusion (PSF), the gold standard operative treatment, is associated with potential long-term complications such as degenerative disc disease, back pain, radiculopathy, and loss of mobility.^{4,5} Anterior vertebral body tethering (AVBT) received US Food and Drug Administration Humanitarian Device Exemption approval in 2019 and has become an alternative to PSF for skeletally immature (IM) patients.^{5–9} AVBT depends on skeletal growth potential that is harnessed for progressive correction in accordance with the Hueter-Volkman law,^{1,2,10,11} as borne out in animal models,^{12–15} finite element analysis,^{16–18} and clinical case series.^{5–7,9,19–22} Initial series containing skeletally IM patients (Risser 0–1) have

yielded high overcorrection rates^{19,20} necessitating revision surgery or conversion to PSF.^{5,8,9} AVBT remains a promising approach,²³ and recent evidence suggests delaying the procedure to mitigate against overcorrection.⁶

AVBT is unproven in skeletally mature (M) patients, given growth modulation cannot occur, but the expansion of indications to those with minimal remaining skeletal growth would provide a treatment alternative to 21% of patients for whom fusion has been the only option.²⁴ To date, most studies have reported on AVBT results in IM patients, and thus evaluation of long-term outcomes comparing IM and M patients is warranted to evaluate ideal indications, timing, as well as the ideal amount of surgical correction vs anticipated growth modulation.^{5,6,9,19} The senior author gained experience

with the M population after patients who initially had significant remaining growth presented months after the initial consultation for surgery. However, the clinical success appeared consistent eventually leading to an expansion of indications. The aim of this study was to compare 2-year (YR2) radiographic and clinical outcomes of thoracic AVBT in patients with AIS who underwent surgery before their skeletal growth acceleration phase vs patients with minimal remaining growth.

PATIENTS AND METHODS

Following Institutional Review Board approval, a prospectively maintained database was retrospectively reviewed for consecutive AIS patients undergoing AVBT of a thoracic major curvature. All surgeries were conducted by a single surgeon between 2016 and 2018 in patients ≤ 18 years old at the time of surgery with a main thoracic curve 40° to 70° and minimum of YR2 follow-up. Indications for surgery in both groups followed standard clinical indications including curve progression and/or the potential for curve progression, clinical deformity, and pain. Skeletal maturity was measured preoperatively and throughout follow-up, according to the ossification of the iliac apophysis (Risser sign) and proximal humeral physis (proximal humerus ossification system [PHOS]). Patients were stratified by Risser, with bone age at or leading up to the growth acceleration phase being designated as skeletally IM (Risser 0–2) vs patients with minimal remaining skeletal growth (Risser 3–5). Left hand x-ray images were not uniformly available to assess Sanders stage for this analysis.^{25,26}

Demographic, Radiographic, and Clinical Outcomes

Clinical and radiographic outcomes were collected at the preoperative (PR) visit, first erect (FE), and after YR2. Coronal curves included the instrumented thoracic curvature and noninstrumented compensatory thoracolumbar/lumbar (TL/L) curvature. Sagittal curve behavior was captured by T5-T12 kyphosis. Thoracoplasty was defined as >3 rib resections. Clinically successful correction was quantified by a residual curve $<35^\circ$ at FE and YR2, as defined by Newton et al.¹⁹ Height change between upper and lower instrumented levels (UIV-LIV)⁶ and proportional height gain as a function of body height were calculated. FE% and total YR2% corrections were calculated in relation to PR measurements, whereas follow-up percent correction was calculated between FE and YR2 (Figure 1). Vertebral body

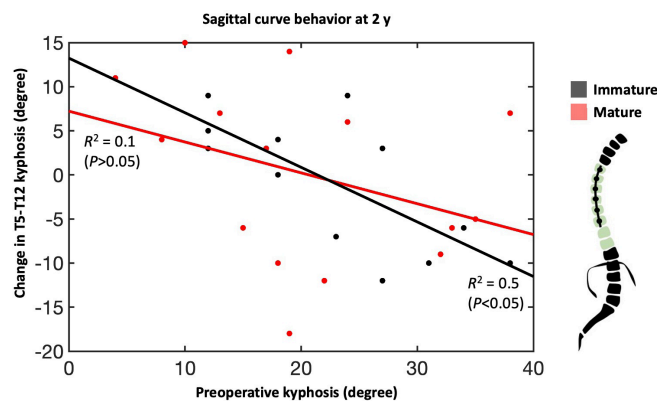


Figure 1. Sagittal curve behavior, characterized as T5-T12 kyphosis, shows an inverse relationship between preoperative kyphosis and the change in curvature over 2 y. This relationship was statistically significant for immature patients whose spines are more amenable to growth modulation from anterolateral compression.

wedging was measured as the angle of the apical vertebra's cephalad and caudad endplate margin on coronal x-ray images comparing FE with YR2, where the difference quantified vertebral body squaring (VBSQ) with more positive values indicating greater squaring.

Complications

All-cause complications were assessed. Overcorrection was defined as a negative YR2 angle and loss of correction as a curve increases $>5^\circ$ between FE and YR2. Screw plowing was defined as the transverse translation of the screw, whereas screw loosening occurred postoperatively.

Surgical Technique

Instrumentation in this series was designed for adult lumbar spinal fusion and used “off label” (Dynesism^m, Zimmer Biomet). The patient was positioned in the lateral decubitus position. A minithoracotomy and 1 to 2 posterior axillary line portals were made for screw placement and an anterior axillary line portal for scope placement. Thoracoplasty of 3 to 5 ribs for rib prominence was offered if inclinometer measurements were $\geq 15^\circ$. Anterior staples were placed anterior to the rib head at each level, followed by bicortical screw placement, and the tether was then seated in the proximal screw. Under fluoroscopic guidance, sequential compression across each level was applied using a tensioner, and set screws were locked into position. We aimed for residual on-the-table curvature of 15° to 20° for IM patients and maximal correction for M patients. Although, we used similar surgical corrective maneuvers between the IM and M groups, we used a combination of manual force through the vertebral body screws and tensioning to remove slack from the tether

maximally in the M group. Double cords with 2 rows of screws were instrumented in patients expected to have less bone remodeling and the need for a more robust composite to withstand forces of activities of daily living, while providing durability of the construct to permit potential bone remodeling.

Statistical Methods

Nonparametric analyses were used due to non-normal data distributions. Categorical and continuous variables were compared between groups using χ^2 test or Mann-Whitney *U* test, respectively. Within-group comparisons were compared across timepoints using a Mann-Whitney *U* test with Bonferroni correction ($P < 0.05$). Data are presented as *n* (%) or median (range).

RESULTS

A total of 89 patients were treated with AVBT and 35 (39%) underwent only instrumentation of their main thoracic curvature. There were 16 skeletally IM and 19 skeletally M patients. Average final follow-up time was 25.2 \pm 3.5 (24–39) months.

Demographic and Skeletal Maturity Measurements

Demographic characteristics were not significantly different between groups (Table 1). Curve distributions

were 83% ($n = 29$) Lenke 1, 14% ($n = 5$) Lenke 2, and 3% ($n = 1$) Lenke 3. The age of the IM and M cohorts was 13 (9–16) vs 15 (12–18) years, respectively. At YR2, the skeletal maturity was 4 (1–5) vs 5 (4–5) (Table 2). In the M group, only 3 patients were Risser 4, and the remainder were Risser 5.

Perioperative Measurements

There was no difference in pre- and postoperative characteristics between groups (Table 1). One cord was instrumented in 16 patients in both groups, whereas 2 cords were used 3 times in the M group ($P = 0.09$).

Coronal and Sagittal Radiographic Outcomes

Median PR and FE major curve were similar between groups, both decreasing from 51° (36°–69°) and 49° (40°–69°) to 23.5° (4°–36°) and 29° (13°–46°) in the IM and M group, respectively (Table 2, Figure 2). The YR2 major curve was 15° (16°–38°) vs 29° (12°–42°) ($P = 0.008$). There was no difference in FE% correction; however, the M group achieved significantly greater YR2% correction (69% vs 53% [$P = 0.008$]) (Figure 3). Follow-up percent correction was zero for M and 15% for IM patients ($P = 0.09$). Major curves corrected significantly when compared with PR in both cohorts; however, only the IM group corrected further between FE and YR2 (Figure 2). TL/L compensatory

Table 1. Demographics and perioperative results.

Variable	Skeletally Immature (Risser 0 to 2)	Skeletally Mature (Risser 3 to 5)	<i>P</i> Value
Descriptives			
Number of patients	16	19	
Follow-up, mo, median (range)	24 (24–39)	25 (24–32)	0.47
Female sex, <i>n</i> (%)	12 (75%)	6 (32%)	0.01
Age, y, median (range)	12.5 (9–16)	15 (12–18)	<0.001
Height, cm, median (range)	156 (138–177)	169 (159–180)	<0.001
Lenke classification 1 2 3	15 1 0	14 4 1	
Preoperative Radiographic			
Major Cobb, degree, median (range)	51 (36–69)	49 (40–69)	0.77
Developmental Stage			
Risser, median (range)	1.5 (0–2)	4 (3–5)	<0.001
Risser 0 1 2 3 4 5	6 1 2 8 0 10 10	0 10 0 16 12 11	
PHOS, median (range)	2.5 (1–3)	4 (2–5)	0.02
PHOS 1 2 3 4 5	2 6 8 0 10	0 11 7 6 5	
Triradiate cartilage closed, <i>n</i> (%)	11 (69%)	19 (100%)	0.49
Operative Data			
Levels tethered, median (range)	8 (6–9)	8 (6–9)	0.36
Upper instrumented level, most frequent level, <i>n</i> (%)	T5, 9 (56%)	T5, 9 (47%)	0.79
Lower instrumented level, most frequent level, <i>n</i> (%)	T12, 9 (56%)	T12, 8 (42%)	0.19
Cords used, 1 cord 2 cords, <i>n</i> (%)	16 (100%) 0 (6%)	16 (84%) 3 (16%)	0.09
Thoracoplasty, <i>n</i> (%)	1 (6%)	2 (11%)	0.65
Estimated blood loss/estimated blood volume, %, median (range)	3.4 (0.8–7.1)	2.4 (0.9–12.4)	0.56
Operative time, h, median (range)	150 (105–210)	165 (105–240)	0.16
Length of stay, d, median (range)	5 (4–7)	5 (3–8)	0.29

Abbreviation: PHOS, proximal humerus ossification system.

Table 2. Preoperative and follow-up radiographic curve behavior of instrumented major curve, noninstrumented compensatory curve, and T5-T12 kyphosis.

Variable	Skeletally Immature (Risser 0 to 2)	Skeletally Mature (Risser 3 to 5)	P Value
Skeletal maturity at final follow-up			
Risser, median (range)	4 (1–5)	5 (4–5)	<0.001
Risser 0 1 2 3 4 5	0 1 1 1 2 1 1 1 1	0 1 0 1 0 3 1 1 4	
PHOS, median (range)	4 (2–5)	5 (4–5)	0.007
PHOS 1 2 3 4 5	0 1 1 1 1 8 1 3	0 1 0 1 0 1 1 1 1	
Instrumented major Cobb, degree, median (range)			
Preoperative	51 (36–69)	49 (40–69)	0.77
First erect	23.5 (4–36) ^a	29 (13–46) ^a	0.27
2-y follow-up	15 (–16 to 38) ^{a,b}	29 (12–42) ^a	0.008
Percent correction, % degree, median (range)			
First erect	55.5 (31–92)	44 (33–73)	0.37
Total	69 (28–132)	53 (13–76)	0.008
Follow-up	15 (–75 to 500)	0 (–61 to 30)	0.09
Successful correction (residual curve degree <35), n (%)			
First erect	16 (100%)	15 (79%)	0.21
Final follow-up	15 (94%)	15 (79%)	0.58
Noninstrumented thoracolumbar/lumbar curve, degree, median (range)			
Preoperative	32.5 (17–52)	31.5 (9–47)	0.77
First erect	13 (–6 to 29) ^a	13 (3–33) ^a	0.72
2-y follow-up	13.5 (–17 to 27) ^a	15 (0–31) ^a	0.77
Percent correction, % degree, median (range)			
First erect	42.5 (8–119)	57.5 (–22 to 83)	0.18
Total	51 (–14 to 153)	55.5 (–33 to 100)	0.85
Follow-up	4 (–183 to 214)	0 (–300 to 100)	0.64
T5-T12 kyphosis, degree, median (range)			
Preoperative	23.5 (12–38)	19 (4–38)	0.51
First erect	21.5 (10–37)	17 (4–35)	0.10
2-y follow-up	23.5 (15–41)	20 (1–45)	0.14
Change in T5-T12 kyphosis, degree, median (range)			
First erect	–5 (–12 to 9)	–5 (–13 to 16)	0.82
Total	1.5 (–12 to 9)	3 (–18 to 15)	0.61
Follow-up	4 (–7 to 10)	2.5 (–20 to 19)	0.94

Abbreviation: PHOS, proximal humerus ossification system.

^aWithin-group difference compared with preoperative, Bonferroni-corrected $P < 0.05$.

^bWithin-group difference compared with first erect, Bonferroni-corrected $P < 0.05$.

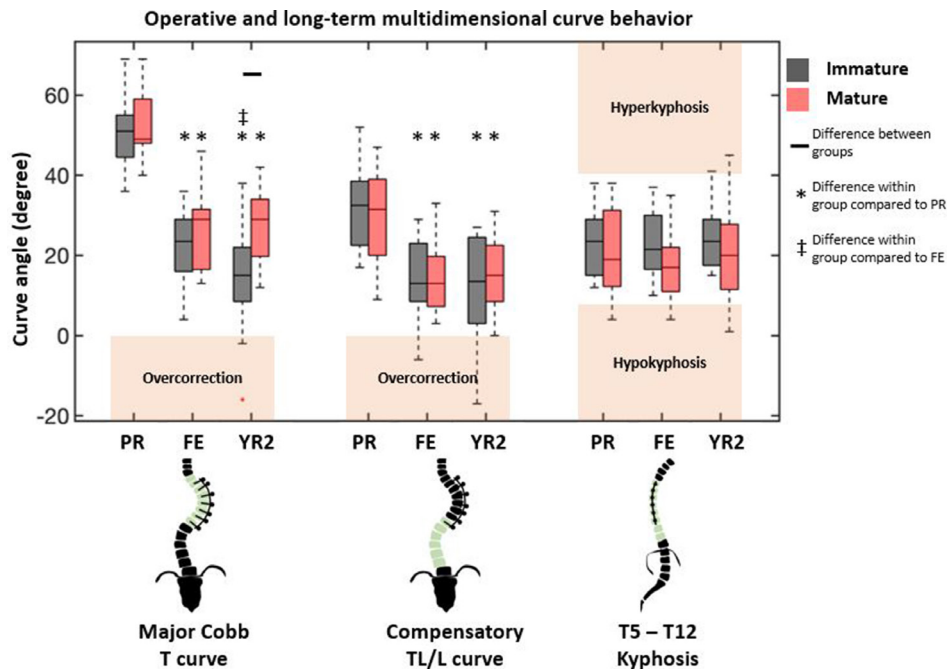


Figure 2. Coronal and sagittal radiographic measurements at 3 timepoints show differences due to skeletal maturity only at 2-y follow-up in the instrumented thoracic curve. Differences between groups are designated by black bar. Differences within a group with reference to preoperative and first erect values are denoted by asterisk (*) and cross (‡), respectively. Boxplot interquartile range shows 25% to 75% with black bar indicating median. Outliers are designated by red plus sign (1.5 times interquartile range). Between- and within-group comparisons were done using a Mann-Whitney U test with Bonferroni correction ($P < 0.05$). PR, preoperative; FE, first erect; YR2, 2 y; T, thoracic; TL/L, thoracolumbar/lumbar.

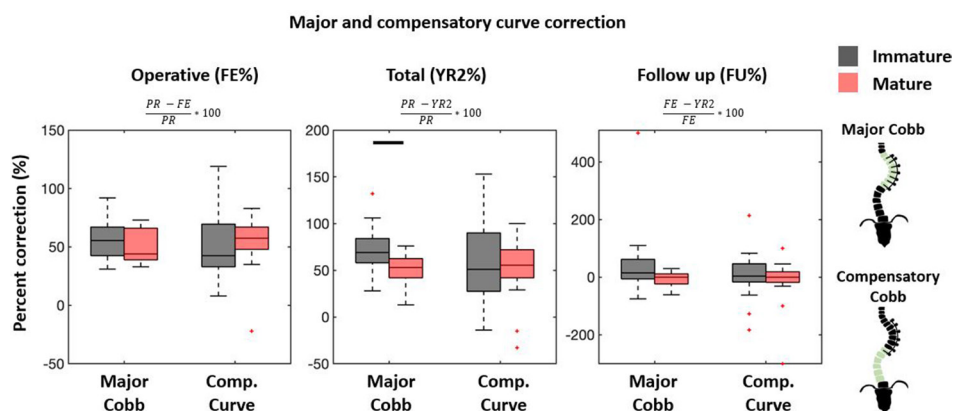


Figure 3. Major and compensatory curve first erect and total percent correction (FE% and YR2%) are referenced to preoperative (PR) curve, whereas follow-up percent correction (FU%) compares FE with YR2. Percent correction beyond 100% defines overcorrection, and negative values define loss of correction. Large variations seen in FU% occurs with near-zero FE curves. Boxplots follow formatting described in Figure 2. Between-group comparisons were done using a Mann-Whitney *U* test with Bonferroni correction ($P < 0.05$).

curve measurements were similar between groups at all timepoints (Figures 2 and 3). When data were pooled, there was no difference in T5-T12 kyphosis between groups and within groups at any timepoint (Figure 2). However, subsequent patient-specific analysis showed patients with kyphosis below the mean tended to have an increase in kyphosis and those with kyphosis above the mean tended to have a decrease in their kyphosis (Figure 1) Two (100%) PR hypokyphotic patients became normokyphotic at YR2 and 27 (90%) normokyphotic patients remained normokyphotic. There was a difference in UIV-LIV height at PR and FE, but this difference was not seen at YR2 (Table 3, Figure 4A). UIV-LIV height gain was larger ($P < 0.001$) for IM patients after YR2; however, groups were similar when normalizing by total body height (Figure 4B). The degree of apical vertebral body wedging was not different at FE but was smaller in the IM group at YR2 ($P = 0.02$),

which leads to greater VBSQ of 6° vs 1° ($P < 0.001$) (Table 3, Figure 5).

Clinical and Patient-Reported Outcomes

Successful major curve correction at YR2 was achieved in 15/16 (94%) and 15/19 (79%) IM and M patients, respectively (Table 2, Figure 6). Of the 5 unsuccessful cases, 2 had successful FE correction and 1 lost correction due to suspected breakage. Only in a Risser 4 patient with a 69° PR curve did the major curve never correct $<35^\circ$. There was no difference in cord survival and number of suspected cord breakages (Table 4). Breakages occurred at 24, 39, 12, and 43 months, yielding curvature changes of (IM: $+8^\circ$, -2° ; M: $+8^\circ$, $+11^\circ$) and only 1 per patient. There were 2 (13%) overcorrections in the IM and 0 in the M and no significant difference

Table 3. Preoperative and follow-up body height, instrumented segment vertical height measurements, and apical vertebral body squaring.

Variable	Skeletally Immature (Risser 0 to 2)	Skeletally Mature (Risser 3 to 5)	<i>P</i> Value
Body height, cm, median (range)			
Preoperative	156 (138–177)	169 (159–180)	<0.001
2-y follow-up	162 (153–178)	175 (162–184)	0.04
Height gain	8 (2–15)	3.5 (0–15)	0.04
Upper and lower instrumented levels vertical height, cm, median (range)			
Preoperative	15 (13–20)	20 (14–25)	<0.001
First erect	18 (13–20) ^a	21 (15–26)	<0.001
2-y follow-up	19.5 (14–24) ^{a,b}	22 (16–26)	0.12
First erect gain	1.5 (0–4)	1 (0–3)	0.15
Total gain	3.5 (1–8)	1.5 (0–4)	<0.001
Proportional height gain, %	41.5 (20–71)	33 (0–67)	0.15
Apical vertebral body squaring, degree, median (range)			
First erect wedge	9 (7–15)	8 (5–13)	0.13
2-y follow-up wedge	3 (0–12) ^a	6 (2–12) ^a	0.02
Follow-up squaring	6 (3–8)	1 (0–6)	<0.001

^aWithin-group difference compared with preoperative, Bonferroni-corrected $P < 0.05$.

^bWithin-group difference compared with first erect, Bonferroni-corrected $P < 0.05$.

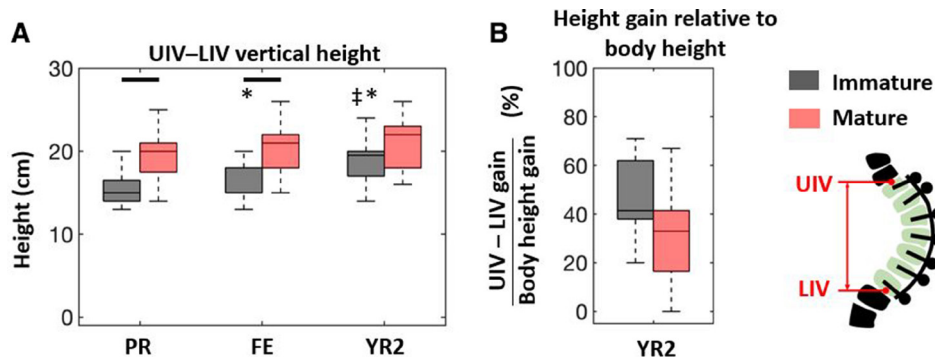


Figure 4. (A) Vertical height changes of the instrumented segment show significant differences between groups at preoperative (PR) and first erect (FE) that disappear at 2 y (YR2). (B) The immature group had greater height gain at YR2, but this difference disappeared when normalizing by total body height gain. Between- and within-group comparisons were done using a Mann-Whitney *U* test with Bonferroni correction ($P < 0.05$). UIV-LIV, upper and lower instrumented levels.

in loss of correction. Figure 7 illustrates a case of overcorrection. There was 1 case of screw plowing with angulation $>10^\circ$, which occurred during operative tensioning of the tether from inertial insertion, but no screw loosening, readmissions, or revisions. There were no significant differences in Scoliosis Research Society-22 outcomes between maturity groups with scores ranging between 3 and 5 for all subsections (Table 4).

DISCUSSION

This study compared the effect of PR skeletal maturity on ≥ 2 -year postoperative clinical and radiographic outcomes following thoracic AVBT. Prior literature captures outcomes in IM cohorts^{8,9,19,23} and only a few report subgroups of slightly more M patients.^{5,6} To date, there is a singular case series of AVBT in skeletally M patients, but the study reports on a small sample size (N

= 10) with less than YR2 follow-up.²⁷ We report on the largest series of patients with limited remaining skeletal growth at the time of surgery and minimum YR2 follow-up.

In our IM cohort (12.5 ± 1.7 years), we observed comparable successful major thoracic curve correction in 94% of patients at YR2, with 2 overcorrections, an 8° correction loss in 1 patient, and no revisions. Samdani et al²⁰ published on 11 IM patients (Risser 0.6 ± 1.1), reporting clinical success ($<25^\circ$) in all but 1 and 9% to 18% overcorrection. Newton et al¹⁹ reported on 17 IM patients (Risser 0, 94% open triradiate cartilage), reporting 59% clinical success, 23% overcorrection, and 4 patients requiring revision surgery due to overcorrection. Miyanji et al⁹ published on 55 IM patients (Risser 0.5 ± 0.9) showing clinical success in 77%, counting 1 (2%) overcorrection, and 5 (8%) insufficient correction, all of which required conversion to PSF. Alanay et al⁶

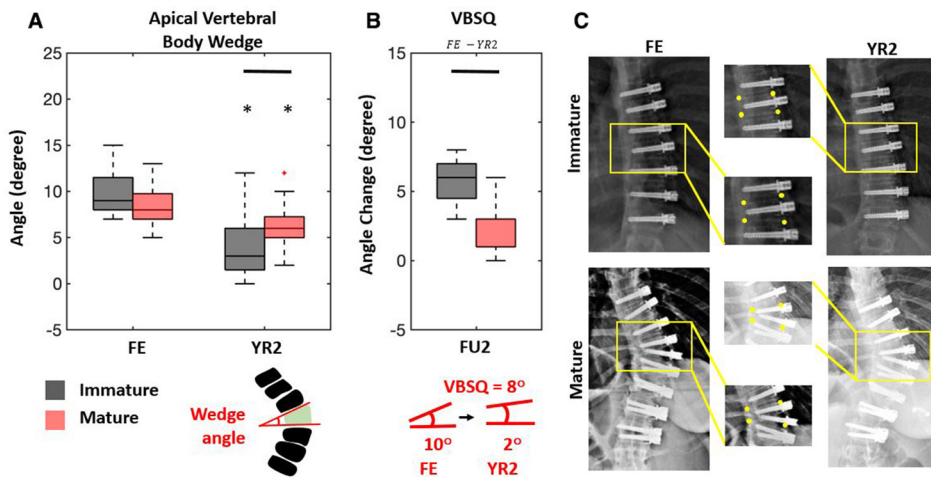


Figure 5. (A) The degree of apical vertebral body wedging was assessed at first erect (FE) and compared with the 2-y (YR2) wedge. (B) Vertebral body squaring (VBSQ) quantifies the difference in wedging from FE to YR2, where more positive values indicate greater squaring. Immature patients showed significantly more squaring. (C) Representative immature and mature patients highlight changes in wedging. Between-group comparisons were done using a Mann-Whitney *U* test with Bonferroni correction ($P < 0.05$).

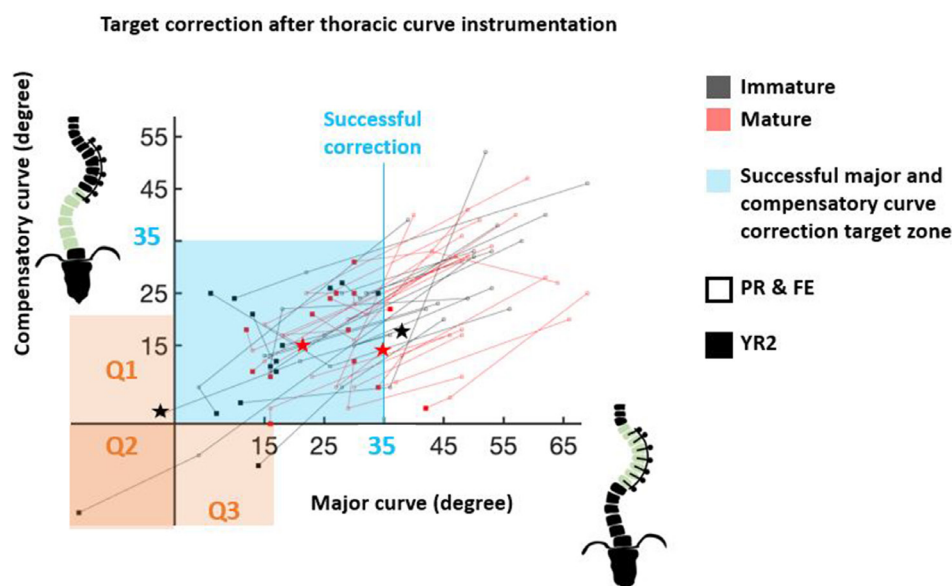


Figure 6. Correction of major thoracic (instrumented) and compensatory thoracolumbar/lumbar (noninstrumented) curves toward target region (light blue, $<35^\circ$) is captured from preoperative (PR) (unfilled) and first erect (FE) (unfilled) to 2-y (YR2) follow-up (filled). Overcorrection of major (Q1), compensatory (Q3), or both curves (Q2) is highlighted in orange. Suspected breakage is indicated by star.

reported on 21 patients spanning the skeletal maturity spectrum, reporting 19% overcorrection (all occurring in Sanders ≤ 3). Hoernschemeyer et al⁵ published on 29 patients (48% Risser ≤ 1) reporting success ($<30^\circ$) in 20 (75%) patients. The revision rate was 21%, of whom 2 patients converted to PSF due to curve progression.

Our M cohort contained 19 patients (15.4 ± 1.8 years), of whom 15 (79%) were clinically successful at YR2 with 53% correction, a curve progression in 4 (23%), and no overcorrections or revision operations. A small cohort reported by Alanay et al⁶ was aged 13 ± 1.0 (Sanders 6–7, Risser 4) with 100% success

rate (residual curve 9° – 27°) at final follow-up (12–29 months) and 55% correction. Hoernschemeyer et al⁵ report successful correction at last follow-up in 2 (66%) skeletally M patients (Sanders 6–7). Studies of PSF in skeletally M AIS patients with thoracic major curves have shown slightly higher corrections between $65\% \pm 11\%$ ²⁸ and $73\% \pm 12\%$.²⁹ This difference may be acceptable for patients with minimal remaining skeletal growth seeking to avoid fusion. Similar patient-reported outcomes between our skeletal maturity groups support the notion that skeletally M patients appear satisfied with the surgical outcome at YR2 removed from

Table 4. Complications and patient-reported outcomes.

Variable	Skeletally Immature (Risser 0 to 2)	Skeletally Mature (Risser 3 to 5)	P Value
Revisions, n (%)	0 (0%)	0 (0%)	
Screw plowing, n (%)	1 (6%)	0 (0%)	0.27
Screw loosening, n (%)	0 (%)	0 (%)	
Cord breakage			
Number of breakages, n (%)	2 (13%)	2 (12%)	0.94
Survival time of breakages, mo, events	(24, 39)	(12, 42)	
Survival time all, mo, median (range)	24 (24–39)	25 (12–42)	0.32
Correction complications			
Overcorrection, n (%)	2 (13%)	0 (0%)	0.13
Overcorrection degree, median (range)	9 (2–16)	0	
Loss of correction, n (%)	1 (6%)	4 (23%)	0.17
Loss of correction degree, median (range)	8 (8)	7.5 (6–11)	0.12
2-y follow-up Scoliosis Research Society Questionnaire Scores, median (range)			
Activity	4.1 (3.6–4.4)	4.4 (3–5)	0.24
Pain	4.5 (3.7–5)	4.7 (3.3–5)	0.26
Image	4.3 (3.4–4.9)	4.4 (3.1–5)	0.44
Mental	4.4 (3.2–5)	4.7 (3.4–5)	0.46
Satisfaction	4.5 (3–5)	4.7 (3–5)	0.57
Average	4.3 (3.6–4.8)	4.5 (3.3–5)	0.30

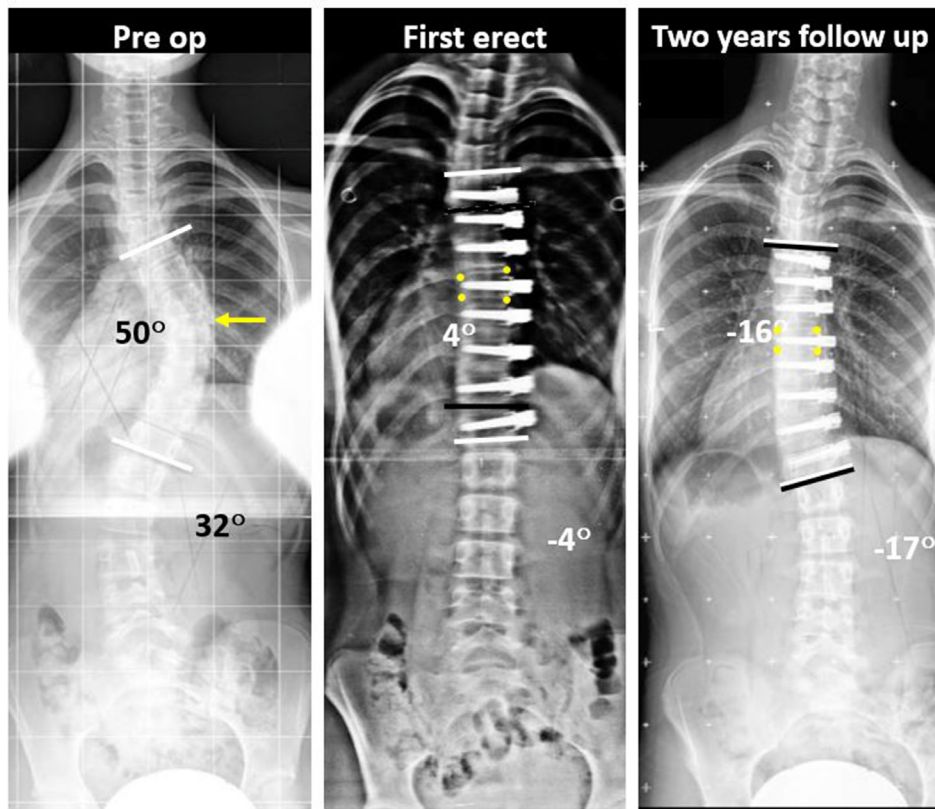


Figure 7. Preoperative posteroanterior scoliosis radiograph of an immature group patient (Risser 2, proximal humerus ossification system 1 [PHOS 1]) with a 50° thoracic curve and 32° thoracolumbar curve. First erect (FE) radiograph shows correction of major and compensatory curves. FE% correction was 92%. The patient was Risser 4 (PHOS 5) at 24 mo, and posteroanterior radiograph shows major curve overcorrection (2-y percent correction [YR2%] = 132%), corresponding to a 500% follow-up percent change (from FE to YR2). Apical wedge angle was 8° at FE and 0° at YR2, generating a vertebral body squaring of 8°. Follow-up angles were measured between vertebra contained by the black bars, where white bars indicate preoperative angles. Yellow arrow indicates the apical vertebra, and yellow dots mark the vertebral body margins.

surgery. An important future consideration is whether these radiographic outcomes will be durable beyond YR2 when compared with PSF.

Both our IM and M cohorts saw reductions in their major thoracic curves concordant with previously reported literature (51°–23.5° vs 49°–29°), reflecting minimal influence of PR skeletal maturity on surgical curve correction.^{5,6,9,19,20} Like prior studies that stratified by maturity, we also found greater residual curves in M patients, due to continued correction in the IM group and not widespread loss of correction. M patients maintained correction with no difference in clinically successful correction after YR2 between groups. Overcorrection was only observed in IM patients, which agrees with the literature,^{9,19,20,22} and confirms prior conclusions that less skeletally M patients (Sanders 1 and 2) are prone to overcorrection.^{6,23} Optimal timing and tensioning of the cord at each spinal segment need to be studied further to minimize overcorrection. Our cohort of IM patients may be more skeletally M than others reported in the literature, which could account for our relatively low rates of overcorrection and revision

surgery. Given these findings, we agree with others^{23,26} who concluded that tethering patients slightly after their growth acceleration phase²⁶ may lead to more predictable successful outcomes, where much of the correction occurs intraoperatively.

Our compensatory TL/L curves corrected independent of skeletal maturity and by similar magnitudes as with PSF.^{5,9,20} We observed overcorrection of the uninstrumented TL/L compensatory curves in 2 Risser 2 patients, which has also previously reported.⁵ Normal kyphosis was maintained for the majority of patients regardless of skeletal maturity, which is congruent with prior literature.^{6,19,20} We also found that kyphosis below the mean for the cohorts increased at follow-up, whereas kyphosis above the mean decreased at follow-up as was desired. It is unclear to the surgeon what specific intraoperative maneuvers might account for those differences.

We report no difference in tether breakage with 2 suspected broken tethers per group. In 1 IM patient, cord breakage occurred at 39 months, coinciding with overcorrection by 2°. Cord breakage

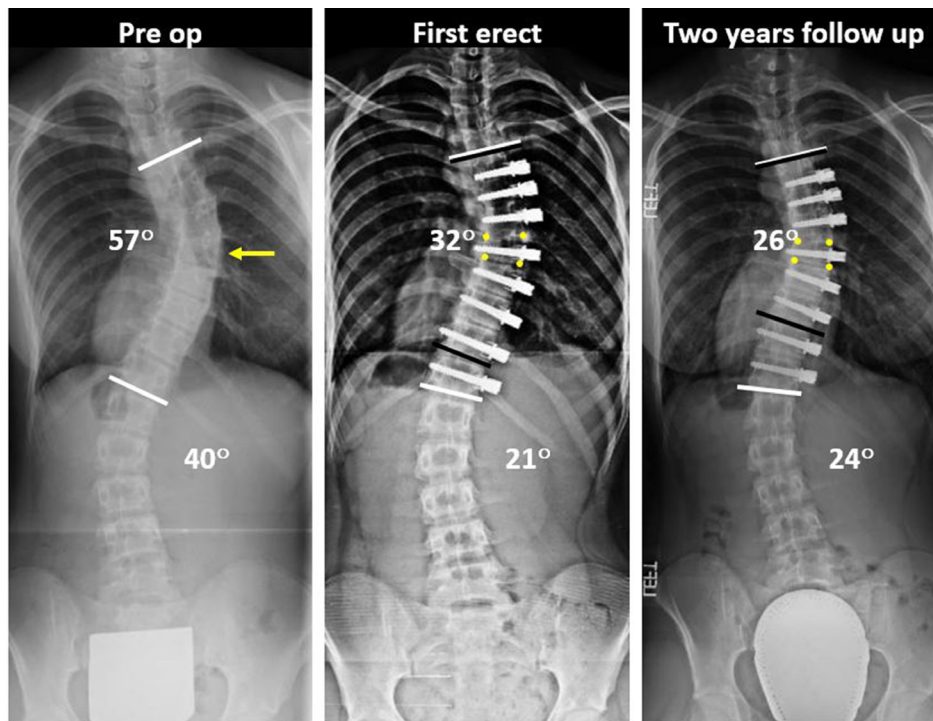


Figure 8. Preoperative posteroanterior scoliosis radiograph of a mature group patient (Risser 4, proximal humerus ossification system 4 [PHOS 4]) with a 57° thoracic curve and 40° lumbar curve. First erect radiograph shows correction of major and compensatory curves. At 24 mo, the patient was Risser 5 (PHOS 5), and posteroanterior radiograph shows maintenance of clinically successful correction. Apical wedge angle was 12° at first erect and 8° at 2-y follow-up, calculating a VBSQ of 4°. Follow-up Cobb angles were measured between vertebra contained by the black bars, where white bars indicate preoperative angles. The yellow arrow indicates the apical vertebra, and yellow dots mark the vertebral body margins.

can be fortuitous if in an overcorrected segment might otherwise require a revision,¹⁹ which was not needed in our series. The M cohort only experienced 2 single cord breakages. We anticipate that tethers will fail in the future with higher incidence of failure in the more mobile sections of the spine. Longer-term follow-up is required to determine the impact of tether breakage on maintenance of correction. We now use a double cord for at least part of the construct to mitigate against cord breakage and loss of correction. Intraoperative translational and derotational maneuvers may also help achieve correction without overstressing and potentially damaging the tether.⁶

We found VBSQ of the curve apical vertebra was significantly increased in IM patients. We attribute this to enhanced bone remodeling of the vertebral body concave wall during the growth acceleration phase according to the Heuter-Volkman law.^{2,10} One postmenarchal Risser 4 woman squared the apical wedge by 4° (Figure 8). While remaining growth could have accounted for this, bone remodeling by Wolff law may also contribute to an M patient's vertebral remodeling. The unchanged UIV-LIV vertical height at YR2 in the M group suggests that the integrity of the tether-spinal column construct remains intact, perhaps through

shared loading of a partially corrected spine, assisted by the tether.

Limitations include our choice of skeletal maturity staging system. Sanders stage is most commonly reported in AVBT studies, but it requires additional hand radiographs, which were unavailable for all of our patients.²⁵ Inaccuracies in Risser staging mostly exist between grades 3, 4, and 5²⁸; however, these patients were grouped as skeletally M in our study, lending confidence to our stratification. Furthermore, PHOS distributes excellently across the growth acceleration phase, and Risser stages were therefore confirmed with PHOS, thus permitting us to isolate a cohort of patients who had minimal remaining skeletal growth, which we defined as M.^{26,30,31} Last, VBSQ may be subject to inaccurate measurements secondary to spinal rotation. We therefore quantified VBSQ between FE and YR2 follow-up, as opposed to PR, thus bypassing the effect of operative curve derotation. These measurements are relatively small and may be subject to measurement variability.

CONCLUSION

AVBT is principally indicated for skeletally IM patients with primary thoracic curves between 35° and 60°. Nevertheless, the perception of achieving

correction while avoiding PSF makes this technology appealing. Although, tethering more M patients is not widely accepted, our results reflect that these patients have satisfactory operative correction and appear to maintain correction at YR2. These patients may also benefit from low overcorrection risk without added mechanical complication rates. Further study relating to long-term outcomes and investigations into whether tissue remodeling occurs is warranted.

REFERENCES

- Mente PL, Stokes IA, Spence H, Aronsson DD. Progression of vertebral wedging in an asymmetrically loaded rat tail model. *Spine (Phila Pa 1976)*. 1997;22(12):1292–1296. doi:10.1097/00007632-199706150-00003
- Stokes IA, Spence H, Aronsson DD, Kilmer N. Mechanical modulation of vertebral body growth. Implications for scoliosis progression. *Spine (Phila Pa 1976)*. 1996;21(10):1162–1167. doi:10.1097/00007632-199605150-00007
- Weinstein SL, Dolan LA, Cheng JCY, Danielsson A, Morcuende JA. Adolescent idiopathic scoliosis. *Lancet*. 2008;371(9623):1527–1537. doi:10.1016/S0140-6736(08)60658-3
- Danielsson AJ, Romberg K, Nachemson AL. Spinal range of motion, muscle endurance, and back pain and function at least 20 years after fusion or brace treatment for adolescent idiopathic scoliosis: a case-control study. *Spine (Phila Pa 1976)*. 2006;31(3):275–283. doi:10.1097/01.brs.0000197652.52890.71
- Hoernschemeyer DG, Boeyer ME, Robertson ME, et al. Anterior vertebral body tethering for adolescent scoliosis with growth remaining: a retrospective review of 2 to 5-year postoperative results. *J Bone Joint Surg Am*. 2020;102(13):1169–1176. doi:10.2106/JBJS.19.00980
- Alanay A, Yucekul A, Abul K, et al. Thoracoscopic vertebral body tethering for adolescent idiopathic scoliosis: follow-up curve behavior according to sanders skeletal maturity staging. *Spine (Phila Pa 1976)*. 2020;45(22):E1483–E1492. doi:10.1097/BRS.0000000000003643
- Crawford CH, Lenke LG. Growth modulation by means of anterior tethering resulting in progressive correction of juvenile idiopathic scoliosis: a case report. *J Bone Joint Surg Am*. 2010;92(1):202–209. doi:10.2106/JBJS.H.01728
- Newton PO, Bartley CE, Bastrom TP, Kluck DG, Saito W, Yaszay B. Anterior spinal growth modulation in skeletally immature patients with idiopathic scoliosis: a comparison with posterior spinal fusion at 2 to 5 years postoperatively. *J Bone Jt Surg*. 2020;102(9):769–777. doi:10.2106/jbjs.19.01176
- Miyanji F, Pawelek J, Nasto LA, Rushton P, Simmonds A, Parent S. Safety and efficacy of anterior vertebral body tethering in the treatment of idiopathic scoliosis. *Bone Joint J*. 2020;102-B(12):1703–1708. doi:10.1302/0301-620X.102B12.BJJ-2020-0426.R1
- Mehlman CT, Araghi A, Roy DR. Hyphenated history: the hueter-volkman law. *Am J Orthop (Belle Mead NJ)*. 1997;26(11):798–800.
- Stokes IAF, Aronsson DD, Spence H, Iatridis JC. Mechanical modulation of intervertebral disc thickness in growing rat tails. *J Spinal Disord*. 1998;11(3):261–265. doi:10.1097/00002517-199806000-00015
- Newton PO, Farnsworth CL, Upasani VV, Chambers RC, Varley E, Tsutsui S. Effects of intraoperative tensioning of an anterolateral spinal tether on spinal growth modulation in a porcine model. *Spine*. 2011;36(2):109–117. doi:10.1097/BRS.0b013e3181cc8fce
- Newton PO, Farnsworth CL, Faro FD, et al. Spinal growth modulation with an anterolateral flexible tether in an immature bovine model: disc health and motion preservation. *Spine (Phila Pa 1976)*. 2008;33(7):724–733. doi:10.1097/BRS.0b013e31816950a0
- Braun JT, Hoffman M, Akyuz E, Ogilvie JW, Brodke DS, Bachus KN. Mechanical modulation of vertebral growth in the fusionless treatment of progressive scoliosis in an experimental model. *Spine (Phila Pa 1976)*. 2006;31(12):1314–1320. doi:10.1097/01.brs.0000218662.78165.b1
- Aubin C-É, Clin J, Rawlinson J. Biomechanical simulations of costo-vertebral and anterior vertebral body tethers for the fusionless treatment of pediatric scoliosis. *J Orthop Res*. 2018;36(1):254–264. doi:10.1002/jor.23648
- Cobetto N, Aubin CE, Parent S. Surgical planning and follow-up of anterior vertebral body growth modulation in pediatric idiopathic scoliosis using a patient-specific finite element model integrating growth modulation. *Spine Deform*. 2018;6(4):344–350. doi:10.1016/j.jspd.2017.11.006
- Driscoll M, Aubin CE, Moreau A, Parent S. Biomechanical comparison of fusionless growth modulation corrective techniques in pediatric scoliosis. *Med Biol Eng Comput*. 2011;49(12):1437–1445. doi:10.1007/s11517-011-0801-8
- Driscoll M, Aubin C-E, Moreau A, Parent S. Finite element comparison of different growth sparing instrumentation systems for the early treatment of idiopathic scoliosis. *Stud Health Technol Inform*. 2010;158:89–94. doi:10.3233/978-1-60750-573-0-89
- Newton PO, Kluck DG, Saito W, Yaszay B, Bartley CE, Bastrom TP. Anterior spinal growth tethering for skeletally immature patients with scoliosis: a retrospective look two to four years postoperatively. *J Bone Joint Surg Am*. 2018;100(19):1691–1697. doi:10.2106/JBJS.18.00287
- Samdani AF, Ames RJ, Kimball JS, et al. Anterior vertebral body tethering for idiopathic scoliosis: two-year results. *Spine (Phila Pa 1976)*. 2014;39(20):1688–1693. doi:10.1097/BRS.0000000000000472
- Samdani AF, Ames RJ, Kimball JS, et al. Anterior vertebral body tethering for immature adolescent idiopathic scoliosis: one-year results on the first 32 patients. *Eur Spine J*. 2015;24(7):1533–1539. doi:10.1007/s00586-014-3706-z
- Baker CE, Kiebzak GM, Neal KM. Anterior vertebral body tethering shows mixed results at 2-year follow-up. *Spine Deform*. 2021;9(2):481–489. doi:10.1007/s43390-020-00226-x
- Senkoylu A, Riise RB, Acaroglu E, Helenius I. Diverse approaches to scoliosis in young children. *EFORT Open Rev*. 2020;5(10):753–762. doi:10.1302/2058-5241.5.190087
- Krakow AR, Magee LC, Cahill PJ, Flynn JM. Could have tethered: predicting the proportion of scoliosis patients most appropriate for thoracic anterior spinal tethering. *Spine Deform*. 2021;9(4):1005–1012. doi:10.1007/s43390-021-00296-5
- Sanders JO, Khoury JG, Kishan S, et al. Predicting scoliosis progression from skeletal maturity: a simplified classification during adolescence. *J Bone Joint Surg Am*. 2008;90(3):540–553. doi:10.2106/JBJS.G.00004
- Li DT, Cui JJ, DeVries S, et al. Humeral head ossification predicts peak height velocity timing and percentage of growth remaining in children. *J Pediatr Orthop*. 2018;38(9):e546–e550. doi:10.1097/BPO.0000000000001232

27. Hegde SK, Venkatesan M, Akbari KK, Badikillaya VM. Efficacy of anterior vertebral body tethering in skeletally mature children with adolescent idiopathic scoliosis: a preliminary report. *Int J Spine Surg*. 2021;15(5):995–1003. doi:10.14444/8122

28. Lonner BS, Ren Y, Bess S, et al. Surgery for the adolescent idiopathic scoliosis patients after skeletal maturity: early versus late surgery. *Spine Deform*. 2019;7(1):84–92. doi:10.1016/j.jspd.2018.05.012

29. Vavruch L, Brink RC, Malmqvist M, et al. Surgical outcomes of anterior versus posterior fusion in lenke type 1 adolescent idiopathic scoliosis. *Spine (Phila Pa 1976)*. 2019;44(14):E823–E832. doi:10.1097/BRS.0000000000002984

30. Li DT, Linderman GC, Cui JJ, et al. The proximal humeral ossification system improves assessment of maturity in patients with scoliosis. *J Bone Joint Surg Am*. 2019;101(20):1868–1874. doi:10.2106/JBJS.19.00296

31. Di Pauli von Treuheim T, Li DT, Mikhail C, et al. Reliable skeletal maturity assessment for an AIS patient cohort: external validation of the proximal humerus ossification system (PHOS) and relevant learning methodology. *Spine Deform*. 2020;8(4):613–620. doi:10.1007/s43390-020-00105-5

Funding: The authors received no financial support for the research, authorship, and/or publication of this article.

Declaration of Conflicting Interests:

Dr Lonner reports personal fees, royalty fees, and research grant support from Zimmer Biomet for The Tether implant. Dr Lonner also reports personal fees, nonfinancial support and other from Depuy Synthes, personal fees and non-financial support

from OrthoPediatrics, other from Paradigm Spine, non-financial support and other from Spine Search, and other from Setting Scoliosis Straight Foundation outside the submitted work.

Patient Consent for Publication: This work was performed under a waiver of informed consent approved by the Institutional Review Board at Mount Sinai Hospital.

Ethics Approval: This work was approved by the Institutional Review Board at Mount Sinai Hospital.

Data Availability Statement: Data will be maintained for this study for up to 7 years after publication as required by our institution's review board.

Corresponding Author: Baron Lonner, Department of Orthopaedic Surgery, Mount Sinai Hospital, 5 E 98th St, 4th Floor, New York, NY 10029, USA; baron.lonner@mountsinai.org

Published 16 September 2022

This manuscript is generously published free of charge by ISASS, the International Society for the Advancement of Spine Surgery. Copyright © 2023 ISASS. To see more or order reprints or permissions, see <http://ijssurgery.com>.