

## Case – An invisible stent

Mohamad Baker Berjaoui<sup>1</sup>, Tiange Li<sup>1</sup>, Keith Lawson<sup>1</sup>, Michael Kogon<sup>2</sup>

<sup>1</sup>Division of Urology, University of Toronto, Toronto, ON, Canada; <sup>2</sup>Division of Urology, Mackenzie Health, Vaughan, ON, Canada

Cite as: Baker Berjaoui M, Li T, Lawson K, et al. Case – An invisible stent. *Can Urol Assoc J* 2023;17(3):E100-2. <http://dx.doi.org/10.5489/cuaj.8024>

Published online October 25, 2022

### INTRODUCTION

A 72-year-old male presented for an annual left-sided ureteral stent change. The stent was entirely invisible on fluoroscopy, but interestingly, was completely intact and functioning normally. After cystoscopic retrieval, ex-vivo fluoroscopy demonstrated that this stent was more radiolucent compared to a brand-new stent. A review of serial computed tomography (CT) imaging demonstrated progressive loss of radio-opacity of the stent over time. We theorize that the stent lost its radiopaque coating due to chronic exposure to urine, suggesting a need for more resilient stent coatings to avoid complications, such as forgotten stent syndrome.

### CASE REPORT

A 72-year-old male with a history of diabetes mellitus and benign prostatic hyperplasia (BPH) who was found to have stage IV non-small-cell lung carcinoma. As part of his treatment for his lung cancer, he received chemotherapy in May of 2020. Subsequently, he presented to the emergency department on June 5, 2020 with fever, tachycardia, elevated white count of 32, and acute renal failure, with a creatinine of 337.

During that presentation, the patient required admission to the intensive care unit for inotropic support, and a CT scan demonstrated a severely thickened bladder wall and large left-sided diverticulum, with left-sided hydronephrosis extending to the left ureterovesical junction. On this basis, urology was consulted and cystoscopic assessment confirmed severe bilobar hypertrophy of the prostate, severe trabeculation, and a large left-sided diverticulum, with the patient failing a trial of void after that. To note, the patient had never seen a urologist before but was performing clean intermittent self-catheterization,

which he learned from a family member with neurogenic bladder.

Considering patient prognosis, goals of care, and after discussing with the patient and medical oncology team, a decision was made to proceed with transurethral resection of prostate (TURP) and insertion of left-sided ureteral stent. The plan was to defer diverticulectomy or ureteral reimplantation and perform annual stent change.

The patient underwent successful Greenlight TURP with left-sided ureteral stent insertion (Cook Black Silicone Filiform Double Pigtail Stent – 6 French). Stent insertion was challenging due to severe tortuosity of the distal ureter, presumably related to the proximity of the ureter to the diverticulum. Stent insertion was ultimately achieved and retrograde pyelography demonstrated the radiopaque, intact ureteric stent, with the proximal and distal curls in their appropriate locations (Figure 1). A year later, at the time of the planned stent exchange, the stent was entirely invisible on fluoroscopy (Figure 2). Interestingly, the stent was easily found on cystoscopy and was successfully retrieved intact, with minimal encrustation or visible degradation. Ex-vivo fluoroscopy demonstrated that this stent was significantly more radiolucent compared to a new, out-of-the-box stent (Figure 3). Finally, a new left-sided stent was inserted over a wire. Fluoroscopic images confirmed that this new stent was radiopaque, with its proximal and distal curls in appropriate positioning (Figure 4).

We reviewed the staging CT scans performed by our colleagues in medical oncology in the interim, between the insertion of the stent and stent change. Interestingly, the stent was seen to be gradually losing its radio-opacity on CT imaging (Figure 5).

### KEY MESSAGES

- In comparing differences in 90-day complications might lose their radiopacity, and thus, thorough clinical history is fundamental.
- More effort should be made to improve the material covering stents to ensure radio-opacity is preserved.

## DISCUSSION

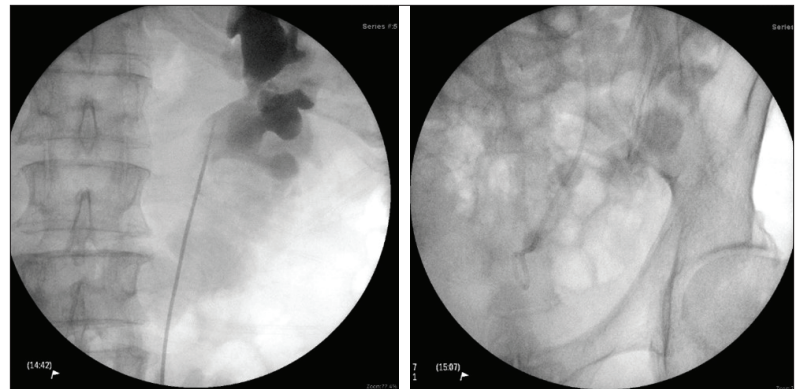
We hereby report a rare case of a ureteric stent that lost its radio-opacity in-situ. Although vanishing stents have been previously described,<sup>1-3</sup> these were in the context of forgotten, long-standing, indwelling stents with significant shaft fragmentation and degradation. The degraded middle fragments were lost, and were therefore not radiologically identified (on plain radiographs and CT), nor were they seen during endoscopic and percutaneous retrieval of remaining fragments. On the other hand, the retained and heavily encrusted proximal and distal segments were clearly radiopaque.

Our patient had an indwelling stent that was invisible on fluoroscopy but was completely intact on endoscopic retrieval and otherwise functioning normally. We find only one comparable case described by Jayadevan and colleagues: a 35-year-old female presented with right flank pain and fever, and was found to have a right double-J ureteric stent that was indwelling for over eight years.<sup>4</sup> This stent was overall intact, fragmented minimally only between the proximal curl and the stent shaft; nevertheless, it was difficult to visualize both on CT and fluoroscopy. It is unknown the exact material and coating composition of this stent; however, the authors theorized that radiopaque materials may have degraded and been lost due to chronic exposure to urine.

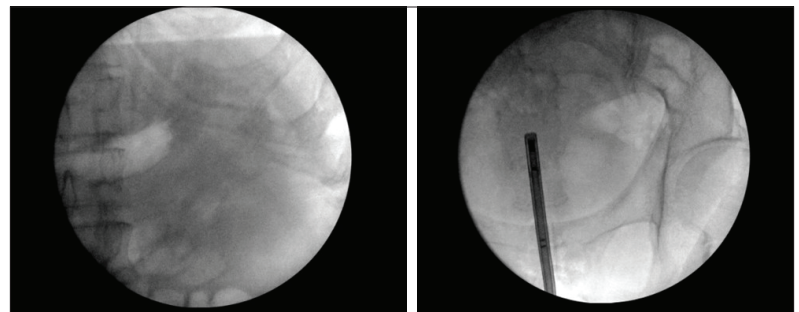
Ureteric stents are widely employed to maintain ureteral patency. Modern innovations in stent materials and coatings<sup>5-7</sup> continue to strive for the “ideal” ureteric stent<sup>7,8</sup> that maximizes biocompatibility<sup>9,10</sup> and ease of use, while minimizing complications, such as biofilm formation and encrustation.<sup>11,12</sup> The modern silicone stent — such as was used for our patient — has a number of advantages, including patient comfort and low risk of encrustation, which makes it a recommended choice over other stent types for many indications.<sup>5</sup> One study examining the effects of chronic exposure to urine on various stent materials demonstrated that after soaking in artificial urine for 14 weeks, silicone stents had the lowest rates of encrustation compared to other stents.<sup>13</sup>

Despite radiopacity being a primary feature of the “ideal” stent,<sup>8</sup> few innovations have targeted the long-term maintenance of stent opacity,<sup>5-7,14</sup> especially in the context of chronic urine exposure. This may be owing to the rarity of this complication, and the general practice of stent changes every few months that minimize opportunities for material degradation.

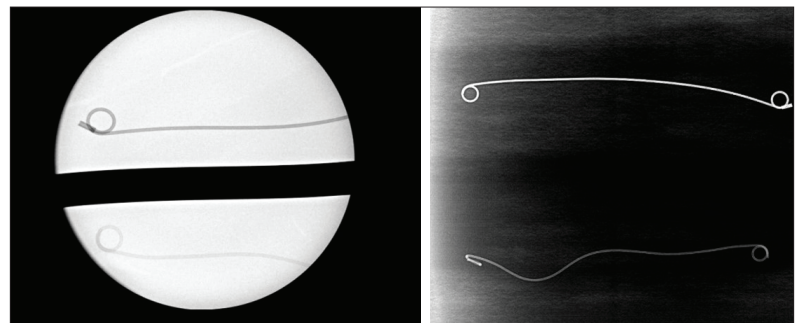
Forgotten ureteric stents is a frequently reported issue that may lead to other complications, including encrustation, stent fragmentation, infection, fistulae,



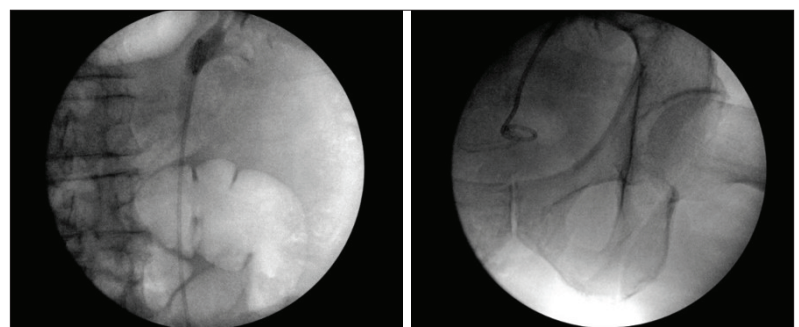
**Figure 1.** Proximal (left) and distal (right) curls of the original double-J ureteric stent at the time of placement.



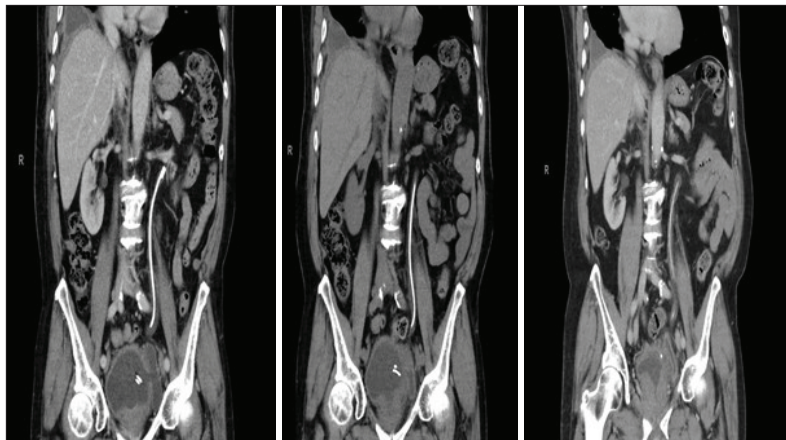
**Figure 2.** Fluoroscopic images prior to stent removal, demonstrating that the stent shaft and proximal/distal curls were not visible radiographically.



**Figure 3.** The original ureteric stent (bottom) has increased radiolucency compared to a new stent (top).



**Figure 4.** Insertion of a new double-J stent, which is easily seen on fluoroscopy, with proximal (left) and distal (right) curls in appropriate positions.



**Figure 5.** Staging computed tomography scans performed by medical oncology on August 25, 2021; November 27, 2020; and March 4, 2021 (from left to right).

and even mortality.<sup>15,16</sup> Although most forgotten stents are rediscovered upon abdominal imaging,<sup>15</sup> our case demonstrates that in rare situations, repeat imaging may not be adequate to discover invisible stents, and appropriate clinician judgment based on the clinical presentation will be necessary to avoid the potentially severe consequences of forgotten stents. In such cases, a CT scan, or even more reliably a cystoscopy, might be warranted to find the “invisible stent.”

Further innovations may help resolve this issue by developing materials that are more resistant to losing their radiopaque properties. Additionally, careful communication with patients, as well as timely followup for ureteric stent changes or removal has been shown to significantly reduce the incidence of patients with forgotten stents.<sup>17,18</sup>

**COMPETING INTERESTS:** The authors do not report any competing personal or financial interests related to this work.

This paper has been peer-reviewed.

## REFERENCES

1. Choudhary R, Singh K, Dausage C, et al. Forgotten double J stents with a “Houdini”-like vanishing act. *BMJ Case Rep* 2014;5-7. <https://doi.org/10.1136/bcr-2014-205220>
2. Gupta R, Modi P, Rizvi J. Vanishing shaft of a double-j stent. *Urol J* 2008;5:277-9. <http://journals.sbm.ac.ir/uroj/index.php/uj/article/view/40/39>
3. Hemant Kumar G, Dilip KP, Nipun A, et al. Spontaneous dissolution mid-shaft of a double-J ureteric stent. *UroToday Int J* 2013;6:56. <https://www.urotoday.com/volume-6-2013/vol-6-issue-5/64375-spontaneous-dissolution-mid-shaft-of-a-double-j-ureteric-stent.html>
4. Jayadevan R, Pannell S, Chuang R, et al. A case of an invisible ureteral stent. *Urology* 2018;121:e9-10. <https://doi.org/10.1016/j.urology.2018.08.005>
5. Lee J, Katz M, Shah O. Developments in ureteral stent technology. *Front Surg* 2021;8:1-5. <https://doi.org/10.3389/fsurg.2021.764167>
6. Mosayyebi A, Manes C, Carugo D, et al. Advances in ureteral stent design and materials. *Curr Urol Rep* 2018;19:35. <https://doi.org/10.1007/s11934-018-0779-y>
7. Mosayyebi A, Vijayakumar A, Yue QY, et al. Engineering solutions to ureteral stents: Material, coating, and design. *Cent Eur J Urol* 2017;70:270-4. <https://doi.org/10.5173/cej.2017.1520>
8. Dyer RB, Chen MY, Zagoria RJ, et al. Complications of ureteral stent placement. *Radiographics* 2002;22:1005-22. <https://doi.org/10.1148/radiographics.22.5.g02se081005>
9. Wiseman O, Ventimiglia E, Doizi S, et al. Effects of silicone hydrocoated double loop ureteral stent on symptoms and quality of life in patients undergoing flexible ureteroscopy for kidney stone: A randomized, multicenter clinical study. *J Urol* 2020;204:769-77. <https://doi.org/10.1097/JU.0000000000001098>
10. Gadzhiev N, Gorelov D, Malkhasyan V, et al. Comparison of silicone vs. polyurethane ureteral stents: A prospective, controlled study. *BMC Urol* 2020;20:1-5. <https://doi.org/10.1186/s12894-020-0577-y>
11. Barghouthy Y, Wiseman O, Ventimiglia E, et al. Silicone-hydrocoated ureteral stents encrustation and biofilm formation after 3-week dwell time: Results of a prospective, randomized, multicenter clinical study. *World J Urol* 2021;39:3623-9. <https://doi.org/10.1007/s00345-021-03646-0>
12. Bouzidi H, Traxer O, Doré B, et al. Characteristics of encrustation of ureteric stents in patients with urinary stones. *Prog Urol* 2008;18:230-7. <https://doi.org/10.1016/j.purol.2008.02.004>
13. Tunney MM, Keane PF, Jones DS, et al. Comparative assessment of ureteral stent biomaterial encrustation. *Biomaterials* 1996;17:1541-6. [https://doi.org/10.1016/0142-9612\(96\)89780-8](https://doi.org/10.1016/0142-9612(96)89780-8)
14. Sali GM, Joshi HB. Ureteric stents: Overview of current clinical applications and economic implications. *Int J Urol* 2020;27:7-15. <https://doi.org/10.1111/iju.14119>
15. Vanderbrink BA, Rastinehad AR, Ost MC, et al. Encrusted urinary stents: Evaluation and endourologic management. *J Endourol* 2008;22:905-12. <https://doi.org/10.1089/end.2006.0382>
16. Abdelaziz AY, Fouada WB, Mosharafa AA, et al. Forgotten ureteral stents: Risk factors, complications, and management. *African J Urol* 2018;24:28-33. <https://doi.org/10.1016/j.afju.2017.09.005>
17. Mulay A, Kapoor R, Sharma S, et al. Strategy to track double-J stents placed during COVID-19 using smartphone-based stent tracker application to prevent forgotten double-J stent in a high-volume centre: A smart solution. *African J Urol* 2021;27:110. <https://doi.org/10.1186/s12301-021-00212-3>
18. Lange D, Bidnur S, Hoag N, et al. Ureteral stent-associated complications — where we are and where we are going. *Nat Rev Urol* 2015;12:17-25. <https://doi.org/10.1038/nrurol.2014.340>

**CORRESPONDENCE:** Dr. Mohamad Baker Berjaoui, Division of Urology University of Toronto, Toronto, ON, Canada; mohamadbaker.berjaoui@uhn.ca