

Use of single photon emission computed tomography (SPECT) to study the distribution of ^{90}Y in patients with Baker's cysts and persistent synovitis of the knee

T SMITH,¹ D J SHAWE,² J C W CRAWLEY,¹ AND J M GUMPEL²

From the ¹Radioisotopes Division, Clinical Research Centre and the ²Rheumatology Department, Northwick Park Hospital, Harrow, Middlesex

SUMMARY The presence of a Baker's cyst may diminish the therapeutic effect of intra-articular ^{90}Y treatment to the knee joint. SPECT (single photon emission computed tomography) was used in 10 patients with Baker's cysts, treated with intra-articular ^{90}Y for persistent synovitis of the knee, to measure the amount of radioisotope within the cyst. Comparison was made with the arthrographic appearances. The likelihood or extent of uptake into Baker's cysts of ^{90}Y injected into the synovial cavity of the knee was not predictable from arthrograms. Deposition of ^{90}Y in cysts was variable, ranging from little or no measurable uptake to a substantial proportion of the administered activity (40% in one case out of 10). It did not appear to relate to clinical response. The low mean uptake (6.3%) in cysts of nine out of 10 patients was probably insignificant in view of the large uncertainty in the prediction of synovial radiation dose.

Radioactive colloids have been used to treat chronic synovitis for more than 20 years. Various radionuclides have been used in a range of joints for this purpose, including ^{90}Y , ^{169}Er , ^{186}Re , and ^{198}Au .¹ Yttrium-90 is now commonly used in the knee because of its favourable physical properties, having a short half life (2.7 days), emitting high energy β particles (E_{max} 2.3 MeV), and lacking γ rays.

The presence of a Baker's cyst has been considered an adverse factor when predicting the success of intra-articular radiotherapy to the knee joint. Davis and Jayson described two cases of joint rupture one to two months after ^{90}Y injection and suggested that this was an important hazard.² Quadriceps contraction normally produces sub-atmospheric or small positive pressures within the knee, but in the presence of arthritis high positive pressures are developed; this is enhanced by an effusion.³ Where there is free communication between the knee joint and Baker's cyst ^{90}Y could leak from one to the other. The flow of synovial fluid has been clearly shown by several studies to be uni-directional from the joint to the cyst,⁴⁻⁶ suggesting a valvular connection. This mechanism could cause a

substantial proportion of the administered radioactivity after ^{90}Y treatment to be diverted from the knee joint to the cyst, thereby diminishing the therapeutic effect on the knee synovium.^{7,8}

In this study the use of SPECT to measure the uptake of ^{90}Y in Baker's cysts after injection into the knee joint has been investigated in a small group of patients. We have examined the results for relations between cyst uptake, cyst size, and clinical response which might suggest an adverse influence on therapeutic effect due to the presence of a cyst, and have considered the possibility of modifying the treatment accordingly.

Patients and methods

SUBJECTS

Studies were carried out on 10 patients undergoing ^{90}Y treatment of persistent synovitis of the knee in whom there was clinical evidence of a Baker's cyst. The presence of a cyst was confirmed by standard arthrograms in nine patients and in one a CT scan combined with arthrography was performed. Yttrium-90 silicate (Amersham International) containing 185 MBq ^{90}Y was injected into the synovial cavity, after which the knee was lightly bandaged and the patient was confined to bed for 48 hours. Doses for injection were checked with a calibrated

dose meter (Capintec). These studies were carried out with the approval of the Northwick Park Hospital ethical committee.

MEASUREMENTS

Single photon emission computed tomography (SPECT)⁹ is a technique that provides spatial information about the distribution of a radionuclide which is better than can be achieved by conventional planar imaging. Multiple images of the distribution are obtained with a gammacamera capable of rotation about the patient. The information so obtained is processed using a method of filtered back-projection, by means of a dedicated computer, to produce a three dimensional data set from which the information contained in mutually perpendicular slices through the region (transaxial, sagittal, coronal) can be extracted. Thus SPECT improves the signal to background ratio compared with conventional imaging as it provides slice images with virtually no background activity. Such a system is capable of use with radionuclides which emit single photons and is therefore simpler, cheaper, and more widely applicable than positron emission tomography systems.

In this study measurements were made with an IGE (International General Electric Co, New York) 400AT rotating gammacamera to detect bremsstrahlung radiation from ⁹⁰Y; this involved the acquisition of 64 views of the knee taken at equal angles within a complete rotation. A STAR computer was used to reconstruct three dimensional tomographic slices (0.63 cm thick) through the treated knee. Nine subjects were measured on three separate occasions; within the first two hours and at 24 and 46 hours. One subject was measured at two and 46 hours only.

In all patients sagittal tomographic slices were

used for quantification because they usually provided best definition of ⁹⁰Y activity in Baker's cysts. For all patient measurements estimates were made of the total ⁹⁰Y activity in the knee and of ⁹⁰Y uptake in the Baker's cyst. These were estimated from the integrated counts in reconstructed slices which exceeded a threshold value set at 10% of the maximum pixel (picture element) counts within the family of slices, considering either the total knee or the cyst alone. All counts were corrected for decay of ⁹⁰Y from the time of injection, and the administered activity was assumed to be exactly 185 MBq in all cases. In addition, the volume of distribution of radioactivity in a cyst was estimated by integrating the number of voxels (cubic pixels) of volume 0.25 cm³ enclosed within a 50% count rate threshold.

Measurement of uptake of ⁹⁰Y in cysts was achieved by the use of realistic 'knee' phantoms, measured under conditions identical to those employed for the patients. The phantoms consisted of human femur and tibia bones obtained after death placed inside water filled perspex cylinders. Studies were then carried out with ⁹⁰Y sources of various sizes positioned behind the phantom knee joint. Calibration factors appropriate for a particular patient were interpolated from the results of the phantom measurements after estimating the dimensions of the knee by direct measurement or from radiographs.

A three dimensional representation of the data of one patient was produced using all voxels with counts above a 20% threshold, following the method of Webb *et al.*,¹⁰ to examine the usefulness of this technique for visualising cysts.

Leakage of ⁹⁰Y from the knee was monitored by estimation of liver radioactivity at 46 hours in eight patients and of lymph node radioactivity in one patient showing uptake in the groin.

Table 1 Estimated uptake of ⁹⁰Y in Baker's cysts (percentage of administered activity) at different intervals, and clinical response up to 12 months

Patient No	Size index of cyst†	Uptake in cyst (% of administered activity)			Clinical response‡	
		1-2 h	24 h	46 h	6 mo	12 mo
1	*	14.6	10.4	11.2	++	++
2	*	37.2	40.3	35.5	+	++
3	**	0	0	0	+++	+
4	***	1.7	6.0	4.8	++++	++++
5	***	0.7	2.7	3.4	-	-
6	***	15.1	19.6	16.7	+++	+++
7	*	0	0	0	++	+
8	**	7.8	7.3	6.8	+	+
9	-	11.9	Not done	10.2	++	+
10	***	1.0	3.7	2.2	+++	-

†Size index: * <20; **20-40; *** >40. See text.

‡ Clinical response: + poor, ++ slight, +++ good, ++++ excellent.

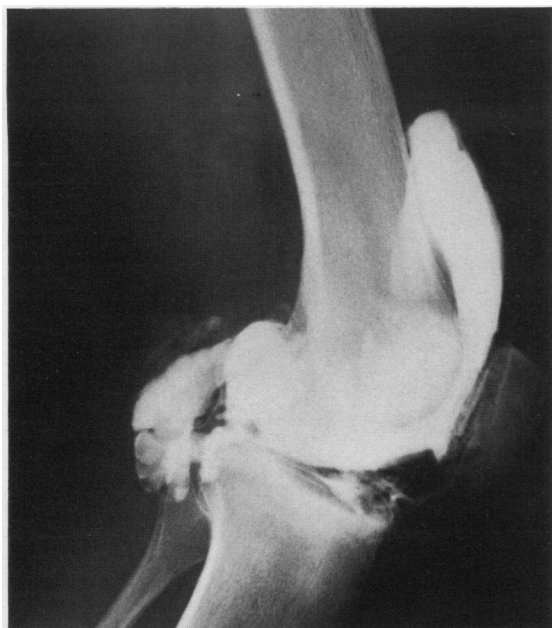


Fig. 1a

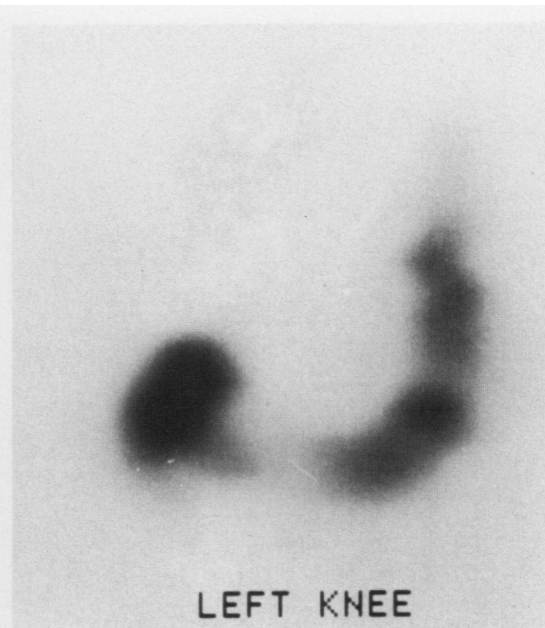

Fig. 1b

Fig. 1 Arthrogram (a) showing the presence of contrast medium, and a corresponding single sagittal SPECT slice (b) showing ^{90}Y , in the relatively small Baker's cyst which had the highest measured uptake of ^{90}Y (patient No 2).

Results

Table 1 shows the serial estimates of the ^{90}Y content of cysts in the 10 patients, normalised as a percentage of the administered activity, which were obtained using estimated cyst volumes and calibration factors interpolated from phantom measurements. Table 1 also includes an index of the size of the Baker's cysts for comparison with estimated uptakes. This index was estimated from arthrograms as the product of the maximum vertical and horizontal dimensions (cm) of the two dimensional image of the cyst, and cysts were graded according to whether this index was less than 20, between 20 and 40, or greater than 40.

Uptake of ^{90}Y in cysts was very variable, ranging from 0 to about 40% of administered radioactivity with a mean value of 9.4%. Apart from the single high value of 40%, however, uptake in the remaining nine patients did not exceed 20% with a mean value of 6.3%. Figs 1a and b show a single sagittal slice through the knee of the patient who had the highest cyst uptake in relation to the arthrogram, and Fig. 2 shows the result of a three dimensional reconstruction of tomographic data for the same patient. In some cases retention in cysts remained

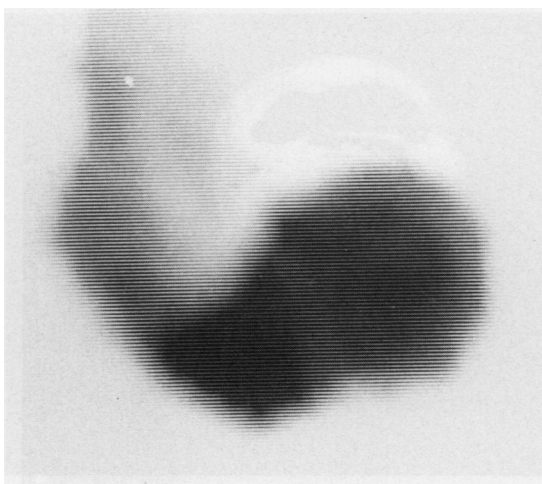


Fig. 2 Three dimensional reconstruction of tomographic data showing the size, shape, and location of a Baker's cyst (patient No 2).

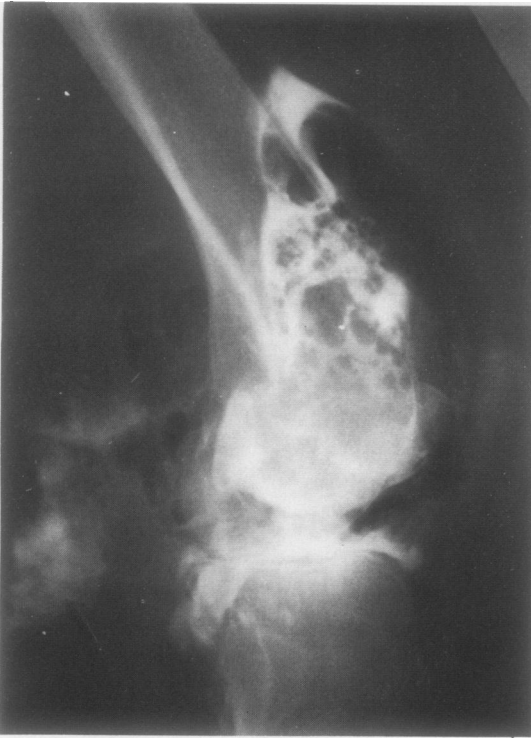

Fig. 3a

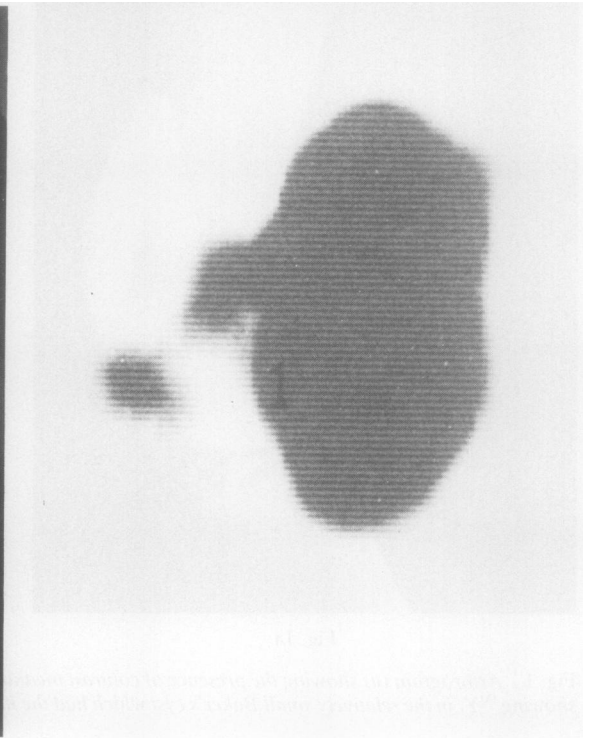


Fig. 3b

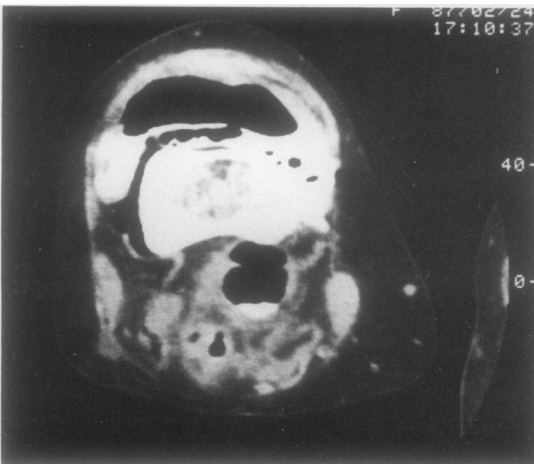

Fig. 3c

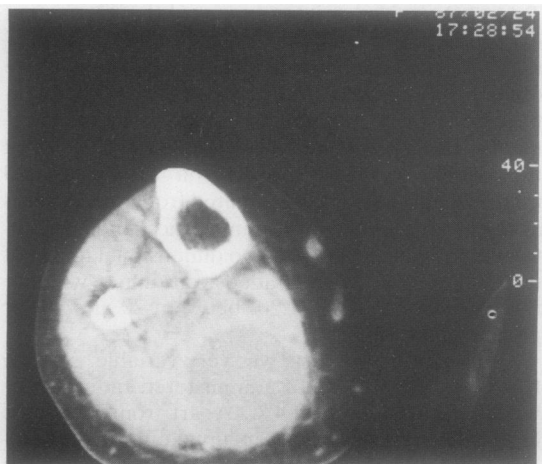


Fig. 3d

Fig. 3 Comparison of the arthrogram and SPECT and CT images in patient No 10. The initial lateral arthrogram (a), sagittal SPECT slice (b) and CT slice (c) show ample evidence of contrast medium and air, but little ^{90}Y in a popliteal cyst behind the knee. The large fluid filled cyst shown in a CT slice taken about 8 cm below the knee joint (d) showed no uptake of contrast medium, air, or ^{90}Y .

reasonably constant but in others there was a suggestion of slow accumulation.

Comparison of the ^{90}Y content of Baker's cysts and the arthrographic appearance of the cysts (and the apparent ease with which the cyst was filled with contrast material) was unhelpful, even in retrospect. In particular, patient 9 had a palpable popliteal cyst, which was not demonstrated by arthrography, but the presence of the cyst was confirmed by finding about 10% of administered activity within it.

A CT scan on patient 10 highlighted the problem. Clinically the patient had an easily palpable popliteal cyst and an evident calf cyst extending to the mid-calf. Contrast medium, air, and ^{90}Y were shown in the popliteal cyst (Figs 3a, b, and c), but none penetrated into the calf cyst, which is clearly shown in the CT slice (Fig. 3d) approximately 8 cm below the joint. It was necessary to increase the image contrast to visualise the small amount of ^{90}Y taken up in the popliteal cyst.

The clinical outcome of intra-articular ^{90}Y treatment in nine of the 10 patients is known; four patients showed no significant improvement in the degree of synovitis at 12 months' follow up, while the remainder responded to a variable extent (Table 1).

Discussion

The arthrograms demonstrated that the wide range of size of Baker's cyst, varying from popliteal cysts to large calf cysts, as seen in clinical practice, was adequately represented in this study.

The picture emerging from this small group of patients is that the uptake of ^{90}Y in Baker's cysts in the 48 hours after injection is both variable and unpredictable. No clear relation between ^{90}Y uptake and size of Baker's cysts can be shown. Whereas the highest observed uptake (40% of administered radioactivity) occurred in a cyst that was of moderate size on arthrography, larger cysts showed little or no evidence of ^{90}Y uptake and a significant uptake of 10% was measured in one cyst which, although clinically apparent, could not be demonstrated unequivocally by arthrography.

When the single high uptake value of 40% is excluded the mean uptake in the remaining nine patients was only about 6% of the injected ^{90}Y . This probably leads to an insignificant modification of the therapeutic effect, particularly in view of the difficulties in the estimation of radiation dose resulting from our imprecise knowledge of the actual surface area of synovial membrane, and the spatial relationship between ^{90}Y particles and the cells of the membrane. It is evident that in a small proportion of patients there is substantial uptake in cysts, which may be sufficient to reduce the therapeutic effect

significantly, leading to an unsatisfactory response; after follow up in such cases further ^{90}Y treatment may be judged to be necessary. The patient in our series with highest cyst uptake (patient No 2) showed little improvement in the degree of synovitis up to one year after treatment, but, in general, clinical response showed poor correlation with uptake of ^{90}Y in cysts (Table 1). For example, poor clinical response was also observed in two patients (3 and 7) who had no measurable cyst uptake. Furthermore, while two patients (4 and 10) with low uptakes showed good or excellent response, a good response was also observed in patient 6 who had the second highest cyst uptake. Because the uptake in cysts is not predictable from the apparent size and filling of cysts on arthrograms we are unable to suggest the expedient of injecting more radioactivity at the first injection.

The use of a computer program to produce three dimensional images of the knee of one of our patients suggests that the application of this technique has significant value in improving subjective visualisation of the distribution of ^{90}Y in the knee. The example in Fig. 2 shows one of 64 different views around the longitudinal axis of the patient, allowing examination of the distribution from all aspects. The size, shape, and location of the cyst can be appreciated more clearly than from separate transaxial, sagittal, or coronal slices, suggesting a complementary role for this technique, particularly in cases of marginal or equivocal cyst uptake.

Monitoring of the uptake of ^{90}Y in liver and lymph nodes has been used to detect leakage from the knee, but the uptake at these sites usually does not fully account for activity apparently lost from the knee.⁷ In the present studies the mean (SD) retention in knees at 46 hours was 85 (12)% of administered ^{90}Y , whereas the highest combined uptake in liver and lymph nodes was 6%. Spooen *et al* found no trace of radioactivity in regional lymph glands of 10 patients at 24 or 48 hours after injection of ^{90}Y silicate into the knee joint.¹¹ Although the residual ^{90}Y released from the knee is presumably generally distributed throughout the body, it is possible that in some cases discrepancies can be partly explained by changes in counting efficiency resulting from observed alterations in distribution of injected ^{90}Y within the knee as suggested by the results of measurements on phantoms.

Redistribution of ^{90}Y within the knee also emphasises the difficulty of making accurate radiation dose estimates. The wide variation in such estimates was illustrated in a series of 16 knees (11 patients) by Williams,⁷ who calculated doses in the range of 22–104 Gy when assumptions were made regarding the area and thickness of the synovial membrane

and the distribution of ^{90}Y particles on its surface. The mean value of 58 (SD 25) Gy was similar to the value of 72 Gy estimated by Stevenson *et al*¹² using different assumptions. Although an ideal therapeutic protocol would allow for variable amounts of ^{90}Y to be prescribed for different patients, the lack of accurate dosimetry has led to an empirical approach in which a standard quantity of ^{90}Y (185 MBq) is injected. The application of emission computed tomography, however, could yield useful information about the size and shape of the synovial cavity and distribution of ^{90}Y within it, which together with accurate retention data should help to improve the precision of radiation dose estimation.

In conclusion this study has shown that in ^{90}Y treatment of persistent synovitis the uptake of ^{90}Y into Baker's cysts was very variable, was unpredictable from arthrographic appearances, and was poorly related to clinical response. There is insufficient evidence from this study to indicate that the dose of administered radioactivity should be increased in the presence of a cyst.

We wish to thank Dr R Mitchell, Radiology Department, Northwick Park Hospital, for performing the CT scan on one of our patients, and Mr R Copeland for technical assistance.

References

- 1 Ingrand J. Characteristics of radioisotopes for intra-articular therapy. *Ann Rheum Dis* 1973; **32** (suppl): 3-9.
- 2 Davis P, Jayson M I V. Acute knee joint rupture after yttrium-90 injection. *Ann Rheum Dis* 1975; **34**: 62-3.
- 3 Jayson M I V, Dixon A St J. Intra-articular pressure in rheumatoid arthritis of the knee: pressure changes during joint use. *Ann Rheum Dis* 1970; **29**: 401-8.
- 4 Hall A P, Scott J T. Synovial cysts and rupture of the knee joint in rheumatoid arthritis: an arthrographic study. *Ann Rheum Dis* 1966; **25**: 32-41.
- 5 Jayson M I V, Dixon A St J. Valvular mechanisms in juxta-articular cysts. *Ann Rheum Dis* 1970; **29**: 415-20.
- 6 Taylor A R. The formation of popliteal cysts [Abstract]. *Proceedings of the VIIth European rheumatology congress*. 1971: 15.
- 7 Williams E D. Methods of measuring retention of radioisotopes in the knee and extra-articular spread in vivo. *Ann Rheum Dis* 1973; **32** (suppl): 13-15.
- 8 Gumpel J M, Williams E D, Glass H I. Use of yttrium-90 in persistent synovitis of the knee. *Ann Rheum Dis* 1973; **32**: 223-7.
- 9 Keyes J W. Single-photon computed tomography: instrumentation. In: Ell P J, Holman B L, eds. *Computed emission tomography*. Oxford: Oxford University Press, 1982: 243-62.
- 10 Webb S, Ott R J, Flower M A, McCready V R, Meller S. Three-dimensional display of data obtained by single photon emission computed tomography. *Br J Radiol* 1987; **60**: 557-62.
- 11 Spooner P F M J, Rasker J J, Arens R P J H. Synovectomy of the knee with ^{90}Y . *Eur J Nucl Med* 1985; **10**: 441-5.
- 12 Stevenson A C, Bedford J, Dolphin G W, *et al*. Cytogenetic and scanning study of patients receiving intra-articular injections of gold-198 and yttrium-90. *Ann Rheum Dis* 1973; **32**: 112-23.