

## **Case report**

# **Acute non-infectious arthritis of the hip in rheumatoid arthritis: synovial membrane findings**

JEFFREY R WOHLGETHAN, MAGDA M STILMANT, JOHN McA HARRIS III, AND HOWARD R SMITH

*From the Departments of Medicine, Pathology and Orthopedic Surgery, Boston Veterans Administration Medical Center, and the Arthritis Center of Boston University, Boston, Massachusetts, USA*

**SUMMARY** A case of acute hip pain in rheumatoid arthritis is presented, with synovial membrane findings. A patient with classical rheumatoid arthritis suffered three unusual bouts of sudden, severe but transient hip pain. The hips were clinically normal between these episodes. The clinical picture on two of these occasions strongly suggested septic arthritis. Although the synovial fluid was highly inflammatory, cultures were negative. The synovial membrane showed mild lining cell hyperplasia, vascular congestion, and scattered inflammatory cells, predominantly lymphocytes. These findings were not compatible with either pyogenic infection or longstanding rheumatoid arthritis. The clinical and pathological features of acute non-infectious arthritis of the hip appear to delineate a distinct syndrome.

A recent report called attention to an acute non-infectious arthritis of the hip in five patients with rheumatoid arthritis.<sup>1</sup> We wish to report an additional case, in which the clinical and pathological findings support the notion of a distinct form of arthritis of the hip in rheumatoid arthritis.

### **Case report**

A 60 year old man with a nine year history of classical rheumatoid arthritis,<sup>2</sup> responding well to monthly injections of a gold compound, was admitted to hospital with suspected infection of the right hip. The night before admission he rolled over in bed and felt sharp pain in his right groin radiating down the anterior thigh to just above the knee. Over the next 24 hours he had increasingly severe pain, leading to inability to walk. Both hips had been entirely normal on a comprehensive examination at the first visit to the rheumatology clinic one year earlier, and he had had no subsequent complaints of hip pain. There was a history of excisional biopsy of

a subcutaneous nodule (proved to be a rheumatoid nodule) but no history of vasculitis or other extra-articular features of rheumatoid arthritis. Previous treatment had included prednisone but only 5 mg daily for a period of about three months.

On physical examination he appeared well but lay still with the right hip held in flexion. The oral temperature was 38.6°C. There were characteristic rheumatoid deformities of various joints with only slight swelling and tenderness. No nodules were noted. There was severe pain in the right groin with any active or passive motion of the right hip. The range of motion on the right was about 60 degrees of flexion, compared with greater than 100 degrees on the left; and 10 degrees of internal rotation and 10 of external rotation on the right, compared with 15 and 45 on the left.

Laboratory evaluation was remarkable for a peripheral white blood cell count of  $14 \times 10^9/l$  and a packed cell volume of 0.38. A Westergren erythrocyte sedimentation rate was 54 mm/h. Serum chemistry profile, chest radiograph, electrocardiogram, and urine analysis were all normal. A radiograph of the pelvis showed only slight sclerosis of the superior margin of the acetabulum of both hips, with normal cartilage spaces. A latex fixation test for

Accepted for publication 8 August 1988.

Correspondence to Dr Jeffrey R Wohlgethan, Rheumatology A 10–90, Boston VA Medical Center, 150 South Huntington Avenue, Boston, MA 02130, USA.

rheumatoid factor was positive in a titre of 1/640 (normal <1/160).

Under fluoroscopy 15 ml of turbid yellow fluid was aspirated from the right hip joint. The white blood cell count was  $113 \times 10^9/l$ , with 99% polymorphonuclear leucocytes, and the red cell count was  $0.4 \times 10^9/l$ . The mucin clot was graded as poor on a scale of good-fair-poor.<sup>3</sup> A Gram stain was negative. No crystals were seen on polarisation microscopy. A determination of glucose was not carried out.

At arthrotomy, 12 hours after admission, the cartilage of the femoral head appeared normal. A repeat synovial fluid analysis yielded results similar to the first; Gram stain and a search for crystals were again negative. Closed suction drainage was instituted, and treatment with intravenous clindamycin was begun (the patient was allergic to penicillin).

Over the next several days fever persisted but hip pain steadily improved. The peripheral white blood cell count was  $10.6 \times 10^9/l$  when repeated less than 12 hours after admission, before surgery and antibiotic treatment, and continued to fall rapidly. On day 3 the erythrocyte sedimentation rate had risen to 94 mm/h. The packed cell volume gradually fell, reaching a low of 0.3.

Drainage was discontinued on the third day after the operation. Within a week of admission the patient was nearly fully recovered and antibiotic treatment was stopped. Cultures of synovial fluid and synovium were negative for aerobic or anaerobic bacteria and, it was subsequently reported, fungi and mycobacteria. Histological examination of the synovium (Fig. 1) showed a mild synovitis not compatible with pyogenic infection.<sup>4</sup>

Although the hip pain resolved fully, for the next

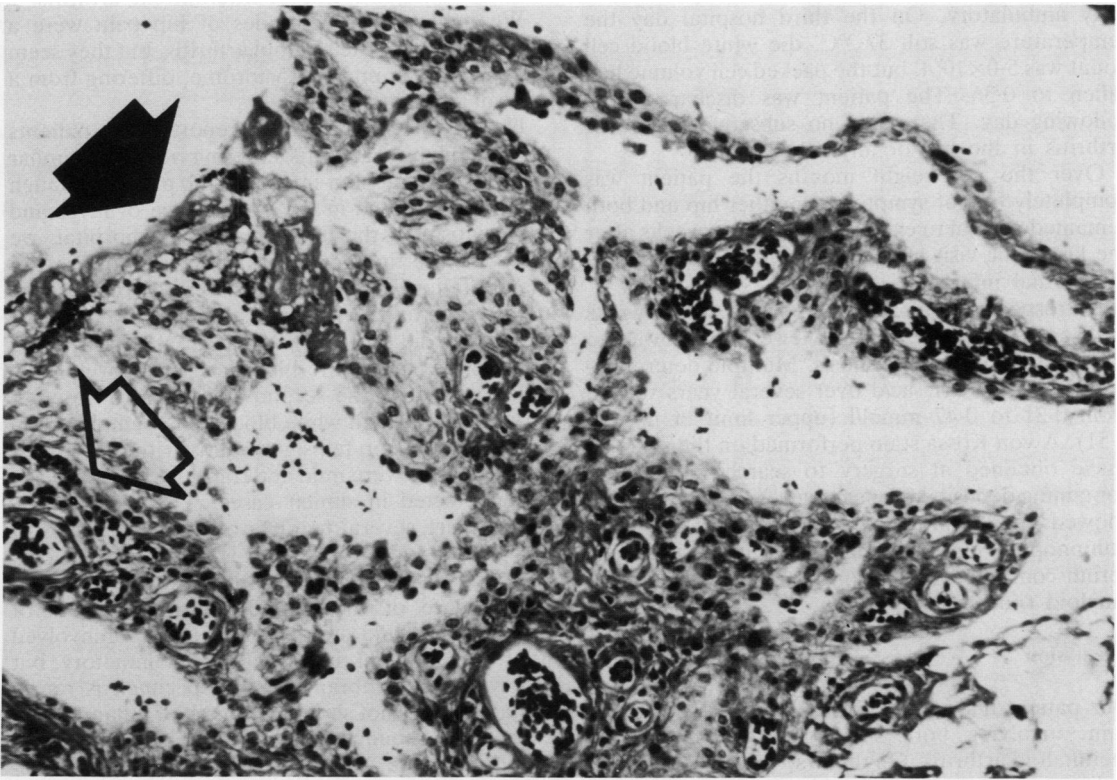


Fig. 1 Synovium from the right hip. There is mild lining cell hyperplasia, seen best at the free edge along the upper part of the field. There is fibrin deposition (closed arrow) and vascular congestion with scattered inflammatory cells, predominantly lymphocytes, around capillaries (open arrow). Haematoxylin and eosin stain.

month the patient had increased pain and tenderness in other joints, especially the wrists, elbows, and shoulders. He provided the additional history that the onset of sustained polyarthritis some nine years earlier had been heralded by a very abrupt episode of severe right groin pain (without fever), which had left him bedridden for several days but resolved without medical attention.

The patient had no further symptoms in either hip until eight months later when he was readmitted with severe pain in the left groin that awoke him at night. On examination he appeared well but lay still with the left hip held in flexion. The oral temperature was 38.2°C. There was severe pain in the groin with any active or passive motion of the left hip. The peripheral white blood cell count was  $10.4 \times 10^9/l$ , the packed cell volume was 0.4, and the erythrocyte sedimentation rate was 54 mm/h. In light of the two previous episodes of acute non-septic hip pain no attempt was made to aspirate the hip and antibiotics were not given. Narcotic analgesia was required for approximately 36 hours. One day after admission the oral temperature was 37.2°C and the patient was fully ambulatory. On the third hospital day the temperature was still 37.2°C, the white blood cell count was  $5.0 \times 10^9/l$ , but the packed cell volume had fallen to 0.36. The patient was discharged the following day. There was no subsequent flare of arthritis in the hip or any other joint.

Over the next eight months the patient was completely free of symptoms in either hip and both remained normal to examination. A few weeks after the last clinic visit he died at another hospital of a myocardial infarction.

Retrospectively, radiographs of the pelvis, wrists and hands, and knees were reviewed and showed no evidence of chondrocalcinosis. Multiple determinations of serum uric acid over several years ranged from 0.21 to 0.47 mmol/l (upper limit of normal 0.51). A von Kossa stain performed on the synovial tissue obtained at surgery to search for calcium containing deposits was negative. A Congo red stain showed small amounts of perivascular amyloid; immunoperoxidase staining with a polyclonal antiserum confirmed deposition of AA, or secondary, amyloid (not shown).

### Discussion

Our patient had three distinct bouts of severe hip pain, involving both sides, during 10 years of rheumatoid arthritis. On the first hospital admission a diagnosis of septic arthritis seemed certain, yet cultures were negative and the mild synovitis found on biopsy was not compatible with pyogenic infection.<sup>4</sup> We believe recovery was not related to

the antibiotic treatment. The next, nearly identical, episode was clearly self limited.

A crystal induced arthritis could account for this picture and cannot be absolutely excluded. Gout must be considered but is extremely unlikely in view of the absence of a history of gout in other joints, the rarity both of gout coexistent with rheumatoid arthritis and of gouty involvement of the hip, the normal serum uric acid concentration, and the negative search for synovial fluid urate crystals in two samples. Pseudogout is a possibility, but the negative search for crystals in synovial fluid and membrane, the negative stain for calcium salts in the synovial membrane, and the absence of radiological evidence of chondrocalcinosis in either hip or in the pubic symphysis, knees, shoulders, or wrists are against the diagnosis of calcium pyrophosphate deposition disease. Finally, the negative von Kossa stain is evidence against the presence of basic calcium phosphate, or hydroxyapatite, crystals,<sup>5</sup> which may cause an acute arthritis similar to gout.<sup>6</sup>

The clinical presentation does not fit with any of the other major forms of intermittent arthritis.<sup>7</sup>

We believe these episodes of hip pain were a manifestation of rheumatoid arthritis, but they seem to represent an unusual syndrome, differing from a typical rheumatoid flare.

Halla and Hardin recently reported five patients with rheumatoid arthritis suffering from very similar episodes of acute non-infectious hip pain.<sup>1</sup> Although our patient differs in the prominence of fever and leucocytosis on the first admission to hospital, we believe these findings simply reflect a more severe manifestation of the same process as our patient reported no fever with his first bout of hip pain (for which he did not seek medical attention), and temperature and white blood cell count were only mildly raised on the second admission to hospital. Moreover, the high white blood cell count noted on the first admission fell significantly within 12 hours; if leucocytosis were mild and transient it could easily go undetected in similar cases.

There are several features of the hip arthritis of our patient and of Halla and Hardin's five patients that delineate a clinical entity distinct from the typical flare of rheumatoid arthritis. Pain is of sudden onset and strikes a previously uninvolved joint. The synovial fluid is highly inflammatory, but the synovial membrane, if our specimen is representative, does not show the degree of inflammation expected in rheumatoid arthritis.<sup>4</sup> There is an acute phase response, with a raised erythrocyte sedimentation rate, and possibly leucocytosis and a fall in the packed cell volume. The picture closely resembles septic arthritis, but cultures are negative, and the episode remits within days.

It should be noted in regard to the course that Halla and Hardin treated only four of their five patients with an intra-articular injection of corticosteroid, yet the fifth patient recovered spontaneously, as did our patient on three occasions.

The dramatic abruptness of our patient's hip pain brings palindromic rheumatism to mind,<sup>8</sup> but the findings are not fully consistent with that form of arthritis. The patient did not have typical palindromic attacks in other joints: flares were never so abrupt nor so transient. Halla and Hardin state that their patients all had occasional flares of arthritis in joints other than the hip but make no mention of palindromic rheumatism. The pattern of isolated attacks limited to the hips and persisting after the onset of sustained polyarthritis does not fit with classical descriptions of palindromic rheumatism. Patients with this condition either continue to have palindromic attacks or go on to develop sustained polyarthritis<sup>9</sup>; palindromic rheumatism as part of rheumatoid arthritis is a pattern of *onset*. Finally, although the changes in the synovial membrane in our case were similar to those recorded by Hench and Rosenberg,<sup>8</sup> the synovial fluid white blood cell count and the percentage polymorphonuclear leucocytes were considerably higher than those reported by Schumacher.<sup>10</sup>

It is doubtful that the small deposits of amyloid noted in the synovial membrane had any relation to the clinical presentations. Our patient probably had subclinical secondary amyloidosis, unrecognised during life, a not unusual finding in rheumatoid arthritis.<sup>11</sup>

In view of the increased risk from infection in rheumatoid arthritis and the urgent nature of septic arthritis of the hip prompt treatment for presumed infection is appropriate in cases of acute severe hip

pain with inflammatory synovial fluid. The diagnosis of non-septic synovitis will probably, in many cases, be made only in retrospect. Full recognition of the syndrome of acute non-infectious hip pain in rheumatoid arthritis as a distinct clinical entity must await further reports.

#### References

- 1 Halla J T, Hardin J G. Acute non-infectious arthritis of the hip in patients with rheumatoid arthritis. *Ann Rheum Dis* 1987; **46**: 475-6.
- 2 Ropes M W, Bennett G A, Cobb S, Jacox R, Jessar R A. 1958 revision of diagnostic criteria for rheumatoid arthritis. *Bull Rheum Dis* 1958; **9**: 175-6.
- 3 Cohen A S, Goldenberg D. Synovial fluid. In: Cohen A S, ed. *Diagnostic procedures in the rheumatic diseases*. 3rd ed. Orlando: Grune and Stratton, 1985: 1-54.
- 4 Goldenberg D L, Cohen A S. Synovial membrane histopathology in the differential diagnosis of rheumatoid arthritis, gout, pseudogout, systemic lupus erythematosus, infectious arthritis and degenerative joint disease. *Medicine (Baltimore)* 1978; **57**: 239-52.
- 5 McCarty D J, Halverson P. Basic calcium phosphate (apatite, octacalcium phosphate, tricalcium phosphate) crystal deposition diseases. In: McCarty D J, ed. *Arthritis and allied conditions*. 10th ed. Philadelphia: Lea and Febiger, 1985: 1547-64.
- 6 Schumacher H R, Smolyo A P, Tse R L, Maurer K. Arthritis associated with apatite crystals. *Ann Intern Med* 1977; **87**: 411-6.
- 7 Ehrlich G E. Intermittent and periodic arthritic syndromes. In: McCarty D J, eds. *Arthritis and allied conditions*. 10th ed. Philadelphia: Lea and Febiger, 1985: 883-900.
- 8 Hench P S, Rosenberg E F. Palindromic rheumatism. *Arch Intern Med* 1944; **73**: 293-320.
- 9 Wajed M A, Brown D L, Currey H L F. Palindromic rheumatism. *Ann Rheum Dis* 1977; **36**: 56-61.
- 10 Schumacher H R. Palindromic onset of rheumatoid arthritis. Clinical, synovial fluid and biopsy studies. *Arthritis Rheum* 1982; **25**: 361-9.
- 11 Cathcart E S, Wohlgethan J R. Amyloidosis. In: Utsinger P D, Zvaifler N J, Ehrlich G E, eds. *Rheumatoid arthritis*. Philadelphia: Lippincott, 1985: 495-501.