

REVIEW ARTICLE

Subchondral avascular necrosis: a common cause of arthritis

Peter G Bullough, Edward F DiCarlo

Arthritis is the term we use to indicate dysfunction of a joint, clinically characterised by pain, instability, and loss of motion. Normal function depends on intact joint anatomy and neuromuscular control.¹ Therefore, arthritis may result from any condition which (a) alters the configuration of the components of a joint, in particular, the contour of the articulating surfaces; (b) affects the mechanical properties of the materials that make up these components—for example, bone, cartilage, and collagenous tissue; (c) disturbs the neuromuscular control of the joint.

Necrosis in the subchondral region of a bone is a common cause of arthritis in our experience, though it is regarded as uncommon by others.² With necrosis in the subchondral region, arthritis results from the change in the contour of the articular surface caused by collapse of the necrotic subchondral bone.

After a short historical discussion of terminology and incidence the morbid anatomy of the disease will be presented so that the reader may be better able to interpret the radiological images and understand the clinical presentations, both of which will be presented later. A brief discussion of treatment will then be presented.

TERMINOLOGY

It is generally accepted that death of tissue—'necrosis'—results from one of four primary types of injury: (a) physical, (b) thermal, (c) toxic, or (d) circulatory. When necrosis occurs secondary to circulatory disturbances, whether because of arterial disease, embolism, or obstruction of the venous system, the resultant region of necrosis is referred to as an 'infarct'. Although circulatory disturbance is assumed to be the principal mechanism of necrosis in the ends of bones, the cause of the disruption cannot usually be shown by anatomical dissection. Because of this a large number of names has been given to necrosis occurring in bones. Some of these names include segmental subchondral infarction, osteonecrosis, ischaemic necrosis, idiopathic avascular necrosis, aseptic necrosis, steroid necrosis, and many eponymic designations (including Perthes' disease, Freiberg's disease, Kienböck's disease, etc) depending on the anatomical locations and joints involved.

In this review we will use the term 'subchondral avascular necrosis' to describe a local-

ised area of bone and bone marrow necrosis occurring immediately beneath the articular surface, usually in the convex component of a joint. We have chosen this term, firstly, to distinguish this condition from necrosis occurring in other parts of the skeleton and, secondly, because the involved regions, regardless of the cause, are without a functional blood supply.

INCIDENCE AND DEMOGRAPHICS

Before the 1960s subchondral avascular necrosis without a history of fracture was considered unusual,³ and by 1962 only 27 reported cases of such necrosis could be found by Mankin and Brower.⁴ The overall incidence of subchondral avascular necrosis in any population is difficult to determine because the lesion may be clinically silent in a significant proportion of cases. Certain groups of people have a predilection for the condition, however. Some of these groups at risk, who are likely to be encountered in clinical practice, are alcoholics,⁵⁻⁸ people taking corticosteroids,^{5,8,9} black subjects with sickle cell disease,¹⁰ and Jews with Gaucher's disease.¹¹

In our laboratory about 18% of the approximately 1000 femoral heads removed each year in total hip replacement procedures for non-traumatic causes show evidence of subchondral avascular necrosis. Approximately 60% of the cases are bilateral; the reported incidence of bilaterality is estimated to be 75%.¹² The incidence in our population is slightly higher among women than among men, about 1.2 to 1. As summarised in the table this distribution is at variance with the male predominance reported before 1971, and it may be the result of the increasing incidence of steroid related cases as well as the particular case load at our institution. (The Hospital for Special Surgery is exclusively devoted to orthopaedic surgery and rheumatological diseases.)

The mean age of patients with subchondral avascular necrosis of the hip presenting in our

Male/female distribution of subchondral avascular necrosis of the femoral head

Authors	Patients (n)	M:F	Reference
Volle	199	4:1	13
Patterson <i>et al</i>	52	4:1	14
Merle d'Aubigne <i>et al</i>	125	4.5:1	15
Hastings and MacNab	14	4:3	16
McCullum <i>et al</i>	68	4.25:1	17
Zinn	48	3.8:1	18

Department of Pathology, Cornell University Medical College, and Department of Laboratory Medicine, Hospital for Special Surgery, New York, USA
P G Bullough
E F DiCarlo

Correspondence to:
Professor Peter G Bullough,
Hospital for Special Surgery,
535 East 70th Street,
New York, New York 10021,
USA.

hospital is 55 years as compared with the mean age of 67 in patients with primary osteoarthritis.

HISTORY

In his lectures on surgical pathology in 1860 James Paget clearly described the gross appearance of bone necrosis.¹⁹

In 1888 the first description of necrosis in a femoral head associated with Caisson's disease was published by Twynham,²⁰ and in 1911 Bornstein and Plate made a study of 500 construction workers on the Elbe tunnel.²¹ In that paper they described the clinical picture of decompression disease, and gave detailed accounts of three patients with hip pain whose radiographs showed the typical picture of subchondral avascular necrosis of the femoral head.

In 1915 Phemister described the microscopic findings in necrotic bone, comparing the changes in bone dying as a result of infection ('septic necrosis') with those resulting from a circulatory interference ('aseptic necrosis').²² In 1920 he related the pathological and radiological changes seen in dead bone,²³ and then 10 years later, in a paper read to the American Orthopaedic Association, he discussed the reparative processes occurring around dead bone following fracture, grafting, and vascular occlusion.²⁴ In this classic paper Phemister coined the term 'creeping substitution' for the process whereby the dead bone is finally removed after a layer of living bone has been deposited onto the pre-existing dead bone.

In 1922 Axhausen reported the occurrence of aseptic necrosis in patients with alcoholism.⁷ The relation between subchondral avascular necrosis and alcoholism was later to be developed by Jones *et al* in 1968.⁸

The relation of subchondral avascular necrosis to steroids was first noted by Pietrogrande and Mastromarino in 1957.²⁵ Confirmation of this was made by Mandel and Freeman, who in 1964 reported a case of aseptic necrosis of the femoral head in a patient with Cushing's disease.²⁶ Increasing renal transplantation and postoperative steroid treatment provided Creuss *et al* with further clinical evidence of the association between this disease and steroid treatment.²⁷

In 1965 Catto published two excellent papers giving details of the destructive and reparative changes in subchondral avascular necrosis of the femoral head.^{28, 29} In these papers she considered the changes occurring in the femoral head after subcapital fractures of the neck of the femur, and dealt with the pathological processes in detail.

Morbid anatomy

Four stages in the development of subchondral avascular necrosis have been defined morphologically and these may be shown to correlate with observed radiographic appearances.³⁰⁻³³ The first stage is characterised predominantly by the presence of necrosis of both bone and bone marrow without evidence of repair. In the second stage reparative processes are evident at the periphery of the necrotic region. The major feature of the third stage is segmental collapse of

the articular surface. In the fourth stage features of secondary osteoarthritis have developed. It is important to recognise that the morphological features of subchondral avascular necrosis are a composite of both necrotising and reparative processes and that at least some of the apparently degenerative features—for example, segmental collapse in stage III, which gives rise to clinical symptoms, may be contributed to by the reparative processes.

STAGE I

In this stage the shape of the joint is unaltered and external examination of the joint shows no abnormalities. On cut section, however, the necrotic zone, recognised as a somewhat wedge-shaped region in which the marrow is dull yellow, chalky, and opaque, may be seen in an immediately subarticular location (fig 1). This region is usually well demarcated and separated from the surrounding bone marrow by a thin, red, 'hyperaemic' border. The marrow beyond this border shows no specific abnormality referable to the necrotising process, but may have an abnormal appearance depending on any associated or predisposing conditions—for example, sickle cell disease with its dark red bone marrow, and Gaucher's disease with its pale and waxy marrow. At this stage changes in the trabecular architecture are not appreciable either by gross inspection or on specimen radiographs, which typically show no abnormality.

On microscopic examination the overlying articular cartilage appears viable down to the calcified zone. The bony end-plate, however, is necrotic. The subchondral bone, corresponding to the opaque yellow region seen grossly, is characterised by necrotic bone and bone marrow. The marrow elements are replaced by granular, eosinophilic material lacking cellular elements except for the occasional ghosts of disrupted fat cells (fig 2). There may also be cysts of lipid material which, with calcification, may appear as saponified fat ('soap'). In the bone the osteocytic lacunae may be empty, contain cellular debris, or have a pale-staining nucleus. At the margin of the infarct there is

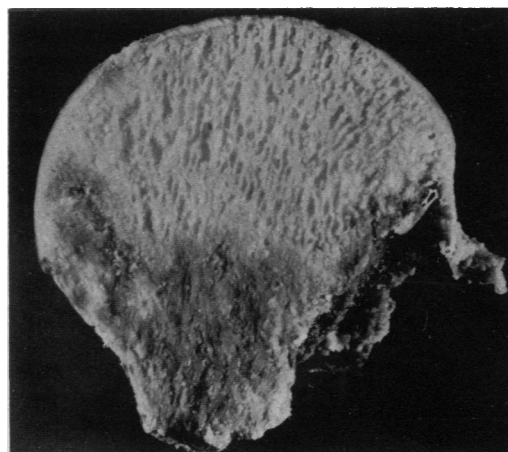


Figure 1: Cut surface of a femoral head removed after subcapital fracture showing the well defined necrotic region affecting most of the head as it appears in stage I subchondral avascular necrosis.

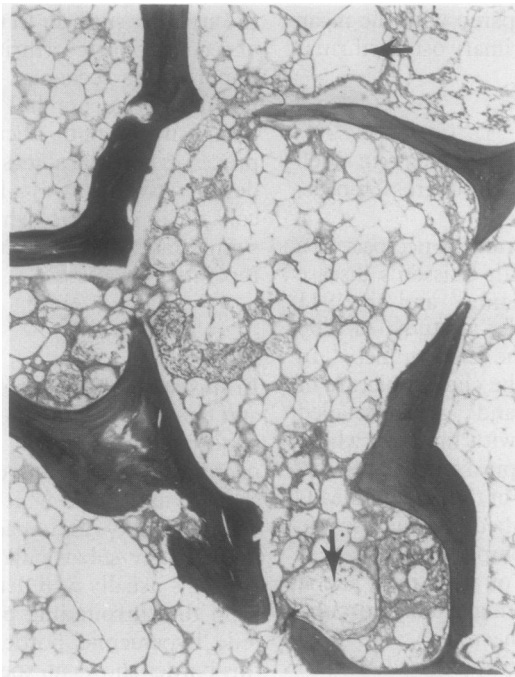


Figure 2: Necrotic bone and marrow showing the granular appearance of the marrow and the ghosts of necrotic fat cells. The cysts (arrows) result from the disintegration of fat cells. (Haematoxylin and eosin.)

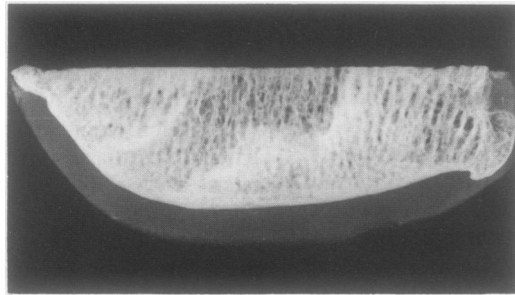


Figure 3: A specimen radiograph of the femoral condyle of a knee joint with stage II subchondral avascular necrosis showing the encroaching sclerosis which represents the 'creeping substitution' occurring at the periphery of the relatively lucent necrotic zone.

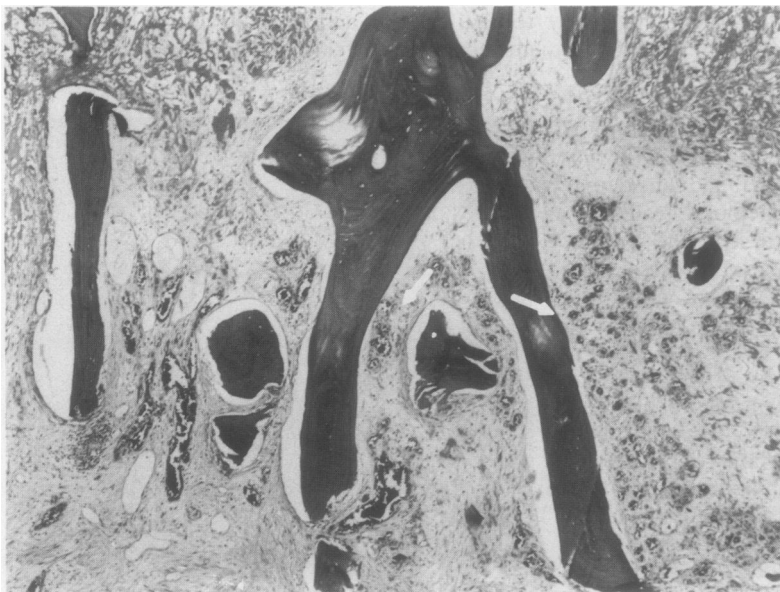


Figure 4: The advancing front of vascular granulation tissue (arrow) progressing into the necrotic zone at the top. (Haematoxylin and eosin.)

increased osteoclastic activity and an intertrabecular infiltrate of proliferating fibroblasts and capillaries. This zone corresponds to the thin red rim seen in the gross specimen. Beyond this hypervascular zone the bone and bone marrow are unchanged by the necrotising process and reflect the state of the marrow before the necrotising event.

STAGE II

As in stage I, the overall shape of the bone is preserved and the articular surface is intact. On sectioning, however, a rim of bony sclerosis can be seen at the periphery of the necrotic zone at the boundary between the necrotic zone and the unaffected marrow. This feature is best seen on specimen radiographs (fig 3). The central region of necrosis is unchanged from stage I, but the hyperaemic zone is generally thicker and may now contain a mixture of tan and white tissue.

On microscopic examination an advancing front of granulation tissue composed of lipid-laden macrophages, proliferating fibroblasts, and capillaries can be seen at the periphery and extends into the central region of the necrotic zone (fig 4). Following closely behind this 'clean up' front is a second front composed of osteoblasts depositing a layer of new bone on the pre-existing dead trabecular bone. Following this second front at a variable distance, limited amounts of both the old dead, and new living bone are being removed by osteoclasts.

The overall effect of these climbing processes is to remove the necrotic marrow and bone while maintaining the structural integrity of the bone. This series of processes is what has been called creeping substitution by Plemister.²⁴ The increased osteoblastic activity and the layer of new bone give rise to the clinical radiographic appearances of bony sclerosis and to the increased uptake of the radioactive technetium diphosphonate isotope on a bone scan.

STAGE III

Alteration of the shape of the bone is first encountered in this stage. This is the result of collapse in the necrotic region and may be apparent on external examination of the bone as a buckling or fragmentation of the articular cartilage (fig 5).

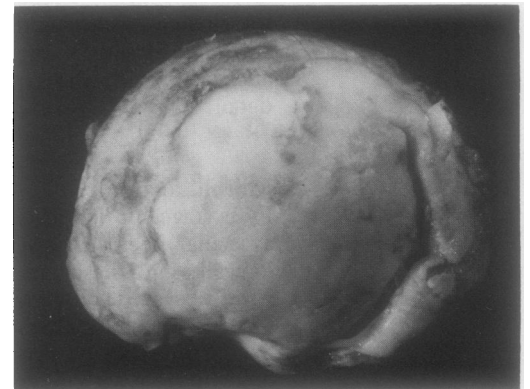


Figure 5: Buckling in the articular cartilage seen at the periphery of the collapsed segment in a humeral head with stage III subchondral avascular necrosis.

On cut section it can be seen that the reason for collapse is fracture of trabecular bone with associated fracture of the end-plate itself (fig 6). Fracture of the trabecula occurs either just below the bony end-plate, deep within the necrotic region, or on the necrotic side of the advancing sclerosis in the reparative front.

The fracture of the trabecula may result from any one of three causes: (a) the cumulative effect of microfractures induced by fatigue within the necrotic zone; (b) weakness of trabeculae in the reparative front due to osteoclastic activity; or (c) focal concentrations of stress at the junctions between the thickened sclerotic trabecula of the reparative zone and the necrotic trabecula. This last cause may be

Figure 6: A cut section through the humeral head shown in fig 5 demonstrating the fracture in the necrotic bone immediately beneath the collapsed articular surface. The fracture line corresponds to the radiolucent line known as the 'crescent sign' seen on clinical radiographs.

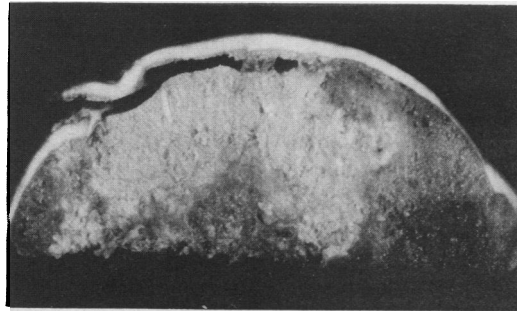


Figure 7: Cut surface of a femoral head with stage IV subchondral avascular necrosis showing the marked destruction which occurs and demonstrating a deep saddle shaped deformity which results from loss of the necrotic segment.

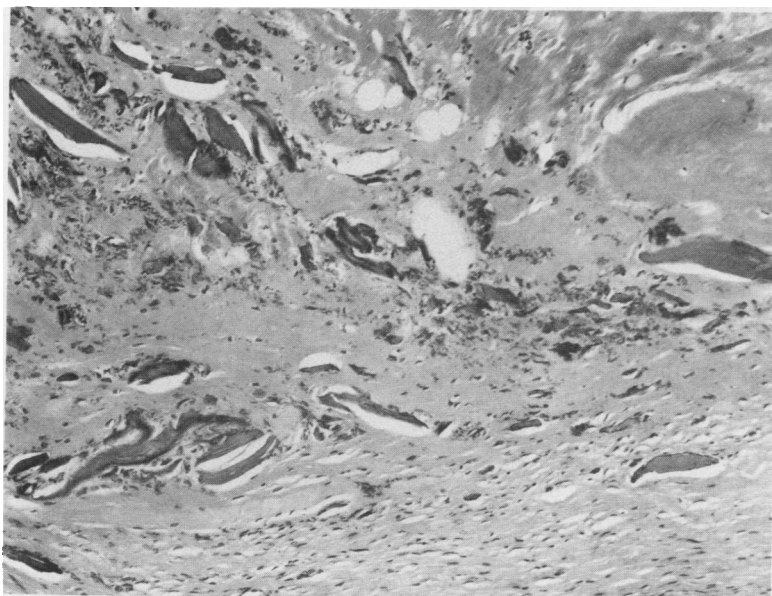
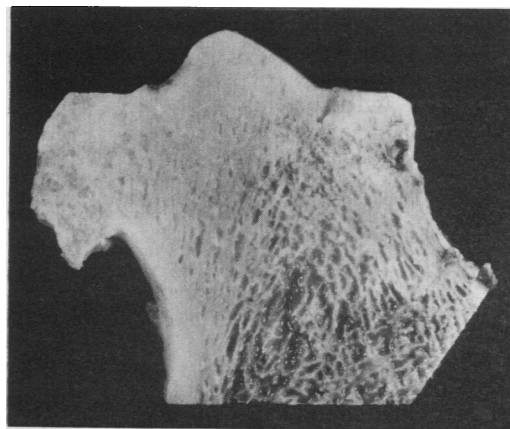


Figure 8: Synovium showing the bony and cartilaginous detritus which may accumulate in stage IV subchondral avascular necrosis.

most important in deep fractures and result from the bioengineering concept of 'stress risers'.³⁴

The linear fracture beneath the end-plate corresponds to the radiolucent zone, referred to as the 'crescent sign', seen on clinical radiographs.^{34 35}

Microscopically, the fractured trabecula in the necrotic region appears as fragments of pulverised bony and cartilaginous detritus. The overlying cartilage may still appear viable. Fractures within the reparative zone have an abundance of fibrous tissue, cartilaginous tissue, and reactive woven bone and have the usual appearance of un-united, unstable fractures elsewhere in the skeleton.

STAGE IV

The major feature of this stage is the appearance of morphological changes usually associated with osteoarthritis. Depending on the degree of the osteoarthritic changes, it may no longer be possible to recognise the initial events as those of subchondral avascular necrosis on the clinical radiographs. In most cases, however, there is sufficient evidence on gross and microscopic examination to allow proper diagnosis.

In general, as best seen in the femoral head, formation of osteophytes is not pronounced and the areas of cartilaginous erosion and bony eburnation surround the collapsed segment. Because of the collapse of the infarcted segment fragmented cartilage may persist in this region. When the changes of osteoarthritis are marked the only clue that the initial event might have been subchondral avascular necrosis is that the femoral head has a deep, saddle shaped deformity (fig 7).

The cut surface in this stage of subchondral avascular necrosis may show residual fragments of articular cartilage and dense fibrous connective tissue in the infarcted area, surrounded at the surface by a margin of densely sclerotic bone representing the eburnated articular surface. In markedly destructive cases the 'articular surface' may be composed of pulverised bony detritus.

Microscopic examination of less distorted specimens shows fragments of viable or necrotic cartilage on or within a layer of fibrous and cartilaginous tissue, which may include granulation tissue and reactive woven bone. The surrounding eburnated articular surfaces are seen microscopically as smooth surfaces overlying densely sclerotic lamellar and occasionally woven bone.

In more advanced cases two useful clues to the diagnosis of subchondral avascular necrosis may be the absence of clearly eburnated bone at the articular surface and the presence of bony and cartilaginous debris in the accompanying synovial and capsular tissue (fig 8).

BIOCHEMICAL ASPECTS OF THE NECROTIC ZONE

In an effort to characterise further the necrotic region of subchondral avascular necrosis the tissue lipids in 18 femoral heads resected for this necrosis have been studied.³⁶ The total lipids in the necrotic region were increased in compari-

son with both the non-necrotic regions of the same femoral head and other femoral heads without evidence of necrosis. The cholesterol content was higher in the necrotic regions than in the non-necrotic regions of the same femoral head, but both were higher than in seven normal control specimens and four osteoarthritic specimens without evidence of necrosis. Interestingly, the greatest increases in the cholesterol content were encountered in those patients with histories of combined use of steroids and alcohol. The cholesterol content correlated ($r=0.82$) with the proportion of necrotic tissue in the specimen and may either contribute to cell death by altering membrane metabolism or might have been released from the cell as a consequence of cell death.

Imaging modalities

TYPES

The current armamentarium used in the radiographic diagnosis of subchondral avascular necrosis includes four main imaging modalities: plain radiographs, radionuclide scintigraphy, computed tomography, and magnetic resonance imaging. Each has contributed to our understanding of the causes and progression of subchondral avascular necrosis and its associated complications—most notably, arthritis. As is the case with all advances in medical technology, the later modalities have been promoted as replacements for their predecessors in the diagnosis of many conditions in general and subchondral avascular necrosis in particular. It has been found, however, that none of the newer methods is infallible, and a combination of techniques is still often necessary.

PLAIN RADIOGRAPHS

The natural contrast afforded by the mineral in bone matrix makes the plain radiograph readily applicable to the diagnosis of bone disease. Because of its ability to show structural alterations the plain radiograph can identify joints affected by subchondral avascular necrosis when the reparative processes are well developed. Plain radiographs are limited, however, by an inability to show the early changes of the disease at a time when therapeutic intervention has the greatest chance to prevent development of arthritis and other complications—that is, in stage I where the plain radiographs are normal.

The earliest plain radiographic finding in an end of a bone affected by subchondral avascular necrosis is the presence of a poorly defined region of sclerosis, which does not generally reach to the subchondral end-plate. The appearance of this sclerosis corresponds to the deposition of bone in the presence of creeping substitution during stage II. Over time this sclerosis becomes well developed and reaches the end-plate. Because the repair process proceeds from the periphery in contact with surviving bone marrow in three dimensional space the sclerosis seen on the plain (two dimensional) radiograph tends to overestimate the extent of repair.

In stage III, where collapse has occurred, the

plain radiograph shows the alteration in the shape of the joint. The characteristic finding of the crescent sign, seen best in the 'frog lateral' view of the femoral head, is easily recognisable in plain radiographs (fig 9).³⁵ Similar evidence of collapse is also apparent in other affected joints. After collapse in stage IV, changes of osteoarthritis may supervene and obscure or even obliterate the features characteristic of subchondral avascular necrosis (fig 10).

In symptomatic subchondral avascular necrosis, if the pain is sufficient to cause

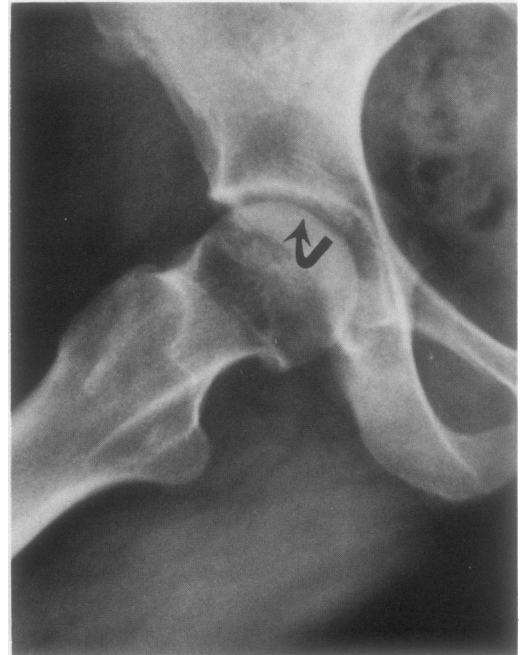


Figure 9: Plain radiograph of a hip in the 'frog lateral' view showing the radiolucent line ('crescent sign'—arrow) representing the subchondral fracture with deformity of the surface in stage III subchondral avascular necrosis.

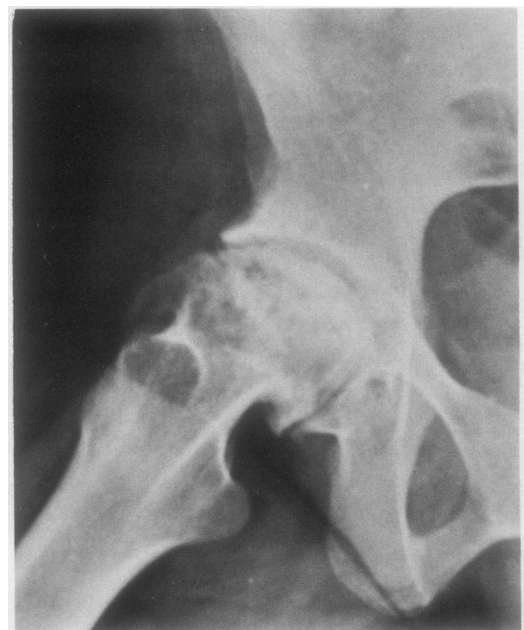

Figure 10: Plain radiograph of a femoral head with stage IV subchondral avascular necrosis showing the destructive arthritis with osteophytes and sclerosis affecting both sides of the joint mimicking osteoarthritis.

reduced use of the joint or extremity, the bone around the necrotic region may undergo disuse osteoporosis, causing the necrotic region to appear dense.

RADIONUCLIDE SCINTIGRAPHY (BONE SCAN)

The bone scan is used in the diagnosis of subchondral avascular necrosis because of its ability to identify regions in the skeleton where bone deposition and mineralisation are occurring. Early in stage II the presence of an incorporated radioactive isotope can be detected well before the plain radiographs show increased sclerosis (fig 11).³⁷ An important feature of the bone scan is that it is capable of indicating multiple affected sites without increasing the exposure of the patient to ionising radiation.

COMPUTED TOMOGRAPHY (CT)

One of the advantages of the CT scan over plain radiographs is its ability to obtain 'slices' through the bone, thereby reducing or eliminating overlap and providing a clearer image of the necrotic zone without interference from surrounding structures such as soft tissues and regional cortical bone (fig 12). The changes seen on the CT scan parallel those seen with plain radiographs and include progressive peripheral sclerosis of stage II and, when it occurs, the crescent sign of stage III. The ability to obtain slices provides a better estimate of the extent of repair within the necrotic region.

MAGNETIC RESONANCE IMAGING (MRI)

The three imaging modalities just discussed are hindered by their inability to identify the earliest stage of subchondral avascular necrosis. They can only identify the reparative processes after they are established. Magnetic resonance imaging offers the considerable advantage of being able to identify chemical changes in necrotic bone marrow well before changes in the bone can be detected by the other methods.³⁸

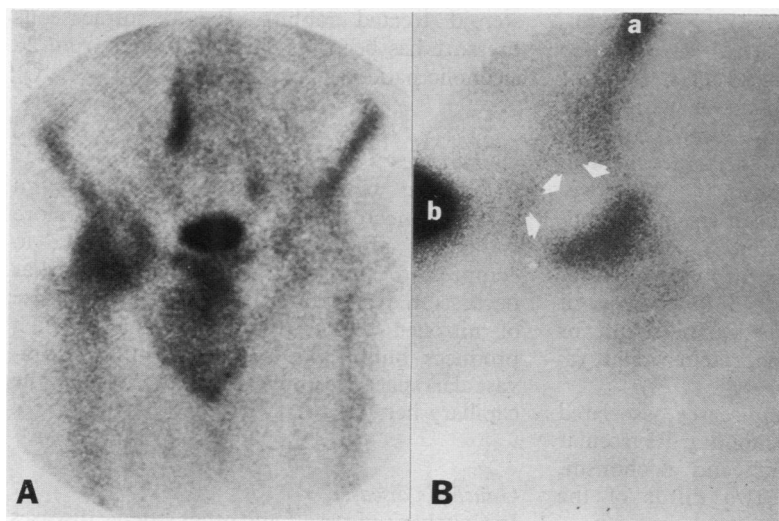


Figure 11: Bone scans showing the increased uptake of radionuclide in the femoral head in stage I subchondral avascular necrosis (A). The uptake is present only on one side of the right hip joint, which distinguishes this condition from osteoarthritis. (B) The central necrotic zone has no uptake in early, large lesions. b = urinary bladder; a = anterior iliac wing; arrows = joint margin of femoral head.

It is also useful in showing other clinically silent foci of subchondral avascular necrosis in patients who already have a clinically evident focus.

The earliest finding of subchondral avascular necrosis as shown by MRI is a decrease in the usual high signal obtained by marrow fat on the T1 weighted image. The region appears darker on the image when compared with the surrounding marrow (fig 13). This decreased signal results from the chemical alteration in the fat that results in the opaque, yellow, and soapy appearance seen on gross examination.

Magnetic resonance imaging shows only variations in signal intensity and it remains incumbent upon the radiologist to keep in mind that any condition affecting the marrow may change the signal intensity simply by replacing or displacing marrow fat. In some conditions, such as sickle cell disease and Gaucher's disease, the marrow signal may already be reduced and thus make it difficult to evaluate the image.

Aetiology and pathogenesis

Regardless of any predisposing conditions, the final cause of subchondral avascular necrosis is the loss of adequate perfusion of blood in the articular ends of bones.

ANATOMICAL FACTORS

Several anatomical features of the ends of bones

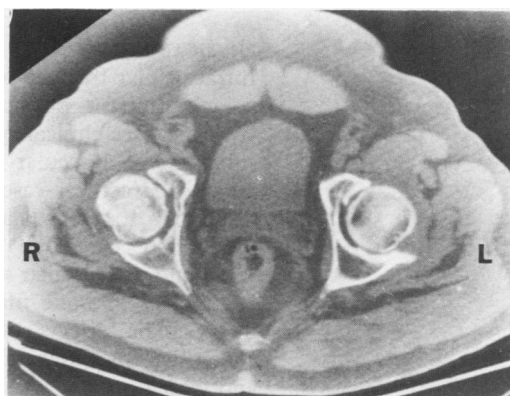


Figure 12: A computed tomography (CT) scan showing the irregular contour of the right femoral head after collapse of the articular surface in stage III subchondral avascular necrosis. The radiolucent line beneath the collapsed cartilage is the CT representation of the 'crescent sign' seen on plain radiographs.

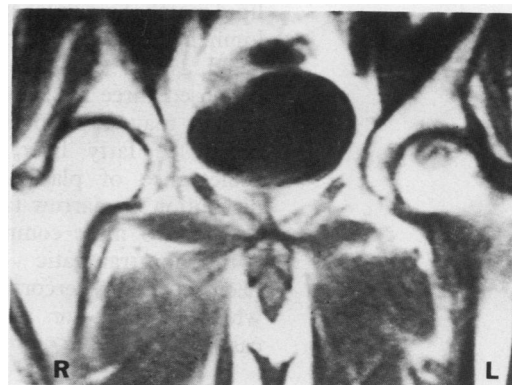


Figure 13: A magnetic resonance imaging scan showing the decreased signal in the T1 weighted image in the necrotic region of the left femoral head.

render them susceptible to compromise in their blood supply: (a) subchondral bone has a limited collateral circulation, particularly on the convex sides of joints^{39 40}; (b) the perfusion pressure and blood flow of epiphyses, and that of fatty marrow, in comparison with red diaphyseal marrow, is low, making the subchondral region susceptible to decreased perfusion pressures in much the same way as in other sites, particularly in the endocardium and 'watershed' regions of the gastrointestinal tract⁴¹; (c) finally, and possibly most importantly, bone, unlike the soft tissue and organs of the body, is rigid and non-distensible, and can neither expand nor collapse in order to assist in the maintenance of adequate perfusion pressures.

As is the case for necrosis elsewhere, necrosis of subchondral bone results from either an intravascular or an extravascular disturbance.

Examples of possible intravascular disturbances are narrowing of arteries and arterioles, resulting from many primary vascular diseases, embolism, thrombosis, increased viscosity of the blood, and haemoglobinopathies. Extravascular causes of disturbed perfusion consist of those conditions which infiltrate the marrow space and generally increase interstitial pressure, such as Gaucher's disease and other lipid storage diseases, infection, hypercortisonism, alcoholism, and both benign and malignant tumours, all of which result in increased venous pressure.

PHYSICAL INJURY

Intracapsular fracture of the femoral neck with its concomitant physical disruption of blood vessels causes clinical symptoms resulting from subchondral avascular necrosis in upwards of 20% of fracture cases with posterior dislocation.⁴² Extracapsular fractures of the proximal femur are much less likely to result in subchondral avascular necrosis.⁴³

Necrosis of bone may also result from the direct toxic effects of high dose radiation, chemotherapy, thermal and electrical injury, and freezing.

LIPID METABOLISM AND FAT EMBOLISM

Approximately 90% of patients with non-traumatic bone necrosis have been shown to have disorders with associated disturbances in lipid metabolism or fat embolism.^{44 45} The development of fat emboli has been strongly implicated as the causative factor.^{46 47} Jones has proposed three mechanisms through which fat emboli may develop and lead to necrosis of bone: (a) fatty liver; (b) destabilisation or coalescence of plasma lipoproteins; and (c) disruption of marrow fat.⁴⁸

The two most common diseases associated with non-traumatic subchondral avascular necrosis are hypercortisolism and alcoholism, which account for about two thirds of the cases.⁴⁵

Hypercortisolism

The evidence linking hypercortisolism, whether

as Cushing's disease or as a result of steroid treatment, to subchondral avascular necrosis is persuasive, though it is likely that more than one mechanism is involved. Studies in steroid treated rabbits have shown the presence of hyperlipaemia, fatty liver, and fat emboli in the lungs and bones.⁴⁸ These findings indicate a major alteration in systemic fat metabolism and suggest that all of the mechanisms proposed by Jones in the development of fat embolism might play a part. In addition to these mechanisms, Wang *et al* have shown increased size of marrow fat cells in steroid treated rabbits.⁴⁹ This in turn was associated with increased intraosseous pressure and decreased blood flow. It has been suggested by Sweet and Madewell that necrosis may extend or be episodic during steroid treatment, and histological evidence of recurring necrosis—that is, evidence of death in previously healing areas, was reported in 83% of the femoral heads that they examined.⁵⁰

Subchondral avascular necrosis complicates systemic lupus erythematosus in approximately 5% of patients and is believed to be associated mainly with steroid treatment.⁵¹

Alcoholism

In alcoholic patients the presence of a fatty liver may act as a continuous source of subclinical fat embolism.⁵ In addition, fat may be released by blunt trauma to the right upper quadrant, and focal liver necrosis may also contribute to embolisation.

INTRAOSSEOUS HYPERTENSION

The importance of increased intraosseous pressure has been emphasised by Zizic *et al*.⁵² In patients in whom they measured intraosseous pressures a raised level was predictive of osteonecrosis in 50% of cases, whereas only rarely did patients with normal pressure develop osteonecrosis. As already mentioned, increased intraosseous pressure associated with increased size of marrow fat cells may be significant in experimental subchondral avascular necrosis in steroid treated rabbits. Raised intraosseous pressure has been reported in 38 hips from 26 alcoholic patients.⁵³

Dysbarism

In contrast with other causes of subchondral avascular necrosis, the humeral head is more commonly affected with necrosis owing to compressed air.⁵⁴ Subchondral avascular necrosis in dysbarism is the result of the release of nitrogen dissolved in the tissues, which produces bubbles in the extracellular, extravascular space, leading to compression of the capillary network.

Gaucher's disease

In Gaucher's disease¹¹ and other storage diseases which replace the normal marrow constituents accumulated storage cells pack the marrow space and constrict the vascular network with subsequent compromise in venous return.

Sickle cell disease

In sickle cell disease occlusion of the small vessels probably occurs because of the increased viscosity of the blood caused by clumping of the affected red cells following hypoxia.¹⁰

Clinical presentation

In an extensive study of patients seen at our institution⁵⁵ the primary presenting complaint in subchondral avascular necrosis of the hip was pain experienced on weight bearing and, in two thirds of the cases, also while at rest. In most respects the symptoms of subchondral avascular necrosis and osteoarthritis are similar, though in subchondral avascular necrosis the functional disability, as assessed in terms of difficulty in walking and performing activities of daily living, is likely to be somewhat less than that experienced with primary osteoarthritis. Most patients with subchondral avascular necrosis have a hard time walking upstairs and putting on their shoes, however.

The mode of onset of the symptoms is rather different from that seen with osteoarthritis. Most patients with subchondral avascular necrosis report a sudden onset of acute pain, whereas in osteoarthritis the onset is usually more gradual. The onset is considered sudden if the patient can relate it to a specific incidence—such as while mowing the lawn, or arising from a chair—or specifically remembers that the symptoms started during a particular week or month.

The statistics for duration of symptoms also show a marked disparity between subchondral avascular necrosis and osteoarthritis. Before surgical treatment patients with subchondral avascular necrosis of the hip, in our experience, had been symptomatic for an average of 3.6 years compared with 5.8 years for primary osteoarthritis, 9.3 years for rheumatoid arthritis, and 13.9 years for secondary osteoarthritis.

Patients with subchondral avascular necrosis generally have restriction of all hip movements but to a much lesser extent than is found in osteoarthritis. The limiting factor in subchondral avascular necrosis seems to be pain rather than deformity of the joint surfaces. In our experience just over half of the affected subject show a positive Trendelenburg's test—that is, when the patient stands on one leg using the affected side the pelvis on the opposite side falls rather than rising. In Zinn's series of 40 patients 29, or 59%, had a positive Trendelenburg's test.

There are as yet no definite clinical laboratory findings which indicate that a patient has subchondral avascular necrosis. In 1975 Mielants *et al*, reporting on the relation between subchondral avascular necrosis and lipid metabolism, showed that there was a significant increase in total serum lipid and triglyceride concentrations in these patients.⁵⁶ We have not been able to confirm these findings in our laboratory, however.

Treatment

Treatment of subchondral avascular necrosis of

the femoral head by core biopsy decompression has been proposed.^{57 58} In stage I and stage II subchondral avascular necrosis—that is, before collapse, it has been shown that core biopsy alone resulted in good long term results in 90% of the patients.⁵³ Another study reported that half the patients treated in this way did not require any further treatment.⁵⁹ Others have reported a series of patients with early subchondral avascular necrosis of the hip who have been treated by electrical stimulation and grafting alone.⁶⁰ Although no statistically significant difference was noted with the addition of the electrical stimulation, the authors remain hopeful that it will help and persist with this form of treatment.

In subchondral avascular necrosis of the knee it is generally thought that patients with typical symptoms, positive bone scans but no lesions evident on radiological examination (stages I–II), are not benefited by surgery.⁶¹ Instead, conservative treatment using protected weight bearing, and analgesics is recommended. These patients are likely to do well, but they should be followed up carefully by serial x ray examinations. For disease in stages III and IV and for large lesions, whether symptomatic or asymptomatic, with an associated angular deformity of the knee, tibial osteotomy is advocated. Total knee replacement is generally only advocated for patients with symptomatic stage III or IV disease who are less active.

Certainly, total joint replacement should be used with care. In a study from our institution there was a 37% overall failure rate in total hip replacements done for subchondral avascular necrosis as compared with a 10% failure rate for those replacements done for other causes.⁶² In that study the highest failure rate was seen among those patients with sickle cell disease, all of whom experienced failure of their implants. The next highest failure rate was observed in alcoholics (67%) and then in those patients who had steroid treatment (30%). The cases which had no known predisposing condition had a much lower failure rate (11%).

Summary

- (1) Subchondral avascular necrosis is an important cause of joint pain and disability and accounts for upwards of 20% of total hip replacements done in our hospital.
- (2) Early diagnosis may be made with the aid of magnetic resonance imaging and radioactive isotope studies.
- (3) Although the signs and symptoms are similar to those of osteoarthritis, there are significant differences—namely, (a) a history of sudden onset of pain, present in more than half the patients; (b) a younger age group; (c) a shorter duration of symptoms at time of surgery; (d) clinically the limiting factor is pain rather than actual joint deformity to account for restriction of movement; (e) a high incidence of multiple sites of involvement.
- (4) The disease is commonly associated with steroid treatment or alcohol abuse. Although many other causes are recognised, they are rare in Western urban practice.

(5) Patients with stage I-II subchondral avascular necrosis, especially of the knee, are better treated conservatively.

(6) Surgical treatment gives less satisfactory results than the treatment of osteoarthritis by similar modalities.

- 1 Bullough P G. The pathology of degenerative change in the hip: the microscopic changes. In: Reynolds D, Freeman M eds. *Osteoarthritis in the young hip*. New York: Churchill Livingstone, 1989.
- 2 Cushner F D, Friedman R J. Osteonecrosis of the femoral head. *Orthopedic Review* 1988; 17: 29-34.
- 3 McCarthy E. Aseptic necrosis of bone. *Clin Orthop* 1982; 168: 216-21.
- 4 Mankin H L, Brower T D. Bilateral idiopathic aseptic necrosis of the femur in adults—Chandler's disease. *Bulletin of the Hospital for Joint Diseases* 1962; 23: 42-57.
- 5 Jones J P. Alcoholism, hypercortisolism, fat embolism and osseous avascular necrosis. In: Zinn W M, ed. *Idiopathic ischemic necrosis of the femoral head in adults*. Stuttgart: Thieme, 1971: 112-32.
- 6 Hungerford D S, Zizic T M. Alcoholism associated ischemic necrosis of the femoral head: early diagnosis and treatment. *Clin Orthop* 1978; 130: 144-53.
- 7 Axhausen G. Die Nekrose des proximalen Bruchstuecks beim Schenkelhalsbruch und ihre Bedeutung fuer das Huftgelenk. *Langenbecks Archiv fur Klinische Chirurgie* 1922; 120: 325-46.
- 8 Jones J P, Jameson R M, Engleman E P. Alcoholism, fat embolism and avascular necrosis. *J Bone Joint Surg [Am]* 1968; 50: 1065.
- 9 Solomon L. Drug-induced arthropathy and necrosis of the femoral head. *J Bone Joint Surg [Br]* 1973; 55: 246-61.
- 10 Sennara H, Gorry F. Orthopedic aspects of sickle cell anemia and allied hemoglobinopathies. *Clin Orthop* 1978; 130: 154-7.
- 11 Herman G, Goldblatt J, Levy R N, Goldsmith S J, Desnick R J, Grabowski G A. Gaucher's disease type I: assessment of bone involvement by CT and scintigraphy. *American Journal of Rheumatology* 1986; 147: 943-8.
- 12 Turek S L. *Orthopaedic principles and their applications*. 2nd ed. Philadelphia: Lippincott, 1984.
- 13 Volle K. *L'osteonecrose idiopathique de la tete femoral chez l'adulte*. Lyons: Rey, 1963.
- 14 Patterson R J, Bickel W H, Dahlin D C. Idiopathic avascular necrosis of the head of the femur: a study of 52 cases. *J Bone Joint Surg [Am]* 1964; 46: 267-82.
- 15 Merle d'Aubigne R, Postel M, Mazabrand A, Massias P, Gueguen J. Idiopathic necrosis of the femoral head in adults. *J Bone Joint Surg [Br]* 1965; 47: 612-33.
- 16 Hastings D E, MacNab I. Spontaneous avascular necrosis of the femoral head. A clinical and pathological review. *Can J Surg* 1965; 8: 68-83.
- 17 McCollum D E, Matthews R S, O'Neill M T. Aseptic necrosis of the femoral head. Associated diseases and evaluation of treatment. *South Med J* 1970; 63: 241-53.
- 18 Zinn W M. Clinical picture and laboratory findings. In: Zinn W M, ed. *Idiopathic ischaemic necrosis of the femoral head in adults*. Stuttgart: Thieme, 1971: 12.
- 19 Paget J. Mortification. *Lecture on Surgical Pathology*. 1860; lecture XIX: 301-2.
- 20 Twynham G E. A case of Caisson disease. *Br Med J* 1888; ii: 190-1.
- 21 Bornstein A, Plate E. Ueber chronische Gelenkveraenderungen entstanden durch Pressluftekrankung. *Fortschritte auf dem Gebiete der Roentgenstrahlen* 1911; 18: 197-206.
- 22 Phemister D B. Necrotic bone and the subsequent changes which it undergoes. *JAMA* 1915; 64: 211-6.
- 23 Phemister D B. Recognition of dead bone based on pathological and X-ray studies. *Ann Surg* 1920; 72: 466-85. (Read to American Surgical Association 5 May 1920.)
- 24 Phemister D B. Repair of bone in presence of aseptic necrosis arising from fractures, transplantations and vascular obstruction. *J Bone Joint Surg [Am]* 1930; 12: 769-87.
- 25 Pietrogrande V, Mastromarino R. Osteopatia da prolungata trattamento cortisonico. *Ortop Traum Appar Mat* 1957; 25: 791-810.
- 26 Mandel S H, Freeman L M. Avascular necrosis of bone in Cushing's disease. *Radiology* 1964; 83: 1068-70.
- 27 Creuss R L, Blennerhassett J, MacDonald F R, MacLean L D, Dossetor J. Aseptic necrosis following renal transplantation. *J Bone Joint Surg [Am]* 1968; 50: 1577-89.
- 28 Catto M A. Histological study of avascular necrosis of the femoral head after transcervical fracture. *J Bone Joint Surg [Br]* 1965; 47: 749-76.
- 29 Catto M. The histological appearance of late segmental collapse of the femoral head after transcervical fracture. *J Bone Joint Surg [Br]* 1965; 47: 777-91.
- 30 Ficat R P, Arlet J. *Ischemia and necrosis of bone*. Baltimore: Williams and Wilkins, 1980.
- 31 Glimcher M J, Kenzora J E. The biology of osteonecrosis of the human femoral head and its clinical implications: Part I. *Clin Orthop* 1979; 138: 284-309.
- 32 Glimcher M J, Kenzora J E. The biology of osteonecrosis of the human femoral head and its clinical implications: Part II. *Clin Orthop* 1979; 139: 283-312.
- 33 Glimcher M J, Kenzora J E. The biology of osteonecrosis of the human femoral head and its clinical implications: Part III. *Clin Orthop* 1979; 140: 273-312.
- 34 Kenzora J E, Glimcher M J. Pathogenesis of idiopathic osteonecrosis: the ubiquitous crescent sign. *Orthop Clin North Am* 1985; 16: 681-96.
- 35 Norman A, Bullough P G. The radiolucent crescent line: an early diagnostic sign of avascular necrosis of the femoral head. *Bull Hosp Jt Dis Orthop Inst* 1963; 24: 99-104.
- 36 Boskey A L, Raggio C L, Bullough P, Kinnett J G. Changes in the bone tissue lipids in persons with steroid and alcohol induced osteonecrosis. *Clin Orthop* 1983; 172: 289-95.
- 37 Bonnarens F, Hernandez A, D'Ambrosia R. Bone scintigraphic changes in osteonecrosis of the femoral head. *Orthop Clin North Am* 1985; 16: 697-703.
- 38 Jergesen H E, Heller M, Genant H K. Magnetic resonance imaging in osteonecrosis of the femoral head. *Orthop Clin North Am* 1985; 16: 705-16.
- 39 Sevitt S, Thompson R G. The distribution and anastomoses of arteries supplying the head and neck of the femur. *J Bone Joint Surg [Br]* 1965; 47: 560-73.
- 40 Brookes M. *The blood supply of bone*. New York: Appleton-Century-Crofts; 1971: 193.
- 41 Brookes M. *The blood supply of bone*. New York: Appleton-Century-Crofts; 1971: 81.
- 42 Roeder L F, DeLee J C. Femoral head fractures associated with posterior hip dislocations. *Clin Orthop* 1980; 147: 121-30.
- 43 Mann R L. Avascular necrosis of the femoral head following intertrochanteric fracture. *Clin Orthop* 1973; 92: 108-15.
- 44 Jacobs B. Epidemiology of traumatic and non-traumatic osteonecrosis. *Clin Orthop* 1978; 130: 51-67.
- 45 Jones J P. Osteonecrosis. In: McCarty D J, ed. *Arthritis and allied conditions*. 11th ed. Philadelphia: Lea and Febiger, 1989: 1546.
- 46 Jones J P, Engleman E P, Steinbach H L, Murray W R, Rambo O N. Fat embolization as a possible mechanism producing avascular necrosis. *Arthritis Rheum* 1965; 8: 449.
- 47 Jones J P, Sakovich L, Anderson C E. Experimentally produced osteonecrosis as a result of fat embolism. In: Beckman E L, Elliot D H, Smith E M, eds. *Dysbarism-related osteonecrosis*. Washington: Dept HEW, 1974: 117-32.
- 48 Jones J P. Fat embolism and osteonecrosis. *Orthop Clin North Am* 1985; 16: 595-633.
- 49 Wang G J, Sweet D E, Reger S I, Thompson R C. Fat cell changes as a mechanism of vascular necrosis of the femoral head in cortisone-treated rabbits. *J Bone Joint Surg [Am]* 1977; 59: 729-35.
- 50 Sweet D E, Madewell J E. Pathogenesis of osteonecrosis. In: Resnick D, Niwayama G, eds. *Diagnosis of bone and joint disorders*. Vol 3. Philadelphia: Saunders, 1981: 2781-831.
- 51 DuBois E L. *Lupus erythematosus*. 2nd ed. Los Angeles: USC Press, 1974: 332-42.
- 52 Zizic T M, Marcoux C, Hungerford D S, Stevens M B. Predictive value of hemodynamic studies in ischemic necrosis of bone [Abstract]. *Arthritis Rheum* 1983; 26: S37.
- 53 Hungerford D S, Zizic T M. Alcoholism associated ischaemic necrosis of the femoral head. *Clin Orthop* 1978; 130: 144-53.
- 54 Decompression Sickness Panel, Medical Research Council. Aseptic bone necrosis in commercial divers. *Lancet* 1981; ii: 384-8.
- 55 Fitzpatrick D J. Avascular necrosis of the femoral head: its natural history and pathology. Dublin: Trinity College, 1977. (Thesis.)
- 56 Mielants H, Veyes E M, De Bussere A, Van der Jeught J. Avascular necrosis and its relation to lipid and purine metabolism. *J Rheumatol* 1975; 2: 430-6.
- 57 Ficat R P. Treatment of avascular necrosis of the femoral head. In: *Proceedings of the eleventh open scientific meeting of the Hip Society*. St Louis: Mosby, 1983: 279-95.
- 58 Hungerford D S. Bone marrow pressure, venography and core decompression in ischaemic necrosis of the femoral head. In: *Proceedings of the seventh open scientific meeting of the Hip Society*. St Louis: Mosby, 1979: 218-37.
- 59 Kenzora J E. Treatment of idiopathic osteonecrosis: the current philosophy and rationale. *Orthop Clin North Am* 1985; 16: 717-25.
- 60 Steinberg M E, Brighton C T, Hayken G B, Tooze S E, Steinberg D R. Electrical stimulation in the treatment of osteonecrosis of the femoral head. *Orthop Clin North Am* 1985; 16: 747-56.
- 61 Lotke P A, Ecker M L. Osteonecrosis of the knee. *Orthop Clin North Am* 1985; 16: 797-808.
- 62 Cornell C N, Salvati E, Pellicci P M. Long-term follow-up of total hip replacement in patients with osteonecrosis. *Orthop Clin North Am* 1985; 16: 757-69.