

Lymphoedema of the limbs as an extra-articular feature of rheumatoid arthritis

J E Dacre, D L Scott, E C Huskisson

Abstract

Seven patients with lymphoedema of the hands and arms, an unusual extra-articular feature of rheumatoid arthritis, are described. In all cases the lymphoedema persisted throughout follow up—in one case for more than five years—and was resistant to treatment with slow acting drugs, steroids, or cytotoxic agents. There was no correlation with severity of disease. It is concluded that the lymphoedema in these patients may be associated with reduced numbers of lymphatic vessels; increased capillary permeability or abnormal fibrinolysis may also be contributory factors. Conservative management of such patients is recommended.

had no neurological symptoms. Examination showed bilateral lymphoedema of the hands that extended to his wrists and inflammatory arthritis of the metacarpophalangeal joints. He had previously had polymyalgia rheumatica, which had been treated with steroids. He had concomitant diabetes mellitus and ischaemic heart disease. Tests for rheumatoid factor were negative and his erythrocyte sedimentation rate (ESR) was 35 mm/first hour. Radiographs of his hands showed an erosive arthritis. Seronegative RA was diagnosed. He was treated with indomethacin and showed symptomatic improvement. The lymphoedema persisted. No other antirheumatic drugs were given.

Patients with rheumatoid arthritis (RA) characteristically present with painful swollen hands and feet due to synovitis of their small joints. Lymphoedema of the limbs can be an added complication in a small number of cases. Lymphoedema of the upper limbs was first reported in RA by Kalliomaki and Vastamaki in 1968.¹ Dudley Hart subsequently mentioned three cases in a review of the extra-articular features of RA.² Since then there have been three further reports,³⁻⁵ and altogether 16 patients have been described. We have seen seven patients with this complication and report their clinical course, together with a review of the published findings.

Case reports

A synopsis of the patients studied is given in table 1.

CASE 1

A 57 year old motor mechanic presented with painful swollen hands and prolonged morning stiffness which he had had for six weeks. He

CASE 2

A 52 year old photographer had a 10 year history of classic RA of polymyalgic onset. He had coexistent benign paraproteinaemia. He presented with a two year history of increased pain in his wrists and hands associated with diffuse swelling and considerable morning stiffness. Examination showed bilateral lymphoedema of hands and forearms in association with active synovitis and pronounced joint destruction. Tests for rheumatoid factor were positive; the ESR was 64 mm/first hour. Radiographs of his hands showed symmetrical erosive changes. Electrophoresis showed an IgM monoclonal gammopathy. There was no evidence of lymphoma or myeloma despite extensive investigation. Lymphangiography was undertaken with difficulty and showed no definite abnormality. He had previously been treated with gold and penicillamine with no alleviation of his symptoms. Subsequently treatment with hydroxychloroquine, prednisolone, and cyclophosphamide was unsuccessful. At the time of writing he was receiving sulphasalazine. The lymphoedema persists (figure), though it has shown some improvement.

Department of Rheumatology, St Bartholomew's and Homerton Hospitals, West Smithfield, London EC1A 7BE
J E Dacre
D L Scott
E C Huskisson

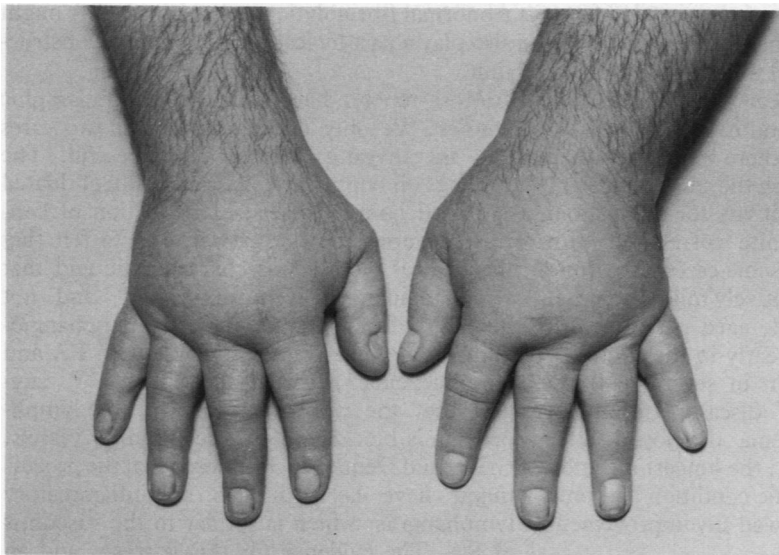
Correspondence to: Dr Dacre.

Accepted for publication 13 October 1989

Table 1 Synopsis of patients with lymphoedema studied

	Case No						
	1	2	3	4	5	6	7
Age in years when seen	57	52	44	51	45	62	54
Sex	M	M	M	F	F	M	F
Site of lymphoedema	Hands	Hands	Hands	Hands	Hands	Hands	Feet
Onset of lymphoedema after RA (years)	<1	8	1	<2	2	5	<1
Rheumatoid factor	Negative	Positive	Positive	Negative	Positive	Negative	Positive
Antinuclear antibody	Negative	Negative	Positive	Positive	NK	Negative	Negative
ESR	High	Very high	High	Low	High	High	High
Radiology	Erosions	Erosions	No erosions	Erosions	Erosions	Erosions	Erosions
Outcome	Minor improvement	Minor improvement	No change	No change	No change	No change	No change

NK=not known.



Hands of one rheumatoid patient with lymphoedema (case 2).

CASE 3

A 44 year old publican presented with 18 months of swollen stiff hands. He had some pain when first seen. This resolved, leaving persistent bilateral lymphoedema of both hands and wrists that extended to the left elbow. Tests for rheumatoid factor were initially negative but subsequently became positive. His ESR was 45 mm/first hour. Radiographs showed soft tissue swelling and periarticular osteoporosis without erosions. RA was diagnosed. Non-steroidal anti-inflammatory drugs were of minimal value, but he has not needed additional treatment. His lymphoedema persists.

CASE 4

A 51 year old woman with an 11 year history of classic RA developed painful swollen hands. Examination showed bilateral lymphoedema. She had previously been treated with levamisole, but had relapsed, and, at the time of writing, was currently controlled on auranofin. Her ESR was 10 mm/first hour and she was rheumatoid factor negative. Radiographs of her hands showed fusion of both wrists joints with erosions affecting the metacarpophalangeal joints. She also had atlantoaxial subluxation. The lymphoedema subsequently persisted for more than five years without regression.

CASE 5

A 45 year old woman with a 10 year history of classic RA presented with an eight year history of a swollen right hand. Examination showed

unilateral lymphoedema of the right hand with bilateral synovitis of the metacarpophalangeal joints. At presentation she was treated with azathioprine and has continued receiving that treatment. Her ESR was 50 mm/first hour; tests for rheumatoid factor were positive. Radiographs of her hands showed moderately severe erosive changes. The lymphoedema has been resistant to treatment.

CASE 6

A 62 year old greengrocer presented with three years of polyarthritis which was diagnosed as RA. Most peripheral joints were affected. He had had a history of Raynaud's phenomenon since the age of 16. At presentation he had pronounced lymphoedema of the left hand and forearm and the right hand. Radiography showed that this was an erosive arthritis. He was seronegative for rheumatoid factor and also negative for antinuclear antibodies. The ESR varied from 2 to 20 mm/first hour. A lymph-angiogram showed no abnormality. The arthritis went into remission with non-steroidal anti-inflammatory drugs alone but the lymphoedema of his hands has persisted.

CASE 7

A 54 year old housewife developed acute polyarthritis in 1983 with the typical symmetrical and widespread distribution of RA. She had associated Raynaud's phenomenon. She had a severely swollen right foot. Over the next few months she developed bilateral lymphoedema of the feet extending up to the mid-calf. This varied in severity over the ensuing years. There was no evidence of venous thrombosis. Investigations showed an ESR of 30 mm/first hour which subsequently rose to >100 mm/hour, remaining high. She was seropositive for rheumatoid factor. Tests for antinuclear antibodies and extractable nuclear antibodies were consistently negative. Radiographs showed widespread rheumatoid erosions. She received non-steroidal anti-inflammatory drugs, tetra-cosactrin acetate, and several slow acting drugs, including penicillamine and chlorambucil. Her RA remained active and the lymphoedema persisted. In 1986 she developed radiological atlantoaxial subluxation.

Discussion

Lymphoedema of the upper limbs is a rare extra-articular feature of RA. It can also affect the lower limbs, as shown in our final case (case 7), and those reported by Dudley Hart² and

Table 2 Summary of six reports of lymphoedema in RA

Report	Year	Number of cases	M/F	Mean age in years	Mean disease duration in years	Rheumatoid factor	Outcome
Kallomaki <i>et al</i> ¹	1968	2	0/2	48	5	2	Neither improved
Dudley Hart ²	1969	3	NK	NK	NK	NK	One case improved
De Silva <i>et al</i> ³	1980	7	NK	51	7	3	One case improved
Kyle <i>et al</i> ⁵	1982	1	1/0	40	3	1	No improvement
Grillet <i>et al</i> ⁴	1987	3	3/0	52	5	1	One case improved
This report	1989	7	3/4	52	3	4	Two cases improved

NK=not known.

Grillet *et al.*⁴ A summary of the details of our own patients and those of the previously reported cases is shown in table 2. Twenty three patients with lymphoedema have been described: in 19 it affected the upper limbs and in four the legs. It is more common in men; there were seven men out of the 13 cases for which the sex was known. It is not related to seropositivity for rheumatoid factor. There is no definite correlation with disease activity; although some cases have quite active RA, others have relatively mild disease. It usually develops in middle aged patients with RA. Sometimes it occurs early in the course of RA, and it has been seen in several patients within the first year of disease. In others, however, the lymphoedema developed after more than a decade of RA; the longest duration was 12 years. It is a chronic condition and only five out of the 23 cases showed any improvement with time and treatment.

The first report by Kalliomaki and Vastamaki described two Finnish women in middle age with seropositive RA.¹ Their lymphoedema showed no obvious response to diuretics, steroids, or other drugs. These workers used lymphoscintigraphy with radiolabelled colloidal gold; the colloidal gold is injected subcutaneously and enters the lymph ducts and passes on to the regional lymph nodes.⁶ In normal subjects active accumulation is seen in the axillary nodes. Kalliomaki and Vastamaki found no uptake of colloidal gold in the axillary nodes of the affected side, which suggested a local lymphatic blockage.

In some patients other mechanisms may lead to swelling of the forearms. Macfarlane and Van der Linden have described swelling in one man due to leaking olecranon bursitis.⁷ McCarty *et al* have reported pitting oedema in remitting seronegative symmetrical synovitis.⁸ These patients have different problems from the 23 patients with lymphoedema, and the changes might have reflected other pathological mechanisms. There may, however, be some features in common; our first patient had diabetes mellitus and the second patient an IgM paraprotein, and both of these might have contributed to increased lymphatic permeability and part of the upper limb swelling. Jayson and Barks have shown that there are changes in capillary permeability in RA with increased filtration of tissue fluid.⁹ In some cases this might have contributed towards the lymphoedema.

Abnormal fibrinolytic mechanisms in RA might also play a part by leading to lymphatic obstruction.

Most reports have included lymphographic studies. We only undertook this in two cases and the investigation was unsuccessful. The findings on lymphography are usually of dilated proximal lymph vessels, extravasation of contrast material and dermal reflux. We felt that the clinical picture was characteristic and that lymphangiograms were unpleasant, and not necessary for management. The lymphangiograms undertaken in the patients with RA and lymphoedema reported previously¹⁻⁵ suggest that the principal cause of the lymphoedema is blockage of the deep lymph vessels. Grillet and Dequeker considered that the process might have been due to an inflammatory lymphangitis, which is similar to the vasculitis of RA. The evidence for this is weak, and an alternative possibility is that there are reduced numbers of lymphatics in rheumatoid patients, which can readily become obstructed by fibrin and related products. In either case there is no definite improvement after aggressive treatment with steroids, slow acting antirheumatic drugs, and cytotoxic agents. We recommend conservative management of such patients with limited investigation.

We thank the Arthritis and Rheumatism Council and the Joint Research Board of St Bartholomew's Hospital for their support. Dr Dacre is an ARC Research Fellow. Dr Scott is the Muir Hambro Research Fellow of the Royal College of Physicians. We thank Dr D V Doyle and Dr J Lanham for allowing us to report their cases.

- 1 Kalliomaki J L, Vastamaki M. Chronic diffuse oedema of the rheumatoid hand: a sign of local lymphatic involvement. *Ann Rheum Dis* 1968; 27: 167-9.
- 2 Hart F D. Rheumatoid arthritis: extra-articular manifestations. *Br Med J* 1969; iii: 131-6.
- 3 De Silva R T D, Grennan D M, Palme D. Lymphatic obstruction in rheumatoid arthritis: a cause for upper limb oedema. *Ann Rheum Dis* 1980; 39: 260-5.
- 4 Grillet D, Dequeker J. Rheumatoid lymphoedema. *J Rheumatol* 1987; 14: 1095-6.
- 5 Kyle V M, De Silva M, Hurst G. Rheumatoid lymphoedema. *Clin Rheumatol* 1982; 1: 126.
- 6 Sage H H, Sinba B K, Kizilay D, Toulon R. Radioactive colloidal gold measurements of lymph flow and functional patterns of lymphatics and lymph nodes in the extremities. *J Nucl Med* 1964; 5: 626-30.
- 7 Macfarlane J D, Van-der-Linden S J. Leaking rheumatoid olecranon bursitis as cause of forearm swelling. *Ann Rheum Dis* 1981; 40: 309-11.
- 8 McCarty D J, O'Duffy J D, Pearson L, Hunter J B. Remitting seronegative symmetrical synovitis with pitting oedema. *JAMA* 1985; 954: 2763-7.
- 9 Jayson M I, Barks J S. Oedema in rheumatoid arthritis: changes in the coefficient of capillary filtration. *Br Med J* 1971; ii: 555-7.