


MASTERCLASS *Clinical cases from the Royal National Hospital for Rheumatic Diseases*

Series editors P J Maddison, A K Bhalla



Spondylodiscitis and pseudarthrosis in a patient with enteropathic spondyloarthropathy

A Calin, D Robertson

Royal National Hospital
for Rheumatic Diseases,
Bath
A Calin

Royal United Hospital,
Bath
D Robertson

Correspondence to:
Dr A K Bhalla,
Royal National Hospital for
Rheumatic Diseases,
Upper Borough Walls,
Bath BA1 1RL.

Bath medallion reproduced
with permission of the
Royal National Hospital for
Rheumatic Diseases, Bath.

The seronegative spondyloarthropathies consist of a group of disorders which includes idiopathic (primary) ankylosing spondylitis, juvenile ankylosing spondylitis, reactive arthritis (or Reiter's syndrome), psoriatic arthritis, and spondylitis of inflammatory bowel disease (enteropathic spondyloarthropathy). The underlying features of these disorders include a predilection to enthesopathy and spinal arthritis, with sacroiliac joint involvement as well as peripheral arthritis. Extra-articular involvement of the eye, heart, mucous membrane, and skin may occur. In addition, there is strong familial aggregation and a striking association with class I antigen HLA-B27.^{1 2}

Chronic inflammation affecting the spinal

entheses leads to fibrosis and ossification of these structures and the formation of syndesmophytes, which reduce mobility. A less common spinal complication of spondylitis is the development of erosive sclerotic lesions of the vertebral bodies surrounding a disc (spondylodiscitis). This article discusses the causes of discovertebral lesions in spondyloarthropathy and the relation between inflammatory bowel disease and spondylitis.

Case report

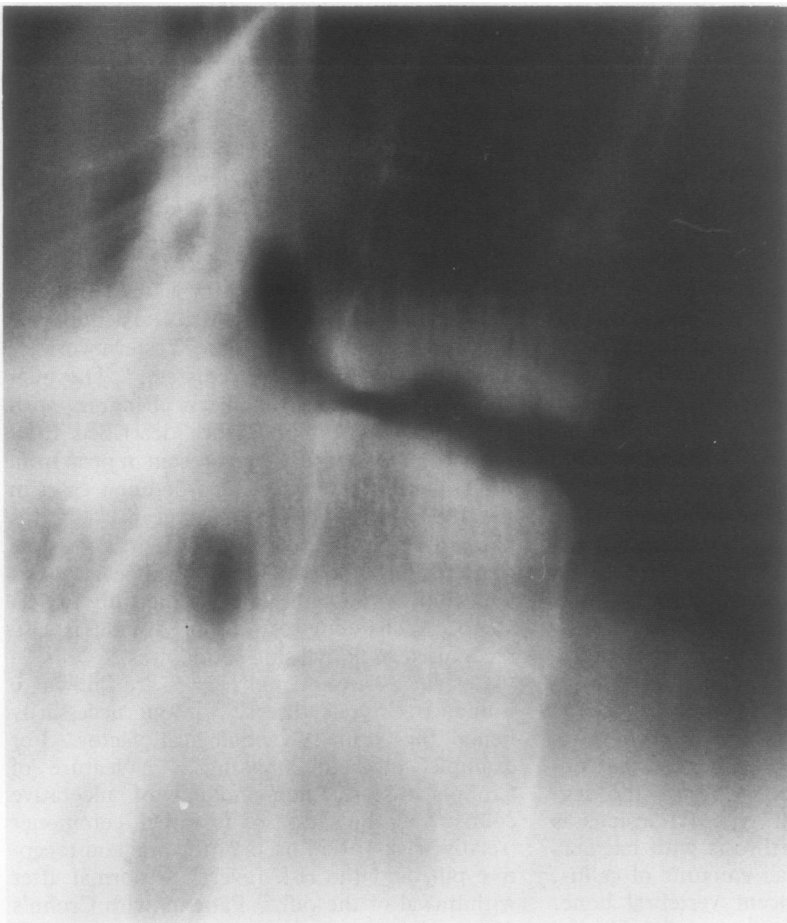The patient, a 48 year old man with ankylosing spondylitis and Crohn's disease, was admitted to hospital in January 1990 with severe lower thoracic back pain.

Ankylosing spondylitis was diagnosed in 1965. Since then he has had regular courses of physiotherapy both as an inpatient and outpatient because of low back ache and neck stiffness. He has had recurrent uveitis since 1971. Crohn's disease was diagnosed in 1972. He has had five bowel resections because of obstruction and is currently awaiting a further operation because of a 20 cm stricture in the terminal ileum. Nephrolithotomy was performed in 1981 because of renal calculus.

Three years ago he developed lower thoracic spinal pain without any history of trauma. This became progressively more severe such that he required opiate analgesia for pain control. He was admitted to hospital in February 1989. Thoracic spine radiography showed evidence of discitis and vertebral end plate collapse at T10-11 vertebrae. Technetium scan showed increased uptake in this area. Gallium scan was normal. His pain improved with rest, physiotherapy, and intramuscular diclofenac.

He was readmitted in January 1990 because of worsening back pain. Pain was described as sharp and knife-like with radiation to his abdomen. Drugs on admission were diclofenac intramuscularly daily, morphine sulphate 20 mg twice daily, prednisolone 15 mg daily. On examination there was a marked thoracic kyphosis. He had tenderness over the lower thoracic vertebrae. Tomography showed widening, irregularity, and sclerosis at the T10-11 intervertebral space. There was a translucent defect through the posterior elements of T11 (figure).

A decision was made to fuse the spine at



Lateral tomogram of T10 and T11 vertebrae showing an erosive sclerotic reaction and a defect through the posterior articulation.

T10–11 after recovery from the impending abdominal operation.

Discussion

In spondylitis, acute back pain may result from trauma or from discovertebral destruction (spondylodiscitis). Discovertebral lesions were first reported in 1937 by Andersson,³ who described the destruction and sclerosis of the disc bone border in the lumbar and thoracic spine of two patients. In 1940 Edstrom described such lesions occurring in a patient after a spell of heavy manual work.⁴ In their comprehensive analysis of such lesions Cawley *et al* have suggested that there are three types of discovertebral lesion.⁵ Type I lesion affects the peripheral region of the discovertebral junction; type II involves the central cartilaginous region of the discovertebral junction; type III affects both the central and peripheral areas of the discovertebral junction. The radiological prevalence of destructive lesions varies from 1% to 28% in different series.^{5 6}

Types I and II lesions often occur in the early phases of the disease, whereas type III lesions occur late in the disease and are uncommon in non-ankylosed spines. The localised peripheral lesion (type I) is often found in senile kyphotic spines, as described by Schmorl and Jungmann.⁷ Histologically the outer fibres of the annulus fibrosus and the adjacent vertebra are replaced by vascular fibrous tissue. Osteoporosis of the vertebrae aids in the collapse of the vertebrae. Type II lesions, affecting the cartilaginous end plates can be found in ankylosed or non-ankylosed spines. Their cause is unknown but is thought to be related to vertebral osteoporosis producing focal bone loss in the subchondral area and permitting the disc contents to herniate through the cartilaginous end plate into the vertebral body.^{5 6} In this regard, it is interesting to note that vertebral osteoporosis in spondylitis may occur early on in the disease.⁸ In addition, apophysial disease in spondylitis may increase forces across the discovertebral junction, leading to breaks in the subchondral bone or cartilaginous end plate and subsequent herniation of the disc contents into the vertebral body.⁶

Type III lesions, seen in patients with advanced spondylitis, may follow trauma or heavy manual work, and there may be a fracture through the ankylosed apophysial articulation or an undisplaced, complete fracture of an ankylosed segment.⁹ Isolated traumatic fractures of the neural arch in non-spondylitis may be followed, some years later, by destructive lesions of the discovertebral junction.⁷ Occasionally, type III lesions may occur in the absence of a fracture and be seen in non-ankylosed segments, where damage is the consequence of excessive forces across the segment.¹⁰ The histology of type III lesions is consistent with a pseudarthrosis with haemorrhage, fibrous tissue, small amounts of callus, and sclerosis of the adjacent vertebral bone. There is only mild inflammatory cell infiltrate, which is thought to be secondary to damage to the tissue of the discovertebral border.

Most patients with discovertebral lesions have back pain which, in the case of type III lesions, may rarely lead to neurological complications.¹¹ Patients, in whom such lesions were detected accidentally during radiological examination, however, were followed up for 17 years but remained asymptomatic.¹² For those with severe back pain immobilisation of the affected segment with braces or spinal fusion seems to be successful in relieving pain.⁴

About 20% of patients with inflammatory bowel disease have sacroiliitis and of these only one fifth will develop widespread axial disease. Peripheral arthritis occurs in 15–20% of patients with inflammatory bowel disease and is often migratory, transient, non-destructive, and oligoarticular. The sacroiliitis and axial disease, but not peripheral arthritis, are HLA-B27 associated. The spondylitis, unlike the peripheral arthritis, does not mimic the fluctuation in the bowel disease.

The causes of both Crohn's disease and ankylosing spondylitis are unknown. The coincidence of these two rare disorders (symptomatic spondylitis is 30 times more common in patients with Crohn's disease than in controls) suggests that there may be aetiological factors common to both. There are differences, however, between primary ankylosing spondylitis and enteropathic spondylitis. The male predominance of primary ankylosing spondylitis (2–6:1) is not found in the spondylitis associated with inflammatory bowel disease (1:1). HLA-B27 is present in only 50% of patients with enteropathic spondylitis compared with close to 100% of patients with primary ankylosing spondylitis.¹³ HLA-B27 is no more common in Crohn's disease than in control groups, except where ankylosing spondylitis is present as well.

The weight of evidence points to an environmental factor rather than genetic factors as the important aetiological agent in Crohn's disease. The disease was not described until the early part of this century.¹⁴ There are large variations in incidence globally, with a tendency for immigrants from Asia and Africa to acquire the disease when they move to the Western world.¹⁵ There are well described clusters.¹⁶ The incidence of the disease has been changing, with steady increases in incidence described from most centres¹⁷ until a very recent report from the United States, where recorded new cases in the 1980s have reduced dramatically.¹⁸ If this observation is repeated elsewhere it is possible that Crohn's disease may disappear, as it appeared, without the cause being fully understood. A changing pattern of disease is also recognised in ankylosing spondylitis.¹⁹

Certain environmental factors are known to influence Crohn's disease without necessarily being the primary aetiological factor. For example, cigarette smoking is a feature of Crohn's disease, non-smoking of ulcerative colitis.²⁰ Crohn's disease is rather commoner (relative risk 1.9) in users of the oral contraceptive pill, and the risk reverts to normal after withdrawal of the pill.²¹ Patients with Crohn's disease have a higher premorbid intake of refined sugar than controls.²²

Does inflammation in the gut predispose to,

or permit, ankylosing spondylitis? Whatever the underlying cause of persistent inflammation in the gut in Crohn's disease, there is increased humoral and cellular immunological activity in the gut, increased epithelial permeability permitting increased absorption of antigen and systemic reactions, and increased expression of class II molecules by epithelial cells.²³ Patients with reactive arthritis or apparent primary ankylosing spondylitis may have asymptomatic inflammation in the gut.²⁴

Intestinal inflammation may be much more common than is widely recognised in ankylosing spondylitis and improvement in our understanding of intestinal inflammation in Crohn's disease and changes in the epidemiology of Crohn's disease may result in improved understanding of ankylosing spondylitis.

- 1 Moll J M H, ed. *Ankylosing spondylitis*. Edinburgh: Churchill Livingstone, 1980.
- 2 Arnette F C. Seronegative spondyloarthropathies. *Bull Rheum Dis* 1987; 37: 1-12.
- 3 Andersson O. Röntgenbildern vid spondylarthritis ankylopoetica. *Nord Med* 1937; 14: 2000.
- 4 Edstrom G. Is spondylarthritis ankylopoetica an independent disease or a rheumatic syndrome? *Acta Med Scand* 1940; 104: 396.
- 5 Cawley M I D, Chalmers T M, Kellgren J H, Ball J. Destructive lesions of vertebral bodies in ankylosing spondylitis. *Ann Rheum Dis* 1972; 31: 345-58.
- 6 Resnick D, Niwayama G. Ankylosing spondylitis. In: Resnick D, Niwayama G, eds. *Diagnosis of bone and joint disorders*. Philadelphia: Saunders, 1988: 1103-70.
- 7 Schmorl G, Junghans H. *The human spine in health and disease*. New York and London: Grune and Stratton, 1957.
- 8 Will R, Palmer R, Bhalla A K, Ring F, Calin A. Osteoporosis in early ankylosing spondylitis: A primary pathological event? *Lancet* 1989; ii: 1483-5.
- 9 Kanefield D G, Mullins B P, Freehafer A A, Furey J G, Horenstein S, Chamberlin W B. Restrictive lesion of the spine in rheumatoid ankylosing spondylitis. *J Bone Joint Surg [Am]* 1969; 51: 1369-75.
- 10 Rivelis M, Freiberg R H. Vertebral destruction at unfused segments in late ankylosing spondylitis. *Radiology* 1969; 93: 251-6.
- 11 Wide C M, Irby W R. Spondylodiscitis in ankylosing spondylitis: variable presentations. *J Rheumatol* 1983; 10: 1004-6.
- 12 Little H, Urowitz M B, Smythe H A, Rosen P S. Asymptomatic spondylodiscitis. An unusual feature of ankylosing spondylitis. *Arthritis Rheum* 1974; 17: 487-93.
- 13 Russel A S. Arthritis, inflammatory bowel disease and histocompatibility antigens. *Ann Intern Med* 1977; 86: 820-1.
- 14 Dalziel T K. Chronic interstitial enteritis. *Br Med J* 1913; ii: 1068-70.
- 15 Mayberry J, Rhodes J. Epidemiological aspects of Crohn's disease. *Gut* 1984; 25: 886-9.
- 16 Allan R N, Pease P, Ibboston J P. Clustering of Crohn's disease in a Cotswold village. *Q J Med* 1986; 59: 473-8.
- 17 Rose J D R, Roberts G M, Williams G, Mayberry J, Rhodes J. Cardiff Crohn's disease jubilee: the incidence over 50 years. *Gut* 1988; 29: 346-51.
- 18 Stowe S P, Redmond S R, Stormont J M, et al. An epidemiological study of inflammatory bowel disease in Rochester, New York; hospital incidence. *Gastroenterology* 1990; 98: 104-10.
- 19 Will R K, Amor B, Calin A. The changing epidemiology of rheumatic diseases: Should ankylosing spondylitis now be included? *Br J Rheumatol* 1990; 29: 299-300.
- 20 Franceschi S, Panza G, La Vecchia C. Non-specific inflammatory bowel disease and smoking. *Am J Epidemiol* 1987; 125: 445-52.
- 21 Lesko S M, Rosenberg L, Helmrick S P, Miller D R, Stolley P D, Shapiro S. Evidence for increased risk of Crohn's disease in oral contraceptive users. *Gastroenterology* 1985; 89: 1046-9.
- 22 Mayberry J F, Rhodes J R, Allan R N. Diet in Crohn's disease. Two studies of current and previous habit in newly diagnosed patients. *Dig Dis Sci* 1981; 26: 444-8.
- 23 Poulsen L O, Elling P, Sorensen P B, Hoedt-Rasmussen K. HLA-DR expression and disease activity in ulcerative colitis. *Scand J Gastroenterol* 1986; 21: 364-8.
- 24 Mielants H, Veys G M, Cuvelier C, De Vos M, Botelberghe L. HLA B27 related arthritis and bowel inflammation. *J Rheumatol* 1985; 12: 294-8.