

## Scleroderma 'en coup de sabre'

J David, J Wilson, P Woo

### Abstract

**A case of scleroderma 'en coup de sabre' presenting with uveitis, predominantly posterior, and intractable grand mal seizures is described. The histopathology specimens and neuroradiology investigations reaffirm the clinical impression that inflammation is not solely confined to the skin in this form of linear scleroderma.**

Scleroderma 'en coup de sabre' is a descriptive term denoting linear scleroderma of the frontoparietal area of the face and scalp. There is scant reported information on the subject and little is known of the aetiopathogenesis.

### Case report

A previously well boy presented at the age of 4 years with a painful, red, puffy left eye. Low grade posterior uveitis was diagnosed by slit lamp examination, but response to topical corticosteroid was slow. The question of whether he had uveitis associated with juvenile arthritis was raised because his mother had a history of pauciarticular juvenile chronic arthritis with chronic anterior uveitis.

Over the succeeding two years he had frontal headaches in addition to his eye problem. At the age of 6 he had a grand mal seizure. Subsequent electroencephalography suggested encephalitis, and lumbar puncture showed 14 lymphocytes and five polymorphonuclear cells in the cerebrospinal fluid. A presumptive diagnosis of viral encephalitis was made, and he was treated with intravenous acyclovir for 10 days. Oral sodium valproate was given for recurrent seizures.

Owing to intractable seizures and drop attacks, the patient was referred to the Hospital for Sick Children for further investigations. Baseline haematology was normal, erythrocyte sedimentation rate 6 mm/h, C reactive protein <6 mg/l. A skull radiograph was normal. Calcific foci in the left posterior parieto-occipital area were seen by computed tomography; these enhanced with contrast media, suggesting infection, inflammation, or arteriovenous malformation. Angiography of both vertebral and carotid axes was normal. Computed tomography of orbits showed mild proptosis of left eye with retro-orbital soft tissue extending beyond the orbital fat plane and infiltrating the ethmoid and sphenoid air sinuses (fig 1). Serum angiotensin converting enzyme and Kveim tests were performed and were negative. Toxoplasma dye test, toxocara enzyme linked immunosor-

bent assay (ELISA), cytomegalovirus titres, and fungal serology were negative. Antibodies to neutrophil cytoplasmic antigen were negative. T cell subsets, phytohaemagglutinin response, neutrophil mobility, and further tests of neutrophil function to exclude chronic granulomatous disease were negative or normal. The antinuclear antibody test was weakly positive with a speckled pattern, but antibodies to extractable nuclear antigen, in particular antibodies to centromere or topoisomerase I, were undetected. Immune complex measured by the C1q binding assay was weakly positive; complement profiles were normal. Biopsy of left orbit showed diffuse chronic inflammatory cell infiltrate with degeneration and regeneration of muscle fibres. There were scattered eosinophils and histiocytes, but no tumour, granuloma formation, microorganisms, or arteritis was seen. Nuclear magnetic resonance imaging showed diffuse involvement of orbital muscles on the left side, suggestive of vasculitis (fig 2). To exclude a

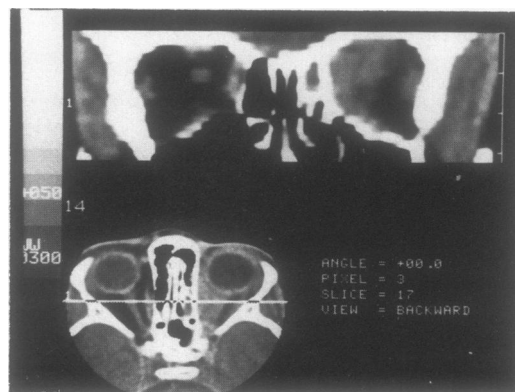


Figure 1 Computed tomography of orbits, sphenoid and ethmoid air sinuses, indicating retro-orbital soft tissue mass on left with infiltration of sinuses.

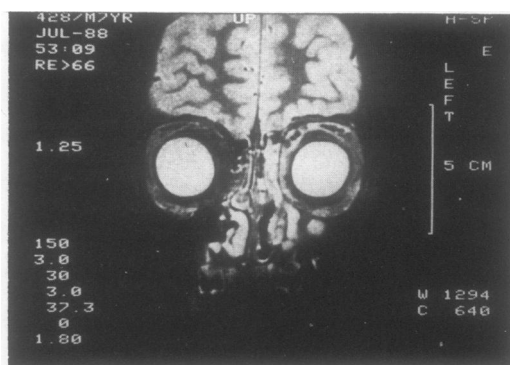


Figure 2 Coronal T2 weighted magnetic resonance image indicating diffuse involvement of left periorbital muscles.

Northwick Park Hospital,  
Harrow and Hospital for  
Sick Children,  
Great Ormond Street,  
London  
J David  
J Wilson  
P Woo

Correspondence to:  
Dr J David,  
Department of Molecular  
Rheumatology,  
Clinical Research Centre,  
Watford Road, Harrow,  
Middlesex HA1 3UJ.

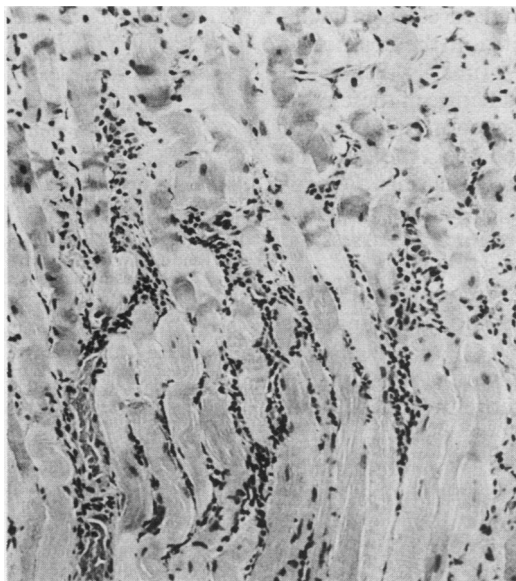
Accepted for publication  
16 May 1990

systemic vasculitic illness a renal DMSA (meso-2,3-dimercaptosuccinic acid) scan was performed and was normal. Further nasal mucosa biopsies showed marked acute and chronic inflammation, but no necrotising arteritis. The nasal sinus section showed oedema and chronic inflammation of the mucosa; there were focal ring-like areas of calcification suggestive of small arterioles. The lateral rectus muscle showed prominent lymphocytic infiltrate between muscles fibres (fig 3).

In view of the evidence for a localised vasculitis oral corticosteroid treatment was started with prednisolone 2 mg/kg daily. Within two months there was a dramatic improvement in intraocular inflammation as detected by slit lamp examination. The patient, however, became cushingoid, had further seizures and drop attacks, and a groove extending from crown to orbital margin was reported by his parents.

Scleroderma 'en coup de sabre' was the most likely diagnosis and treatment with penicillamine 125 mg daily increasing to 10 mg/kg daily was started. This was well tolerated. Six months after the start of treatment there was no further extension of the groove. The seizures were controlled by the epileptic regimen. His behaviour had also improved during this time.

Figure 3 Section of lateral rectus muscle with prominent lymphocytic infiltrate (haematoxylin and eosin).



#### Ocular manifestations of linear scleroderma<sup>7 8 10-13</sup>

Hyperpigmented or depigmented eyelid  
Narrowed palpebral fissure  
Lid lash loss  
Exotropion and ectropion  
Ptosis due to levator palpebrae paresis  
Excessive lachrymation  
Iritis  
Heterochromia  
Sector iris atrophy  
Corneal epithelial opacity  
Diminished corneal sensitivity  
Phthisis bulbi with uveitis  
Cataract  
Ipsilateral neurocytoma of optic nerve  
Retinal haemorrhage due to new vessel formation  
Paresis of ocular muscles, especially superior and medial recti  
Glaucoma  
Deeply set eyeball in orbit  
Retro-orbital inflammation with proptosis  
Sympathetic nerve lesion causing Horner's syndrome

#### Discussion

Scleroderma 'en coup de sabre' is a rare form of circumscribed scleroderma which affects the skin of the face and scalp. The first descriptions were by Addison in 1854.<sup>1</sup> Characteristically, this form of scleroderma is restricted to one half of the face and has a slow but progressive course. It has all the features typical of scleroderma—initial inflammatory phase, induration, and subsequent atrophy of skin and underlying tissues. Loss of hair occurs on scalp and eyelids, the skin becomes adherent to subcutaneous tissues, and the lesion may have hyperpigmented borders and telangiectasis. Linear scleroderma of the face, especially in the atrophic stage, may closely resemble the Romberg type of idiopathic facial hemiatrophy. Wartenberg believes that 'sabre-cut' scleroderma is an abortive form of facial hemiatrophy, which itself is a sequel of hereditary degenerative changes in the nervous system.<sup>2</sup> Wolff and Ehrenclou consider that facial hemiatrophy is not a pathological entity in itself but a syndrome which may coexist with or occur as a sequel to circumscribed scleroderma as well as other conditions.<sup>3</sup>

Scleroderma 'en coup de sabre' results in atrophy not only of skin and subcutaneous tissue but also of muscles and bone.<sup>4</sup> In hemiatrophy the primary lesion is atrophy of deeper tissues, which thereafter affects the skin. In scleroderma induration and skin adhesion are primary and the atrophic changes secondary. The histology of the conditions is different, with sclerosis of connective tissue as a primary phenomenon in hemiatrophy.<sup>5</sup> The marked intraocular inflammation, mild proptosis, and infiltration of rectus muscles in our patient support the notion of extensive inflammation in linear scleroderma (table), in contrast with morphoea where only the skin is seen to be affected.

Various causative factors have been suggested in scleroderma 'en coup de sabre'. Trauma, including surgery and infection,<sup>6</sup> may precede the development of the lesion. Segal and colleagues describe a case of linear scleroderma that developed some months after severe psychological stress.<sup>7</sup> There is a female preponderance of 3:1 and a higher incidence around menarche, pregnancy, and menopause.<sup>8</sup> One report describes hereditary C2 deficiency in association with scleroderma 'en coup de sabre'.<sup>9</sup> There are no reports linking the lesion to juvenile chronic arthritis. The fact that our patient's mother had pauciarticular arthritis in childhood is interesting. There are several reports where there is a family history of rheumatoid arthritis and systemic lupus erythematosus.<sup>14</sup> Seventy five per cent have onset of linear scleroderma in childhood with the disease progressing rapidly in the first three to six years.<sup>6</sup>

Intracerebral calcification and seizures in association with scleroderma 'en coup de sabre' has been reported previously. It is thought to occur as part of a scarring process after an initial inflammatory phase. In his classic monograph Wartenberg noted that his three patients with scleroderma 'en coup de sabre' showed grand mal epilepsy or Jacksonian seizures.<sup>2</sup> Dilley

described a 13 year old girl with bilateral scleroderma 'en coup de sabre' with major motor and psychomotor seizures<sup>15</sup>; her skull radiographs showed intracranial calcification and electroencephalography showed arrhythmia. Two of the four patients with localised scleroderma of the face in Chazen's series of 19 children with focal scleroderma developed grand mal seizures one year and 16 years respectively after the onset of the facial lesion.<sup>8</sup> Both Leinwand and Stava mention the increased incidence of electroencephalographic abnormalities.<sup>14 16</sup> A number of authors discuss the notion that scleroderma 'en coup de sabre' might represent an abnormality of cranial neural crest cell migration during embryonal life. Johnston describes the migration pattern of crest cells in the cranium following vertical lines similar to the coup de sabre lines.<sup>11</sup> The author describes two cases in which the eye is affected in the same line, both indicating an embryonal predisposition.

Treatment for linear scleroderma is unsatisfactory. Local treatments such as massage with lanolin creams and moisturisers may improve skin elasticity (Ansell B M, personal communication). Treatment with penicillamine is controversial and there are conflicting reports on its efficacy. The rationale of treatment is based on the fact that the final cross linkage of the adjacent polypeptide chains, which constitute the nascent three-standard collagen molecule, can take place in vitro in the absence of enzymes, and is therefore primarily a chemical process.<sup>18</sup> The number and nature of these cross linkages determine the degree of solubility of the molecules. In scleroderma there is no soluble collagen present in the dermis. Penicillamine can solubilise collagen both in vitro and in vivo. A controlled trial is needed to assess the efficacy of penicillamine.

Reconstructive facial surgery with skin excision, grafting, silicone and bone implants have been useful.<sup>19</sup>

This case illustrates how the diagnosis of scleroderma 'en coup de sabre' was made some

years after the presentation of uveitis and seizures and only when a cranial parasagittal linear groove with alopecia was apparent. The previously held clinical impression that there is inflammation elsewhere in linear scleroderma is reaffirmed by the histology specimens obtained. Neuroradiological techniques are useful in monitoring and defining the disease process and in following response to treatment.

- 1 Addison C H. Medico-surgical transactions of 1854, quoted by Fox T C: note on the history of scleroderma in England. *Br J Dermatol* 1892; 4: 101.
- 2 Wartenberg R. Progressive facial hemiatrophy. *Archives of Neurology and Psychiatry* 1945; 54: 75-7.
- 3 Wolff H G, Ehrenclou A H. Trophic disorders of central origin: report of a case of progressive facial hemiatrophy associated with a lipodystrophy and other metabolic derangements. *JAMA* 1927; 58: 991.
- 4 Schnyder O W. Circumscripta Sclerodermien mit Weichteil- und Knochenatrophie. *Dermatol Monatschr* 1956; 112: 444-52.
- 5 Moschella S L, Pillsbury D M, Hurley H J. *Dermatology international*. Philadelphia: Saunders, 1975: 933-5.
- 6 Christianson H B, Dorsey C J, O'Leary P A, Kierland R R. Localised scleroderma—a clinical study of two hundred and thirty-five cases. *Arch Dermatol* 1956; 74: 629-39.
- 7 Segal P, Jablonska S, Mrzyglod S. Ocular changes in linear scleroderma. *Am J Ophthalmol* 1961; 51: 807-13.
- 8 Chazen F M, Cook C D, Cohen J. Focal scleroderma—report of 19 cases in children. *J Pediatr* 1962; 60: 385-93.
- 9 Hulsmans R F H J, Ashar S S, Siddiqui A H, Cormane R H. Hereditary deficiency of C2 in association with linear scleroderma "en coup de sabre". *Arch Dermatol* 1987; 122: 76-9.
- 10 Stone R A, Scheie H E. Periorbital scleroderma associated with heterochromia iridis. *Am J Ophthalmol* 1980; 90: 858-61.
- 11 Serup J, Serup L, Sjo O. Localised scleroderma 'en coup de sabre' with external eye muscle involvement at the same line. *Clin Exp Dermatol* 1984; 9: 196-200.
- 12 Josten K. Sclerodermie en coup de Sabre und Auge. *Klin Monatsbl Augenheilkd* 1958; 133: 567.
- 13 Coyle E F. Scleroderma of the cornea. *Br J Ophthalmol* 1956; 40: 239.
- 14 Leinwand I, Duryee A W, Richter M N. Scleroderma (based on a study of over 150 cases). *Ann Intern Med* 1954; 41: 1003.
- 15 Dilley J J, Perry H O. Bilateral linear scleroderma en coup de sabre. *Arch Dermatol* 1968; 97: 688-9.
- 16 Stava Z, Stein J. Electro-encephalography in scleroderma. *Dermatologica* 1961; 123: 375-90.
- 17 Johnston M. The neural crest in abnormalities of the face and brain. In: Bergsma D, Langman J, Pane N W, eds. *Morphogenesis and malformation of face and brain*. New York: Alan R Liss, 1975: 1-18. (Original article series, Vol 11, No 7.)
- 18 Moynahan E J. Morphea (localized cutaneous scleroderma) treated with low-dosage penicillamine. *Proceedings of the Royal Society of Medicine* 1973; 66: 49-51.
- 19 Milan M F, Bennett J E. Scleroderma en coup de sabre. *Ann Plast Surg* 1983; 10: 364-70.