

# Sternoclavicular joint disease in psoriatic arthritis

E Taccari, A Spadaro, V Ricciari, R Guerrisi, V Guerrisi, A Zoppini

## Abstract

The radiological and tomographic aspects of the sternoclavicular joint were examined in 10 patients with psoriatic arthritis to evaluate better how this joint was affected using different radiological techniques. Imaging of the sternoclavicular joint showed that computed tomography provides a better visualisation of erosions, subchondral cysts, and sclerosis than standard radiography and conventional linear tomography.

The sternoclavicular joint is formed by the articular surface of the clavicle, the sternum, and the first rib. This joint is often divided into two separate compartments by a fibrocartilaginous disc and is stabilised by the costoclavicular ligament.<sup>1-3</sup> The sternoclavicular joint accompanies every movement of the arm and if it is affected clinically, symptoms include swelling, erythema, warmth, pain, and sometimes joint effusions.

Radiological evaluation of the sternoclavicular joint often requires special standard projections, and conventional linear and computed tomography. Radionuclide bone scanning may be helpful in confirming the presence of arthropathy.

The sternoclavicular joint is often affected in polyarthritis or spondyloarthritis. Clinical or radiological abnormalities of the sternoclavicular joint have been reported in 1-41% of patients with rheumatoid arthritis,<sup>4,5</sup> in 2-28% of patients with ankylosing spondylitis,<sup>3-8</sup> and rarely in patients with Reiter's disease.<sup>9,10</sup> Although the sternoclavicular joint is clinically affected in 15% of patients with psoriatic arthritis,<sup>9</sup> there has not yet been any radiological studies on this joint.

This study was performed to evaluate better the radiological, tomographic, and scintigraphic aspects of the sternoclavicular joint affected by psoriatic arthritis, assessing at the same time the value of the various radiological imaging techniques.

## Materials and methods

We examined 10 consecutive patients admitted to hospital (five men and five women, age range 39-71 years; mean 56.7 years) with psoriatic arthritis, fulfilling the diagnostic criteria proposed by Moll and Wright.<sup>11</sup> The duration of the arthritis ranged from 2 to 21 years (mean 7.6 years). All patients had asymmetrical peripheral articular involvement associated with bilateral sacroiliitis in seven patients and

spondylitis in one. In eight patients the large joints were affected articularly.

Psoriatic skin lesions were generalised in eight patients but in two patients these were localised. In four patients the nails were also affected. No patient had palmoplantar pustulosis nor other dermatological disease. All patients denied previous recurrent or acute trauma involving the sternoclavicular joint and were seronegative for rheumatoid factors (determined by enzyme linked immunosorbent assay (ELISA)).

The sternoclavicular joint of each patient was examined with standard radiography, conventional linear tomography, computed tomography, and scintigraphy.

Radiographic and tomographic films of the sternoclavicular joint were evaluated for evidence of marginal erosions (>2 mm), subchondral cysts, sclerosis or osteopenia, changes in the width of the joint, partial or total ankylosis, osteophytes, and capsular or ligamentous calcifications.

Computed tomography examinations of sternoclavicular joint were performed on a Philips tomoscan 350 (scan time 9.5 seconds), with a slice thickness of 3.0 mm and a field of view of 400 mm. All patients lay symmetrically in the supine position with both arms above their head.

A total body scintiscan with 555 MBq <sup>99m</sup>Tc labelled methylene diphosphonate was performed for all patients. A gammacamera was used with an information density acquisition of 2000 counts per square centimetre. In each patient a positive image was defined, evaluating the Tc uptake of the joint relative to adjacent non-articular bone and soft tissue.

We also examined 10 age and sex matched controls (five women, five men; 58.1 years, range 40-69) without clinical involvement of the sternoclavicular joint. The control subjects were interspersed evenly among the patients and were assessed separately by a radiologist and a rheumatologist at the same time as the patients.

## Results

The sternoclavicular joint was clinically affected in only five patients, with spontaneous pain in three patients. All but one patient had radiological or scintigraphic abnormalities, or both, of the sternoclavicular joint (table). In six patients standard radiography and conventional linear tomography showed erosions of the sternum (two patients) or the clavicle, or both (four patients), whereas computed tomography

Institute of  
Rheumatology,  
Policlinico Umberto I,  
University 'La Sapienza',  
Rome, Italy  
E Taccari  
A Spadaro  
V Ricciari  
A Zoppini

Department of  
Experimental Medicine  
(Section of Radiology),  
Policlinico Umberto I,  
University 'La Sapienza',  
Rome, Italy  
R Guerrisi  
V Guerrisi

Correspondence to:  
Professor Egipto Taccari,  
Institute of  
Rheumatology,  
University 'La Sapienza',  
of Rome, 00161 Rome,  
Italy.

Accepted for publication  
20 May 1991

## Radiological (Rx), conventional linear (CLT), and computed tomography (CT) changes of the sternoclavicular joint in patients with psoriatic arthritis

Patient No	Sex*	Age (years)	Disease duration (years)	Erosions*			Cysts*			Sclerosis*			Joint width (mm)	
				Rx	CTL	CT	Rx	CTL	CT	Rx	CTL	CT	Left	Right
1	F	69	15	c	c	s,r	—	—	s,c,r	—	—	s	3	3
2	F	62	5	s	s	s,c,r	—	—	s,c,r	s	—	s,c,r	1	1
3	M	39	6	c	—	c	—	—	—	—	—	—	5	5
4	M	47	21	—	—	s,c	—	—	s,c	—	—	s,c	7	7
5	F	69	2	—	—	—	—	—	—	—	—	—	6	6
6	F	52	18	c	c	s,c,r	—	—	s,c,r	—	—	s,c,r	1	8
7	M	48	6	—	—	s	—	—	s	—	—	—	2	4
8	M	50	19	s	s,c	s,c	—	—	s,c	—	—	s,c	4	4
9	M	71	9	c	c	s,c,r	s,c	s,c	s,c,r	—	—	—	6	8
10	F	66	4	—	—	s,r	—	—	—	—	—	s,c,r	3	3

\*M=male; F=female; s=sternum; c=clavicle; r=rib; Rx=standard radiography; CTL=conventional linear tomography; CT=computed tomography.

showed erosions of the sternum (eight cases), the clavicle (six cases) or the first rib, or both (five cases) in nine patients (fig 1). Computed tomography also revealed subchondral cysts (seven patients) and sclerosis (six patients) (fig 2), whereas the other techniques only showed these abnormalities in patient numbers 2 and 9. The width of the joint was asymmetrically reduced in three patients.

All radiological methods showed osteophytes of the first rib and sternum in four patients,

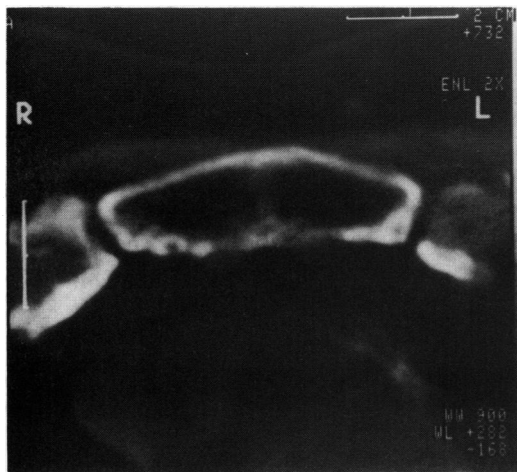


Figure 1 Computed tomography scan of the sternoclavicular joint showing erosion of the chondrosternal articular surfaces and posterior surface of the sternum.

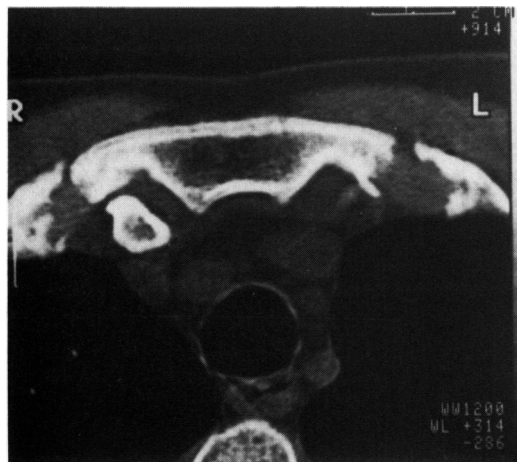


Figure 2 Computed tomography scan of the sternoclavicular joint showing erosion, sclerosis, and cysts.

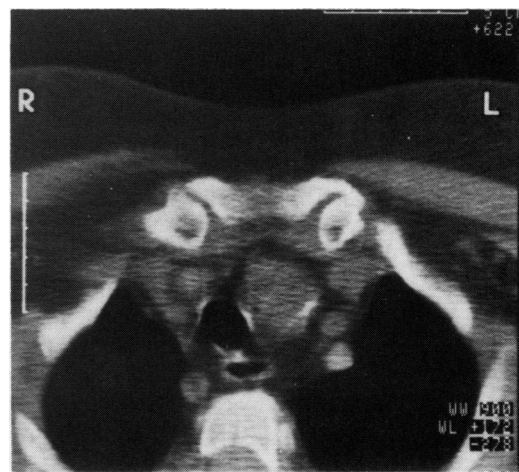


Figure 3 Computed tomography scan of the sternoclavicular joint showing capsular calcification of the left sternoclavicular joint.

whereas only computed tomography allowed a monolateral capsular calcification of the sternoclavicular joint to be seen in patient number 10 (fig 3). No patient showed ankylosis of the sternoclavicular joint.

Radionuclide imaging of the sternoclavicular joint showed a marked uptake, mostly asymmetrical, of methylene diphosphonate labelled Tc in eight patients, which was related to a clinical or radiological involvement, or both.

We found joint narrowing and sclerosis of osteophytes in four of the controls and abnormal radionuclide uptake in two control subjects.

### Discussion

Knowledge of whether the sternoclavicular joint is clinically affected is very important in differential diagnosis of chest or shoulder pain, because pain attributed to this joint may often be confused with pain originating from other articular structures (cervical spine, shoulder, acromioclavicular, or costochondral joints) or viscera (heart, lung, or gall bladder).

The sternoclavicular joint is often affected in systemic and localised rheumatic diseases. In patients with psoriatic arthritis, clinical symptoms referred to this joint were found in 15% of patients,<sup>9</sup> but to our knowledge radiological or scintigraphic studies of the sternoclavicular joint have not been reported previously

in this disease. Evaluation of the sternoclavicular joint using only standard radiography with frontal and oblique projections is often difficult, whereas conventional linear tomography and computed tomography may be helpful.<sup>12-14</sup>

This paper confirms that computed tomography provides a better visualisation of the sternoclavicular joint in agreement with Destouet *et al.*,<sup>13</sup> and allows the elucidation of the radiological picture of the sternoclavicular joint in psoriatic arthritis. Computed tomography showed marginal erosion in nine patients and subchondral cysts in eight, whereas the other radiological techniques often failed to show these lesions in the same articular components of the sternoclavicular joint (table). These articular changes seen by computed tomography were an expression of persistent active arthropathy in eight patients, in agreement with clinical or scintigraphic examinations, or both.

These findings enhance the value of computed tomography because erosive changes play a central part in the radiological diagnosis of arthritis.<sup>15</sup> Moreover, computed tomography allowed a better evaluation of subchondral sclerosis, which is not exclusive to arthropathy as it is important in most normal subjects, especially in the elderly.<sup>15</sup>

The width of the articular space was asymmetrically reduced in three patients, but, according to Kalliomaki,<sup>15</sup> we must consider that the angle between the articular surface of the sternum and the clavicle is very different in individual subjects. Thus, the narrowing of the sternoclavicular joint space is not always a sign of arthropathy.

In four patients we also observed osteoproliferative changes, but degenerative lesions were not unusual in the control subjects, and in autopsy series by the third decade of life.<sup>3</sup>

The number of patients studied is too small for any significant clinical or radiological correlation in psoriatic arthritis, but the aim of this work was to show radiological and tomographic pictures of the sternoclavicular joint in psoriatic arthritis and to confirm the value of

computed tomography in the assessment of the sternoclavicular joint. In fact, computed tomography allows a superior evaluation of this joint compared with conventional radiography and linear tomography. Moreover, we must consider that computed tomography provides less radiation exposure, takes less time to perform, and gives less discomfort to the patient than conventional linear tomography.<sup>13</sup> Thus, computed tomography examination gives information on the arthropathic involvement of the sternoclavicular joint in psoriatic arthritis and is useful for a better control of the disease. In fact, it is suggested that it is reasonable to carry out a computed tomography examination of the sternoclavicular joint in any patient with psoriatic arthritis who has unexplained chest or shoulder pain.

- 1 De Palma A F. *Degenerative changes in the sternoclavicular and acromioclavicular joints in various decades*. Springfield: Charles C Thomas, 1957; 5, 155.
- 2 De Palma A F. The role of the discs of the sternoclavicular and the acromioclavicular joints. *Clin Orthop* 1959; 13: 222-33.
- 3 Yood R A, Goldenberg D L. Sternoclavicular joint arthritis. *Arthritis Rheum* 1980; 23: 232-9.
- 4 Laine V A I, Vainio K J, Pekanmaki K. Shoulder afflictions in rheumatoid arthritis. *Ann Rheum Dis* 1954; 13: 157-61.
- 5 Dilsen N, McEwen C, Poppel M, Gersh W J, DiTata D, Carmel P. A comparative roentgenologic study of rheumatoid arthritis and rheumatoid (ankylosing) spondylitis. *Arthritis Rheum* 1962; 5: 341-68.
- 6 Julkunen H. Rheumatoid spondylitis. *Acta Rheumatol Scand Suppl* 1962; 4: 1-111.
- 7 Wilkinson M, Bywaters E G L. Clinical features and course of ankylosing spondylitis. *Ann Rheum Dis* 1958; 17: 209-28.
- 8 Forestier J, Jacqueline E, Rotes-Querol J. *La spondylarthrite ankylosante; clinique, radiologie, anatomie pathologique, traitement*. Paris: Masson, 1951: 325.
- 9 Baker H, Golding D N, Thompson M. Psoriasis and arthritis. *Ann Intern Med* 1963; 58: 909-25.
- 10 Weldon W V, Scaletter R. Roentgen changes in Reiter's syndrome. *Am J Roentgenol* 1961; 86: 344-50.
- 11 Moll J M L, Wright V. Familial occurrence of psoriatic arthritis. *Ann Rheum Dis* 1973; 32: 181.
- 12 Morag B, Shahin N. The value of tomography of the sternoclavicular region. *Clin Radiol* 1975; 26: 57-62.
- 13 Destouet J M, Gilula L A, Murphy W A, Sagel S S. Computed tomography of the sternoclavicular joint and sternum. *Radiology* 1981; 138: 123-8.
- 14 Deutsch A L, Resnick D, Mink J H. Computed tomography of the glenohumeral and sternoclavicular joints. *Orthop Clin North Am* 1985; 16: 497-511.
- 15 Kalliomaki J L, Viitanen S-M, Virtama P. Radiological findings of sternoclavicular joints in rheumatoid arthritis. *Acta Rheumatol Scand* 1968; 14: 233-40.