

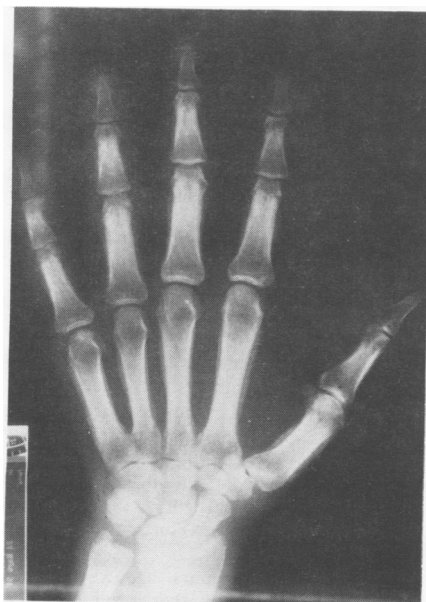
A protein profile disclosed no abnormalities except for mild hypoalbuminaemia (30 g/l). Antibodies against hepatitis B surface antigens and hepatitis B core antigens were positive. A test for hepatitis surface B antigen was negative. Complement C3 and C4 were normal. Immunoglobulin A was 5 g/l (normal <3.75). Tests for IgG and IgM, rheumatoid factor, antinuclear antibodies, the Venereal Disease Research Laboratory test, tests for thyroid hormones and somatotropin were all normal or negative, as were HLA-B27 and serological assays for *Brucella*, *Salmonella*, *Yersinia enterocolitica*, and *Chlamydia* spp.

Roentgenograms of the chest showed images of consolidation and multiple cavitations in the superior lobe of the right lung, compatible with necrotising pneumonitis. Intradermoreaction with tuberculin 2U was positive. Microbiological examination of samples of sputum showed Gram positive cocci. Sputum and blood cultures were negative, and repeated searches found no mycobacteria in the sputum. Thereafter, percutaneous needle aspiration of the lung was performed. Cultures of the samples in anaerobic media were positive for microaerophilic Gram positive cocci and *Bacteroides melaninogenicus*.

Cultures of stools were positive for *Candida albicans*. Upper gastrointestinal fibre endoscopy confirmed the presence of intense candida oesophagitis and hiatal hernia.

Radiographs of the hands, feet, forearms, and legs showed typical signs of hypertrophic osteoarthropathy (figure). Synovial fluid from one knee was mildly inflammatory, it contained 3.5×10^9 cells/l, with more than 90% lymphocytes. The glucose concentration was 3.9 mmol/l, C3 was 500 mg/l, C4 80 mg/l. A search for microorganisms and crystals was negative.

The patient was diagnosed as having AIDS, anaerobic necrotising pneumonitis, and secondary hypertrophic osteoarthropathy. He was treated with clindamycin, indomethacin, and zidovudine (AZT) and both his general condition and lung lesions improved rapidly. Five months later he was asymptomatic in his joints, and bone radiographic changes had almost disappeared.



Radiograph of the left hand of the patient, showing diffuse oedema, clubbing, and periostitis of long bones. The other hand, forearms, and legs, as well as the feet were similarly affected.

To the best of our knowledge the case of only one patient with hypertrophic osteoarthropathy and AIDS has been published, being a young male abuser of parenteral drugs with *Pneumocystis carinii* pneumonitis.¹ The severe osteoarthropathic manifestations of the patient that we report reinforce both the possibility of this association and the typical painful character common to many of the rheumatic syndromes that have been described in HIV infected patients.²

The excellent response of our patient to antibiotics suggests that hypertrophic osteoarthropathy was due to lung infection. As the patient had severe manifestations we do not exclude a possible role for HIV or its effects on immunity as modulator or amplifier of the mechanisms that led to hypertrophic osteoarthropathy. Some authors have proposed immune mechanisms in the pathogenesis of hypertrophic osteoarthropathy.³ Further studies are needed before this possibility can be confirmed.

LOURDES GIL-GARCIA
J MANUEL MARTIN-SANTOS
MANUEL BLANCO-CABERO
J ANGEL TAPIAS DEL POZO
FELICISIMO MARTINEZ-BARRERO
Department of Internal Medicine
Hospital Del Rio Hortega,
Valladolid, Spain

Correspondence to: Dr J M Martin-Santos, Unit of Rheumatology, Hospital 'Del Rio Hortega', C/Cardenal Torquemada s/n, 47010 Valladolid, Spain.

- 1 Bhat S, Heurich A E, Vaguer R A, *et al*. Hypertrophic osteoarthropathy associated with *Pneumocystis carinii* pneumonia in AIDS. *Chest* 1989; **96**: 1208-9.
- 2 Rynes R I. Painful rheumatic syndromes associated with human immunodeficiency virus infection. *Rheum Dis Clin North Am* 1991; **17**: 79-87.
- 3 Schumacher H R. Articular manifestations of hypertrophic osteoarthropathy in bronchogenic carcinoma: a clinical and pathologic study. *Arthritis Rheum* 1976; **19**: 629-36.

Disseminated gonococcal infection in an elderly patient

Sir: We present the case of an elderly patient with disseminated gonococcal infection and congenital C2 deficiency.

A 72 year old married woman was admitted to our hospital because of arthritis of her right wrist and knee. She had been well until 10 days before admission, when she developed chills with painful swelling of the wrist and knee. She denied any rash, diarrhoea, vaginal discharge, recent sexual contacts, ocular or genitourinary symptoms. Her husband also denied sexual activity.

On examination she had a fever (38°C) and painful swelling of the right wrist and knee. No cutaneous lesions or tenosynovitis were seen.

A diagnostic arthrocentesis of the right knee showed 20 ml of purulent synovial fluid containing 80×10^9 cells/l. Gram staining showed no microorganism, but *Neisseria gonorrhoeae* was cultured. Blood cultures remained sterile. The erythrocyte sedimentation rate was 75 mm/h, results of a routine biochemistry test and urine analysis were normal and serological tests for syphilis and brucella were negative. The hands, knees, and pelvis radiographs were normal. Total haemolytic complement (CH50) was 0 U/ml. No

complement C2 was detected in two consecutive determinations.

She was treated with intravenous benzylpenicillin 1.2 g four times a day for seven days, followed by oral amoxicillin 1.5 g daily for 10 days. She required closed drainage for three consecutive days.

Patients with deficiencies in the terminal components of the complement system may develop episodes of disseminated infection with *N gonorrhoeae* and *N meningitidis*.¹ C2 deficiency is the most common complement deficiency, often associated with immune complex disease and recurrent sepsis.² To our knowledge, only one case of disseminated gonococcal infection associated with C2 deficiency has been reported.³ Our patient had not had any previous neisserial or recurrent infections.

Disseminated gonococcal infection has been infrequently reported in the elderly^{5, 6}; patients with disseminated gonococcal infection are usually younger than 40.^{4, 7-9} The importance of suspecting this diagnosis, even in elderly patients without an appropriate history, is that the organism may be missed unless correct cultures are taken.¹⁰ *N gonorrhoeae* is recovered from less than 50% of purulent effusions, and positive blood cultures may occur in only 30% of patients; therefore, in suspected cases, cervical, urethral, rectal, and pharyngeal cultures should be obtained.

This report highlights the need to consider a broad range of microorganisms in elderly patients with septic arthritis.

IÑIGO RÚA FIGUEROA
EDUARDO LOZA CORTINA
SENEN GONZÁLEZ SUÁREZ
CELIA ERAUSQUIN ARRUABARRENA
JOSE L PEÑA SAGREDO
Rheumatology Division,
Hospital Universitario
Marqués de Valdecilla,
Santander, Spain

Correspondence to: Dr Rúa-Figueroa, Hospital Universitario Marqués de Valdecilla, Rheumatology Division, Avda de Valdecilla s/n, 3908 Santander (Cantabria), Spain.

- 1 Petersen B H, Lee T J, Snyderman R, Brooks G F. *Neisseria meningitidis* and *Neisseria gonorrhoeae* bacteremia associated with C6, C7 and C8 deficiencies. *Ann Intern Med* 1979; **90**: 917-20.
- 2 Kelly W N, Harris E D, Ruddy S, Sledge C B. *Textbook of rheumatology*, 3rd ed, Philadelphia: Saunders, 1989.
- 3 McWhinney P H M, Langhorne P, Love W C, Whaley K. Disseminated gonococcal infection associated with deficiency of the second component of complement. *Postgrad Med J* 1991; **67**: 297-8.
- 4 O'Brien J P, Goldenberg D L, Rice P A. Disseminated gonococcal infection: a prospective analysis of 49 patients and review of pathophysiology and immune mechanism. *Medicine (Baltimore)* 1983; **62**: 395-406.
- 5 Geelhoed-Duyvestijn P H L M, van der Meer J W M, Lichtendahl-Bernards A T, Mulder Ch J, Meyers K A E, Poolman J T. Disseminated gonococcal infection in elderly patients. *Arch Intern Med* 1986; **146**: 1739-40.
- 6 Fernández Guerrero M L, Macarrón P, Barros C, Azofra J, Aguado J M. Disseminated gonococcal infection. *Arch Intern Med* 1989; **149**: 227.
- 7 Holmes K K, Counts B W, Beaty H N. Disseminated gonococcal infection. *Ann Intern Med* 1971; **74**: 979-93.
- 8 Masi A T, Eisenstein B. Disseminated gonococcal infection (DGI) and gonococcal arthritis (GCA). II. Clinical manifestations, diagnosis, complications, treatment and prevention. *Semin Arthritis Rheum* 1981; **10**: 173-97.
- 9 Brogadir S P, Schimmer B M, Myers A R. Spectrum of the gonococcal arthritis-dermatitis syndrome. *Semin Arthritis Rheum* 1979; **8**: 177.
- 10 Hook E W, Holmes K K. Gonococcal infections. *Ann Intern Med* 1985; **102**: 229-43.