

## Vacuum sign in spondylodiscitis due to *H aphrophilus*

SIR: *Haemophilus aphrophilus* is a Gram negative, capnophilic, slow growing bacillus.<sup>1</sup> In human disease this organism is an uncommon cause of bacterial endocarditis and, rarely, brain abscess, meningitis, sinusitis, peritonitis, pneumonitis, epidural abscess.<sup>2</sup>

We report a case of spondylodiscitis due to *H aphrophilus*, in which diagnosis was delayed because of the presence of a vacuum phenomenon in the intervertebral disc space, initially interpreted as non-infectious disease.

A 67 year old man presented with a three week history of increasing low back pain associated with fever of 38°C. Eight days previously he had been treated for a respiratory tract infection with 1 g of amoxicillin/day. A physical examination showed he was normal except for severe lumbar stiffness. His temperature was raised to 38.5°C. Routine laboratory tests showed leucocytosis ( $10.5 \times 10^9$  white blood cells/l) and a raised erythrocyte sedimentation rate (60 mm/h). Routine x ray examination of the lumbar spine showed narrowing of the L4-5 and L5-S1 discs. Computed tomography confirmed the absence of bone lesions and showed a vacuum phenomenon at the L4-5 level, which was interpreted as a degenerative lesion (fig 1). A bone scan (technetium-99m) showed a slightly increased uptake at L4-5. The search for a septic process proved to be negative in urine, blood, sputum, and in pharyngeal and buccal swabs. Multiple investigations for a malignant neoplasm or a haematological malignancy gave negative results showing that the pain was not due to such lesions. Repeated serological tests for Lyme disease and HIV, and Wright and Widal-Felix tests were negative. The intradermal tuberculin was negative.

Owing to the lack of improvement and the persistent fever during this long hospital admission, a lumbar puncture was performed. It showed a raised cerebrospinal fluid protein concentration of 2.4 g/l with 97 cells, including 60% lymphocytes. The cerebrospinal fluid remained sterile on various culture media, however. Repeated x ray examination of the lumbar spine, performed three weeks after the initial admission to hospital, showed further narrowing of the L4-5 disc space with erosions of adjacent bone end plates of the L4 and L5 vertebrae suggesting osteomyelitis. Computed tomography confirmed the lesions with swelling of the surrounding soft tissues (fig 2).

Results of two dimensional echocardiography were normal. Culture of a discverte-

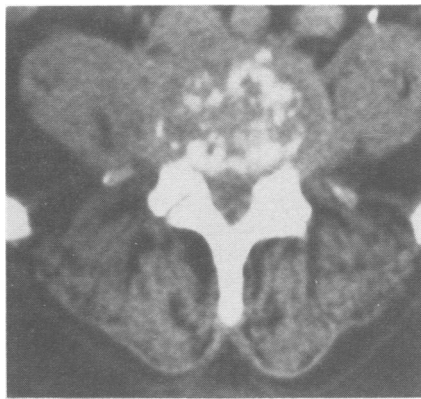

Figure 2 Computed tomography scan obtained three weeks after admission to hospital showing multiple bone erosions of the superior vertebral end plate of L5 with swelling of the surrounding soft tissues.

bral biopsy specimen showed *H aphrophilus* on CO<sub>2</sub> enriched medium. The patient was then treated with active antibiotics: intravenous pefloxacin (800 mg/day) and netilmicin for the first four weeks followed by oral pefloxacin alone for another eight weeks. Currently (six months later) the patient is walking and has no back pain.

The most interesting point in this case was the misdiagnosis due to the presence of a vacuum phenomenon. The presence of a vacuum phenomenon in the intervertebral disc space usually confirms the diagnosis of degenerative disease and is useful in eliminating the diagnosis of infection.<sup>3</sup> However, radiolucent collections are rarely seen in infections,<sup>4</sup> essentially when the organism produces gas as a result of its metabolism, a condition associated with *H aphrophilus* which requires high concentrations of CO<sub>2</sub> for its growth.<sup>1,2</sup> Therefore, the presence of a vacuum phenomenon may lead to a false sense of security. In such cases magnetic resonance imaging may detect the spondylodiscitis earlier.<sup>5</sup>

*H aphrophilus* is a commensal organism found in oral flora, especially in the mouth (interdental material and dental plaque).<sup>2</sup> An association between infections due to *H aphrophilus* and the oropharynx and between such infections and a previous history of dental disease or manipulation has been previously reported.<sup>2</sup> A review of publications found only five reported cases<sup>6-9</sup> of osteoarticular infections due to *H aphrophilus*, including two cases of spondylodiscitis<sup>7,8</sup> and one case of spinal epidural abscess.<sup>9</sup> *H aphrophilus* is reported to be sensitive to a broad range of commonly used antibiotics, including fluoroquinolones as in our case.<sup>2</sup>

XAVIER CHEVALIER  
BRUNO LARGET-PIET  
Department of Rheumatology  
Hopital Henri-Mondor  
Creteil, France

Correspondence to: Dr X Chevalier, CCA, Service de Rhumatologie, Bd de Latre de Tassigny 94010 Creteil, France.

- 1 Sutter V L, Finegold S M. *Haemophilus aphrophilus* infection: clinical and bacteriological studies. *Ann NY Acad Sci* 1970; 174: 468-84.
- 2 Bierger R C, Brewer N S, Washington M D. *Haemophilus aphrophilus*: a microbiologic and clinical review and report of 42 cases. *Medicine (Baltimore)* 1978; 57: 345-55.
- 3 Resnick D L, Niwayama G, Guera J Jr, Vint V, Usselman J. Spinal vacuum phenomenon:

anatomical study and review. *Radiology* 1981; 137: 341-8.

- 4 Bielicki D K, Sartoris D, Resnick D, Van Lom K, Fierer J, Haghighi P. Intraosseous and intra discal gas association with spinal infection: report of three cases. *Am J Roentgenol* 1986; 147: 83-6.
- 5 Modic M T, Feiglin D H, Piraino D W, et al. Vertebral osteomyelitis: assessment using MR. *Radiology* 1985; 157: 157-66.
- 6 Ho J L, Soukiasian S, Oh W H, Snyderman D R. *Haemophilus aphrophilus* osteomyelitis. *Am J Med* 1984; 76: 159-61.
- 7 Houssiau F A, Huaux J P, Nagant de Deuchaisnes C. *Haemophilus aphrophilus*: a rare pathogen in vertebral osteomyelitis. *Ann Rheum Dis* 1987; 46: 248-50.
- 8 Page M I, King E O. Infection due to actinomycetomycetans and *Haemophilus aphrophilus*. *N Engl J Med* 1966; 275: 181-8.
- 9 Gaudin P, Zagala A, Juvin R, et al. Abscès épidual à *Haemophilus aphrophilus* avec étude en résonance magnétique nucléaire. *Ann Med Interne (Paris)* 1989; 11: 68-9.

## Idiopathic orbital myositis: treatment with cyclosporin

SIR: Idiopathic orbital myositis is a relatively rare variant of orbital pseudotumour. A search of published work did not disclose any references to the management of idiopathic orbital myositis with cyclosporin. Similarities between the muscle lesions in this process and in polymyositis (recognised to be successfully treated by this drug), however, led to our decision to start cyclosporin treatment of a patient with steroid resistant idiopathic orbital myositis.

In December 1987 a 31 year old woman experienced an episode of right eye pain with redness as well as swollen lids and conjunctiva. Ocular movements enhanced the pain. No other symptoms were noted and results of a clinical examination were entirely normal. Results of the following laboratory tests were normal: blood count, erythrocyte sedimentation rate, glucose, urea nitrogen, electrolytes, serum protein electrophoresis, bilirubin, alkaline phosphatase, serum muscle enzymes, serum complement, cryoglobulins, antinuclear antibodies, rheumatoid factor, and thyroid function. Computed tomography (CT) scanning detected a fusiform enlargement of the right internal rectus muscle extending anteriorly to affect the tendon inserting on the globe, accompanied by slight exophthalmos. No left orbit abnormalities were seen (figure A). Rapid improvement followed the start of prednisone treatment (30 mg/d) in March 1988, but all attempts to reduce the steroid dose resulted in a new burst of activity. For this reason, and owing to the appearance of hyperglycaemia and signs of hypercorticism, azathioprine (100 mg/d) was added to the treatment. Further attempts to taper the steroid dose invariably met with a recurrence of the process. In September 1989, after another relapse following the withdrawal of steroids but not azathioprine, the treatment was changed to oral cyclosporin (3.5 mg/kg daily). The clinical manifestations immediately improved and five months later the patient was asymptomatic and no adverse secondary effects had been recorded. A new CT scan showed complete regression of the myositis (figure B).

Orbital pseudotumours are a group of noneoplastic processes that produce intra-orbital mass lesions.<sup>1</sup> Idiopathic orbital myositis, a subgroup of orbital pseudotumour, is characterised by inflammatory infiltration of one or more extraocular muscles.<sup>2,3</sup> Although

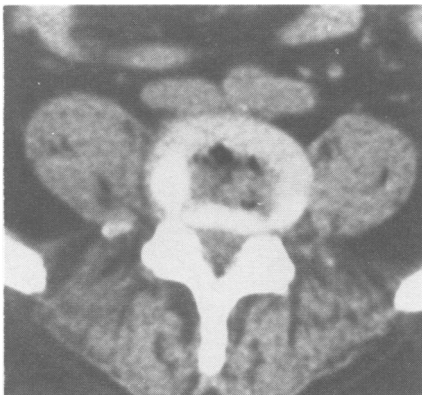

Figure 1 Gas in the L4-5 intervertebral disc space shown by computed tomography.

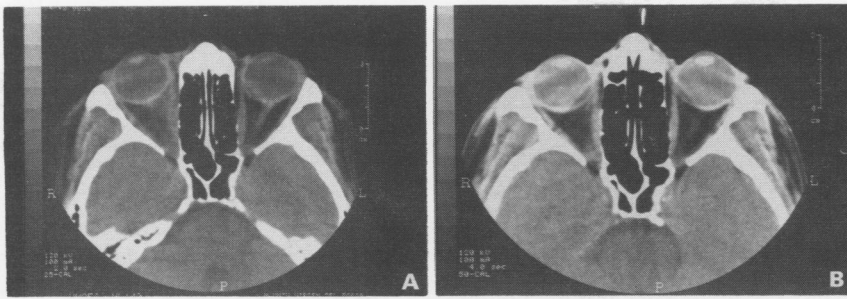


Figure 1 (A) Orbital computed tomography scan showing fusiform enlargement of the right internal rectus muscle. (B) Complete regression of the myositis after cyclosporin treatment.

its origin remains unclear, immunological mechanisms have been postulated. Seldom has orbital myositis been reported in association with autoimmune diseases, such as systemic lupus erythematosus,<sup>4</sup> Wegener's granulomatosis,<sup>5</sup> or viral syndrome.<sup>6</sup> The cardinal feature of this disease is an acute, afebrile, unilateral onset with bulbar pain intensified by ocular movement. Alternatively, there may be ophthalmoplegia, chemosis, proptosis, blepharoptosis, and conjunctival infection.<sup>2,7</sup> Differentiating from other orbital pseudotumors (especially from thyroid ophthalmopathy, carotid-cavernous fistulae, orbital cellulitis, and tumours of the orbit) has been simplified by the advent of CT and nuclear magnetic resonance imaging.<sup>7,8</sup> A fusiform enlargement of the affected muscle is usually detected in a CT scan: extension of this process to the zone of insertion into the ocular globe (tendon sign),<sup>9</sup> although not consistently found, is specific for idiopathic orbital myositis and is not seen in dysthyroid myopathy. In contrast with the latter disorder, idiopathic orbital myositis is usually unilateral and only one muscle is affected (generally the internal rectus).<sup>8,9</sup> Idiopathic orbital myositis responds rapidly to steroid treatment with no residual sequelae.<sup>7,8</sup> Nevertheless, some patients have a chronic and recurrent course with fibrotic muscle transformation and permanent loss of ocular motility.<sup>3</sup> Clinical and radiological features in our patient were absolutely characteristic of idiopathic orbital myositis. However, the multiple relapses which occurred upon attempting to cut back the steroids, even when associated with azathioprine, made us look for an alternative treatment. The use of cyclosporin in ophthalmic Graves' disease is well documented,<sup>10</sup> but no references have been made to its use in idiopathic orbital myositis. Reported favourable results obtained in patients with polymyositis,<sup>11</sup> and our own experience, led us to use it successfully in our patient. We consider cyclosporin to be a valuable alternative for patients who develop dependency on steroids or who cannot tolerate or are resistant to such treatment.

J SÁNCHEZ-ROMÁN  
J M VARELA-AGUILAR  
J BRAVO-FERRER  
Collagenosis Unit  
Department of Medicine  
Virgen del Rocío University Hospital,  
Sevilla, Spain

E SEQUEIROS MADUENO  
Department of Ophthalmology  
Virgen del Rocío University Hospital,  
Sevilla, Spain

M FERNÁNDEZ DE BOBADILLA  
Department of Radiology  
Virgen del Rocío University Hospital,  
Sevilla, Spain

Correspondence to:  
Dr Julio Sánchez Román,  
Plaza San Martín nº 3, F-2,  
41003 Sevilla, Spain.

- Birch-Hirschfeld A. Zur Diagnostik und Pathologie der Orbitaltumoren. *Berichte der Deutsche Ophthalmologische Gesellschaft* 1905; 32: 127-35.
- Bach M C, Knowland M, Schuyler B J. Acute orbital myositis mimicking orbital cellulitis. *Ann Intern Med* 1988; 109: 243-45.
- Bullen C L, Young B R. Chronic orbital myositis. *Arch Ophthalmol* 1982; 100: 1749-51.
- Grimson B S, Simons K B. Orbital inflammation myositis and systemic lupus erythematosus. *Arch Ophthalmol* 1983; 101: 736-8.
- Cassan S M, Divertrie M B, Hollenhorst R W, Harrinson E G Jr. Pseudotumor of the orbit and limited Wegener's granulomatosis. *Ann Intern Med* 1970; 72: 687-93.
- Purcell J J Jr, Taulbee W A. Orbital myositis after upper respiratory tract infection. *Arch Ophthalmol* 1981; 99: 437-8.
- Dresner S C, Rothfus W E, Slamovits T L, Kennerdell J S, Curtin H D. Computed tomography of orbital myositis. *AJR* 1984; 143: 671-4.
- Dua H S, Smith F W, Singh A K, Forrester J V. Diagnosis of orbital myositis by nuclear magnetic resonance imaging. *Br J Ophthalmol* 1987; 71: 54-7.
- Trokel S L, Hilar S K. Recognition and differential diagnosis of enlarged extraocular muscles in computed tomography. *Am J Ophthalmol* 1979; 87: 503-12.
- McGregor A M, Beck M, Weetman A P, Hall R. Cyclosporin in the management of Graves' ophthalmopathy. In: Schindler R, ed. *Cyclosporin in autoimmune diseases*. Berlin: Springer, 1985: 229-34.
- Alijotas J, Barquinero J, Ordi J, Vilardell M. Polymyositis and cyclosporin A. *Ann Rheum Dis* 1990; 49: 66-7.

## Non-Hodgkin's lymphoma: initial manifestation

Sir: Skeletal involvement frequently occurs in malignant lymphoma,<sup>1</sup> but monoarthritis and polyarthritis are uncommon and are usually considered to be synovial reactions secondary to adjacent bone disease.<sup>2-4</sup> We report the case of an elderly woman who presented with seronegative symmetrical synovitis and pitting oedema, resembling the 'RS3PE' syndrome described by McCarty *et al*,<sup>5</sup> in whom non-Hodgkin's lymphoma became apparent subsequently.

A 63 year old woman presented in November 1989 with sudden onset of swelling of her metacarpophalangeal joints, knees, and feet; morning stiffness of hands of more than one hour; and oral ulcerations. Examination showed tenderness or swelling, or both, of all hand joints, flexor digitorum tendons, wrists, carpal joints, knees, and tarsal joints. Pitting oedema of the dorsum of hands and feet was seen bilaterally. There was no evidence of lymphadenopathy or hepatosplenomegaly. Roentgenograms of the hands and feet showed soft tissue swelling but no erosions or joint space narrowing. Results of routine laboratory studies were normal. Rheumatoid factor, antinuclear antibodies, and precipitin tests for antibodies to Sm, nRNP, Ro, and La antigens

were absent. C3, C4, and lactate dehydrogenase were normal.

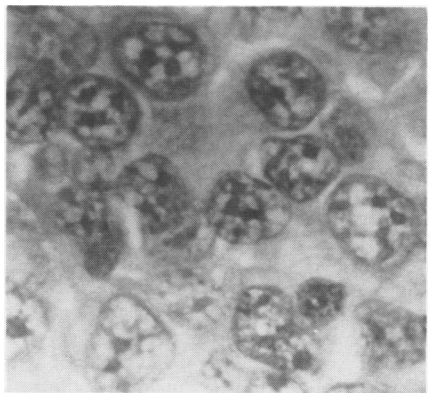
She was treated with hydroxychloroquine 200 mg twice a day, salicylates in anti-inflammatory doses and, later, with prednisone 5 mg daily, without symptomatic improvement.

In March 1990 several cervical, axillary and inguinal lymph nodes became enlarged, her temperature rose to 38.3-39.2°C, and she lost weight progressively. Results of laboratory tests were negative or normal, except for lactate dehydrogenase: 250 U/ml (normal range 83-157 U/ml) and erythrocyte sedimentation rate: 89 mm/hour. A biopsy specimen of a laterocervical lymph node showed diffuse large cell lymphoma (figure) and synovial biopsy of a metacarpophalangeal joint disclosed non-specific synovitis without lymphomatous cell infiltration. A computed tomographic scan of the abdomen and chest showed several anterior mediastinal, pre-tracheal, coeliac, portal, mesenteric, para-aortic, hepatic hilar, renal hilar, and retroperitoneal lymph nodes greater than 1.5-2 cm and hepatosplenomegaly. Results of a technetium-99m bone scan were normal. Bilateral iliac crest bone marrow biopsy specimens did not show malignant infiltration.

The patient was treated with six series chemotherapy according to the IMVP-16 regimen (ifosfamide 1 g/m<sup>2</sup> for five days, methotrexate 30 mg/m<sup>2</sup> for two days, and etoposide 100 mg/m<sup>2</sup> for three days over a period of 21 days). The oedema and synovitis resolved after two cycles of this protocol. Two years after treatment was stopped she remains in complete haematological remission and has no signs or symptoms of rheumatic disease.

Although uncommon, polyarthritis is well recognised in lymphoma. The interest of this case lies in the associated pitting oedema and tentative diagnosis of 'RS3PE' syndrome. In 1985 McCarty *et al* described eight elderly men and two elderly women who presented with symmetrical polysynovitis of acute onset, affecting most of their appendicular joints and flexor digitorum tendons with pitting oedema of the dorsum of both hands and both feet.<sup>5</sup> Rheumatoid factors were absent from serum samples in all, and no radiologically evident erosions developed. They believed that this disease represented a distinct subset of 'seronegative rheumatoid arthritis', with a predictable course to complete remission.

In our patient the first signs and symptoms of non-Hodgkin's lymphoma resembled this syndrome. Little symptomatic improvement



Histological section of a cervical lymph node biopsy specimen, showing large lymphoid cells with vesicular nuclei that have two to four small to medium sized nucleoli, often adjacent to the nuclear membrane. The cytoplasmic borders are not clearly outlined. (Haematoxylin-eosin stain.)