

# HLA antigen familial study in complete Behçet's syndrome affecting three sisters

J L Villanueva, J Gonzalez-Dominguez, R Gonzalez-Fernandez, J L Prada, J Peña, R Solana

## Abstract

Behçet's disease is a multisystemic disease affecting most organs. Although a tendency towards an association with a certain genetic type and with HLA-B51 is suspected, the incidence of several siblings with Behçet's disease in a single family is rare. A family, in which three sisters were affected with Behçet's disease, uveitis being the most severe manifestation, was studied. In this family all siblings were B51 positive. Only the female siblings, however, with a positive identical HLA phenotype: A2, A11, B51, B44, Cw6, Cw5, DR4, DRw13, DRw53, DRw52, DQw7, DQw6, developed the disease symptoms, whereas none of the male siblings was affected.

(*Ann Rheum Dis* 1993; 52: 155-157)

Behçet's syndrome is a multisystemic disease which may affect many organs. The diagnosis is based on clinical manifestations in at least three or four cardinal organs: oral and genital ulcers, skin lesions, and ocular disease.<sup>1</sup> Most patients with Behçet's syndrome are of Oriental or Mediterranean origin.

A close association of HLA-B5 and more recently of its split B51 was reported from Turkey<sup>2</sup> and Japan.<sup>3</sup> Nevertheless, a genetic cause is still debatable.<sup>4</sup> We report on a Spanish family with Behçet's syndrome and show the HLA typing of all family members.

Familial involvement has been reported,<sup>5 6</sup> but as far as we know complete Behçet's syndrome in all female siblings of a family in which all male siblings were free from symptoms has never been published.

## Patients

The figure shows the pedigree of the family and the table the clinical features of affected siblings.

II-1 The proband, a 22 year old woman had had mouth ulcers when she was 17 years old. In recent years she developed recurrent oral and vulvar ulcerations, and erythema nodosum. At the age of 20 she was admitted to hospital with severe bilateral posterior uveitis with unilateral vitreal haemorrhage. Physical examination showed orogenital ulceration and posterior uveitis. Tests for the presence of rheumatoid factor (RF), antinuclear antibodies (ANA), anti-dsDNA, and IgG anticardiolipin (aCL)

Service of Internal  
Medicine, Hospital  
Regional Universitario  
Reina Sofia, Cordoba,  
Spain

J L Villanueva  
J L Prada

Rheumatology Section,  
Hospital Regional  
Universitario Reina  
Sofia, Cordoba,  
Spain

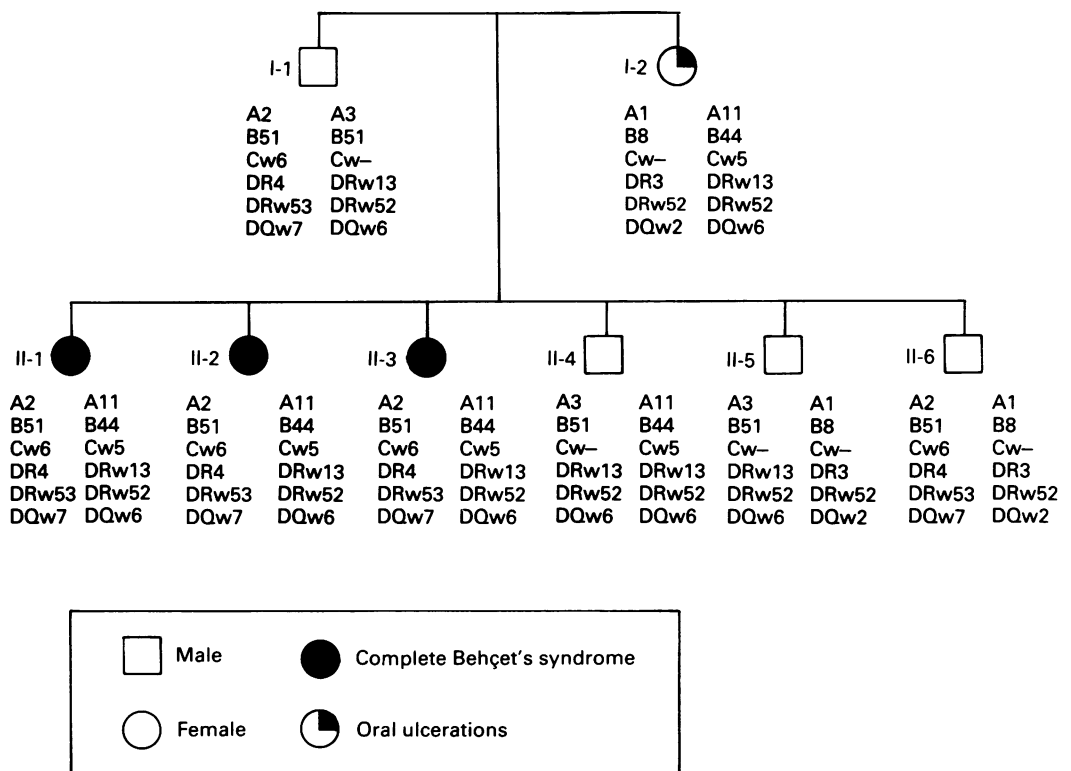
J Gonzalez-Dominguez

Service of Immunology,  
Hospital Regional  
Universitario Reina  
Sofia, Cordoba,  
Spain

R Gonzalez-Fernandez  
J Peña  
R Solana

Correspondence to:  
Dr Rafael Solana,  
Department of Immunology,  
Faculty of Medicine,  
Av Menendez Pidal s/n,  
14004 Cordoba, Spain.

Accepted for publication  
9 September 1992



Pedigree of the family with indications of the HLA phenotypes and the symptoms related to Behçet's syndrome.

*Clinical features of the siblings affected with Behçet's syndrome*

Patient code	Recurrent ulceration	Eye lesions	Skin lesions
II-1	Oral, genital	Posterior uveitis Vitreous haemorrhage	Erythema nodosum
II-2	Oral, genital	Posterior uveitis	Erythema nodosum
II-3	Oral, genital	Anterior uveitis	Erythema nodosum

antibodies were negative. A diagnosis of complete Behçet's syndrome was made and she was treated with cyclosporin A 5 mg/kg/daily; ocular symptoms recurred when cyclosporin was withdrawn. Tissue typing, performed by the NIH technique, was HLA-A2, A11, B51, B44, Cw6, Cw5, DR4, DRw13, DRw53, DRw52, DQw7, DQw6.

II-2 This 28 year old sister of the above patient had a six year history of orogenital ulceration and erythema nodosum and a past history of two abortions. Ophthalmological examination showed unilateral posterior synechial uveitis. Tests for the presence of RF, ANA, anti-dsDNA, and IgG aCL antibodies were negative. A diagnosis of complete Behçet's syndrome was made. She was treated with prednisone 40 mg/day and her symptoms were relieved. HLA phenotype was HLA-A2, A11, B51, B44, Cw6, Cw5, DR4, DRw13, DRw53, DRw52, DQw7, DQw6.

II-3 The third sister, aged 26, had had recurrent aphthous stomatitis and genital ulcers from the age of 22, and recurrent erythema nodosum was also present. Examination detected unilateral anterior uveitis. Tests for the presence of RF, ANA, anti-dsDNA, and IgG aCL antibodies were negative. This patient also fulfilled the criteria for diagnosis of Behçet's syndrome. She was treated with prednisone and her symptoms remitted in two weeks. Tissue typing was HLA-A2, A11, B51, B44, Cw6, Cw5, DR4, DRw13, DRw53, DRw52, DQw7, DQw6.

The patient's three brothers (II-4, II-5, and II-6, aged 34, 31, and 25 respectively) were symptom free. Repeated physical and ocular examination of the three brothers every six months did not show any symptoms of Behçet's syndrome. HLA phenotypes were II-4: A3, A11, B51, B44, Cw5, DRw13, DRw52, DQw6; II-5: A3, A1, B51, B8, DRw13, DR3, DRw52, DQw6, DQw2; and II-6: A2, A1, B51, B8, Cw6, DR4, DR3, DRw53, DRw52, DQw7, DQw2.

The patient's father (I-1, aged 65) was also symptom free. HLA phenotype was A2, A3, B51, Cw6, DR4, DRw13, DRw53, DRw52, DQw7, DQw6.

The patient's mother (I-2, aged 62) had a history of oral ulcers but no other symptoms of Behçet's disease. HLA phenotype was A1, A11, B8, B44, Cw5, DR3, DRw13, DRw52, DQw2, DQw6.

### Discussion

In this study the three sisters of the family (patients II-1, II-2, and II-3) had complete Behçet's syndrome.<sup>1</sup> The proband's mother (I-2) had one of the four major symptoms of the

disease: recurrent oral ulcers, but no other symptoms were reported. The rest of the family were free from symptoms. A familial incidence of Behçet's syndrome has been rarely reported in different ethnic groups.<sup>4-6</sup> In this family it is remarkable that only the female siblings were affected, all of them with complete Behçet's syndrome including severe uveitis, though it has been reported that uveitis is more prevalent in men.<sup>7</sup> Because of the severe ocular disease, patient II-2 required extended cyclosporin A treatment.

The cause of Behçet's syndrome is unknown, though the association between HLA phenotypes in Behçet's syndrome is significant. HLA-B51 may serve as an immunogenetic marker for a subgroup of patients with Behçet's syndrome in Israeli,<sup>8</sup> Japanese,<sup>3</sup> and Turkish patients.<sup>2</sup> In European patients, however, this association is not obvious.<sup>4</sup> Investigations of HLA class II antigens<sup>9</sup> in Behçet's syndrome has shown a correlation with the DR2 and DR7 antigens. In Japanese and Italian patients an increased expression of HLA-B51 and HLA-DRw52 has been reported.<sup>10 11</sup> Increased expression of HLA-DQw3 has been found in Japanese<sup>12</sup> and Tunisian patients.<sup>13</sup> Restriction fragment length polymorphism analysis has suggested an association of a particular DQw3 pattern with refractory Behçet's disease.<sup>14</sup> Other studies in North American and Italian patients, however, have shown no association between HLA class II antigens and Behçet's disease.<sup>15</sup>

In our familial study the affected patients have identical HLA typing sharing both haplotypes, whereas the non-affected siblings share only one maternal (II-4), paternal (II-6), or no (II-5) haplotype of their sisters. These results support the hypothesis that different HLA linked genetic factors may contribute to the onset of the disease. In this family all siblings are HLA-B51, as the father is homozygous B51. However, this disease only affected female siblings who had the haplotype A2, B51, Cw6, DR4, DRw53, DQw7. The father (I-1) and one brother (II-6) also had this haplotype, but they had no clinical symptoms of Behçet's syndrome. The particular involvement of female subjects might be related to hormonal factors or to the inclusion of the maternal haplotype A11, B44, Cw5, DRw13, DRw52, DQw6. This haplotype or the presence of the antigen HLA-B44 might be associated with the presence of oral ulcers in the mother. Although we cannot establish a particular HLA gene, our findings lend support to the suggestion that the association of Behçet's disease with certain HLA antigens<sup>3</sup> is multifactorial.

We thank Professor D BenEzra (Department of Ophthalmology, Haddassah University Hospital, Jerusalem, Israel) for encouragement and helpful suggestions.

- 1 International study group for Behçet's disease. Criteria for diagnosis of Behçet's disease. *Lancet* 1990; 355: 1078-80.
- 2 Muftuoglu A U, Yazici H, Yurdakul S, et al. Behçet's disease. Lack of correlation of clinical manifestations with HLA antigens. *Tissue Antigens* 1981; 17: 226-30.
- 3 Ohno S, Ohguchi M, Hiro S E, et al. Close association of HLA Bw51 with Behçet's disease. *Arch Ophthalmol* 1982; 100: 1455-8.
- 4 Bird Steward J A. Genetic analysis of families of patients with

- Behçet's syndrome: data incompatible with autosomal recessive inheritance. *Ann Rheum Dis* 1986; 45: 265-8.
- 5 Goolamali S K, Comaish J S, Hassanyeh F, Stephens A. Familial Behçet's syndrome. *Br J Dermatol* 1976; 95: 637-42.
  - 6 Fallingborg J, Christensen L D, Grunnet N. HLA antigens in a family with Behçet's syndrome. *Acta Med Scand* 1986; 220: 375-8.
  - 7 BenEzra D, Nussenblatt R B. Ocular manifestations of Behçet's disease. *J Oral Pathol* 1987; 7: 431-5.
  - 8 Chajek-Shaul T, Pisanty S, Kobler H, et al. HLA B51 may serve as an immunogenetic marker for a subgroup of patients with Behçet's syndrome. *Am J Med* 1987; 83: 666-78.
  - 9 Lehner T, Welsh K I, Batchelor J R. The relationship of HLA B and DR phenotypes to Behçet's syndrome, recurrent oral ulceration and the class of immune complexes. *Immunology* 1982; 47: 581-7.
  - 10 Ohno S, Matsuda H. Studies of HLA antigens in Behçet's disease in Japan. In: Lehner T, Barnes C G, eds. *Recent advances in Behçet's disease*. London: Royal Society of Medicine Services, 1986: 11-15.
  - 11 Baricordi O R, Sensi A, Pizetti-Pezzi P, et al. Behçet's disease associated with HLA B51 and DRw52 antigens in Italians. *Hum Immunol* 1986; 17: 297-301.
  - 12 Matsuki K, Juji T, Totunaga K, et al. HLA antigens in Behçet's disease with refractory ocular attacks. *Tissue Antigens* 1987; 29: 208-13.
  - 13 Hamza M, Ayed K, Bardi R, Gorgi Y, Meddeb N. Maladie de Behçet et antigens classes II et III des complexe majeur d'histocompatibilite. *Rev Rhum Mal Osteoartic* 1990; 57: 59-61.
  - 14 Numaga J, Matsuki K, Mochizuki M, Minami M, Juji T. An HLA-D region restriction fragment associated with refractory Behçet's disease. *Am J Ophthalmol* 1988; 105: 528-33.
  - 15 Moore S B, O'Duffy J D. Lack of association between Behçet's disease and major histocompatibility complex class II antigens in an ethnically disease North American caucasoid patients group. *J Rheumatol* 1986; 13: 771-3.