

# Zonal distribution of chondroitin-4-sulphate/dermatan sulphate and chondroitin-6-sulphate in normal and diseased human synovium

J G Worrall, L S Wilkinson, M T Bayliss, J C W Edwards

## Abstract

**Objectives**—Chondroitin sulphate is the major sulphated glycosaminoglycan present in the extracellular matrix of soft connective tissues and the aim of this study was to investigate the distribution of chondroitin sulphate species in normal and diseased synovium.

**Methods**—Distribution of chondroitin-4-sulphate/dermatan sulphate (Ch4S/DS) and chondroitin-6-sulphate in normal (n = 6), osteoarthritic (n = 4) and rheumatoid (n = 10) synovium was determined using an immunoperoxidase technique and specific monoclonal antibodies to chondroitinase ABC-digested preparations.

**Results**—Ch4S/DS was expressed throughout the interstitium of all tissues and was also present on blood vessels in rheumatoid samples only. Ch6S was expressed in the lining layer of normal synovium but was absent from this site in osteoarthritic and rheumatoid tissues. Ch6S was also present on all blood vessels in all tissues.

**Conclusions**—The distinct zonal distributions of Ch4S/DS and Ch6S and their alteration in disease suggest these molecules have different and specific functions in normal and diseased synovium.

(*Ann Rheum Dis* 1994; 53: 35–38)

The glycosaminoglycans (GAGs) chondroitin, dermatan, keratan, heparan and hyaluronan are widely distributed in vertebrate tissues where they most notably contribute to the gel component of tissue extracellular matrix.<sup>1</sup> GAGs are polysaccharides comprising unbranched chains of repeating disaccharide units. All GAGs except hyaluronan may carry sulphate groups and are covalently linked at the terminal reducing end, via a neutral trisaccharide, to core proteins of various sizes to form proteoglycans. Chondroitin sulphate proteoglycan, the most widely distributed proteoglycan, occurs in a number of forms varying in site and degree of sulphation. Dermatan sulphate is an isomer of chondroitin-4-sulphate in which a variable number of glucuronic acid residues are replaced with iduronic acid. Chondroitin-4-sulphate/dermatan sulphate (Ch4S/DS) and chondroitin-6-sulphate (Ch6S) are the

predominant forms; naturally-occurring un-sulphated and over-sulphated forms are also recognised.<sup>2</sup>

GAGs are heavily hydrated and appear to be important in the maintenance of tissue water content. Chondroitin sulphate and hyaluronan fill the interstices of the fibrous network responsible for tissue integrity. Chondroitin sulphate and hyaluronan also bind to receptors on cell surfaces and may be important in cellular adhesion and migration within connective tissue. Little is known of the specific functions of individual chondroitin sulphate species but Ch4S/DS and Ch6S show restricted and characteristic tissue distributions, indicating functional specialisation. Ch6S is a component of basement membranes.<sup>3–5</sup> Ch4S/DS is present in collagenous interstitial matrix and is expressed on high endothelial venules.<sup>6</sup>

The extracellular matrix of synovium is specialised in terms of its mechanical properties and filtration characteristics to facilitate articular movement.<sup>7–8</sup> GAGs are likely to contribute to these functions and their distribution in the tissue may be significant. Hyaluronan, which is responsible for the rheological properties of synovial fluid, is concentrated in the superficial interstitial matrix of normal synovium<sup>9</sup> but the distribution of chondroitin sulphate species has not been analysed in detail. The recent availability of monoclonal antibodies to specific epitopes on Ch4S/DS and Ch6S proteoglycans exposed by chondroitinase ABC digestion<sup>10–11</sup> has facilitated detailed assessment of their morphological distribution in tissue. Striking differences in the distributions of these structurally very similar molecules have been identified in skin,<sup>12</sup> skeletal muscle<sup>13</sup> and embryonic tissues.<sup>2</sup> Using these monoclonal antibodies we report the distributions of Ch4S/DS and Ch6S in normal human synovium and assess the changes associated with inflammatory disease.

## Materials and methods

### 1 TISSUES

Specimens of normal synovium were obtained from macroscopically normal distal joints of limbs amputated for proximal malignancy. Diseased synovium was obtained from patients with rheumatoid arthritis (RA) undergoing arthrotomy, arthroscopy or tenosynovectomy

Rheumatology  
Research,  
University College and  
Middlesex School of  
Medicine,  
London W1P 9PG,  
United Kingdom

J G Worrall  
L S Wilkinson  
J C W Edwards

Kennedy Institute of  
Rheumatology,  
London W6 7DW,  
United Kingdom  
M T Bayliss

Correspondence to:  
Dr J G Worrall,  
Rheumatology Research,  
UCMSM,  
Arthur Stanley House,  
Tottenham Street,  
London W1P 9PG,  
United Kingdom.

Accepted for publication  
2 September 1993

and from patients with osteoarthritis (OA) undergoing replacement arthroplasty or arthroscopy. Patients with RA all satisfied the American Rheumatism Association criteria for RA.<sup>14</sup> Patients with OA all showed radiological features typical of OA together with a normal Westergren erythrocyte sedimentation rate and absence of rheumatoid factor in the serum. All synovia were dissected free of underlying fat and capsule. Five millimetre blocks of fresh tissue were snap frozen in isopentane in a bath of solid carbon dioxide and stored at  $-70^{\circ}\text{C}$  until use. Six normal, four OA and 10 RA specimens, all from different individuals, were examined in this study.

### 2 MONOCLONAL ANTIBODIES

The monoclonal antibodies (Mabs) used in this study were the gift of Dr B Caterson. 2B6 (also known as 9A2) is a mouse IgG and marks Ch4S/DS; 3B3 is a mouse IgM and marks Ch6S. Details of production and specificity of the antibodies are given elsewhere.<sup>10-11</sup> Each antibody recognises the disaccharide stub remaining attached, via the neutral link trisaccharide, to core protein after digestion of the tissue proteoglycan with chondroitinase ABC. The irrelevant Mabs employed as controls were an antimyeloperoxidase IgG which was the gift of Dr G Cambridge and an anti-pancreatic lipase (QED Monoclonals, USA) which is a mouse IgM.

### 3 IMMUNOHISTOCHEMISTRY

Serial cryostat sections seven microns thick were dried under a cool fan for one hour and fixed for 10 minutes in acetone kept at  $-20^{\circ}\text{C}$ . Sections were air-dried, rehydrated in phosphate-buffered saline (PBS) and then incubated for one hour at  $37^{\circ}\text{C}$  with chondroitinase ABC (ICN Biochemicals, USA) at 0.2 units/ml in Tris-acetate buffer (TAB), pH 7.3. Sections were then incubated for one hour with anti-chondroitin sulphate Mabs, each at a dilution of 1:100 in TAB. Endogenous tissue peroxidase was inactivated by treatment with 2% hydrogen peroxide in methanol for five minutes. Sections were then incubated with rabbit anti-mouse immunoglobulins conjugated to horseradish peroxidase (Dako, UK) for 30 minutes at room temperature. Colour was developed using diaminobenzidine tetrachloride (Sigma Chemical, UK) at 0.5 mg/ml in PBS with  $1\ \mu\text{l/ml}$  of 30% hydrogen peroxide. Sections were thoroughly washed in PBS between incubations and unless otherwise stated all incubations were at room temperature. Controls consisted of tissue sections processed as above but incubated with irrelevant Mabs of the same isotypes as the anti-chondroitin sulphate antibodies. Other control sections were processed as above except that either Mabs or digestion with chondroitinase ABC was omitted. Serial sections stained with haematoxylin and eosin were included to demonstrate cellular organisation of the tissue.

## Results

The findings were remarkably consistent between different specimens within the normal, osteoarthritic and rheumatoid groups and did not appear to show significant variation with patient characteristics such as age, sex, disease duration and anti-rheumatic drug therapy.

### 1 CHONDROITIN-4-SULPHATE/DERMATAN SULPHATE PROTEOGLYCAN

In most normal synovia, Ch4S/DS was distributed homogeneously throughout the interstitial matrix of the deep tissue and of the lining layer (fig 1A). However, in one tissue with a densely cellular lining layer, Ch4S/DS staining was reduced in this layer but increased in a band immediately deep to it. In RA synovium (fig 1B), lining layer Ch4S/DS was consistently reduced compared with deeper layers. Ch4S/DS localised to collagen showed the fibrous elements of the interstitial matrix, both superficial and deep, to be of variable thickness, widely separated and orientated in all directions in contrast to the compact, regular, parallel pattern of normal tissue. In OA synovium (not shown), Ch4S/DS was homogeneously distributed throughout the superficial and deep matrix.

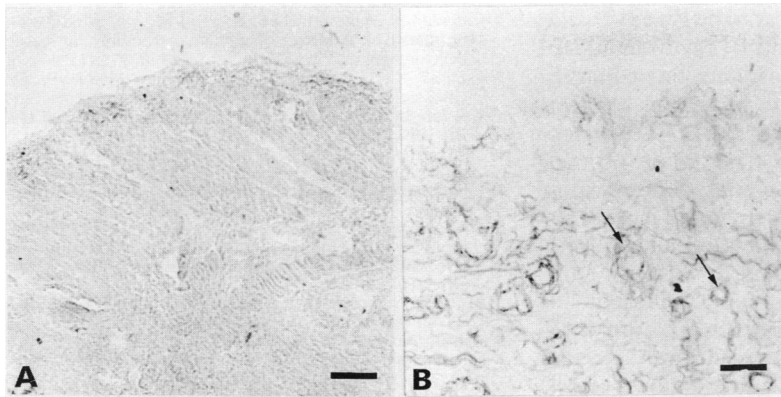
Ch4S/DS was absent from blood vessel intima and media in normal and OA synovium but most vessels showed a faint condensation of Ch4S/DS in the adventitia. In RA synovium many vessels of a variety of sizes showed Ch4S/DS on the luminal aspect and in some cases throughout the vessel wall.

### 2 CHONDROITIN-6-SULPHATE PROTEOGLYCAN

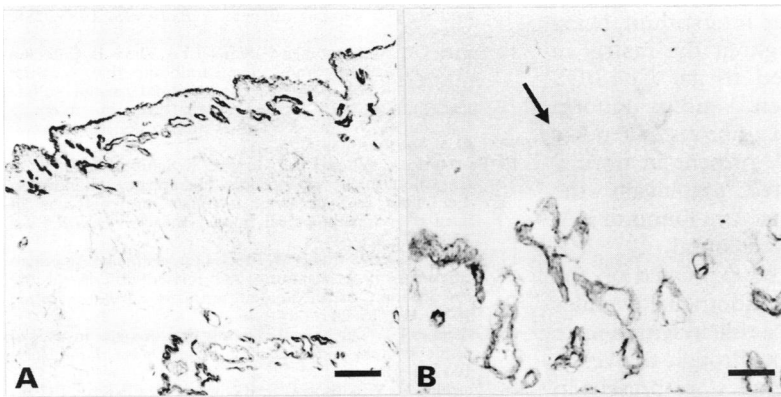
In normal synovium staining for Ch6S was largely concentrated in a band at the tissue surface and the deep interstitial matrix showed only a uniformly distributed faint fibrillar blush. Where the lining layer was sparsely cellular, Ch6S was conspicuous as a dense narrow band at the tissue margin (fig 2A). With increasing cellularity, Ch6S appeared as a wider, less clearly demarcated band enveloping the synovial lining cells. In RA (fig 2B) and OA (not shown) synovium, the bulk of the deep interstitial matrix was negative for Ch6S but there were scattered patches of faint staining. Ch6S was also uniformly absent from the lining layer in both RA and OA, in marked contrast to normal tissue.

Ch6S was seen on blood vessels in normal synovium as a dense narrow band underlying endothelium together with, in larger vessels, a diffuse band outlining the smooth muscle cells of the tunica media. The distribution of Ch6S on blood vessels in RA and OA synovium was similar.

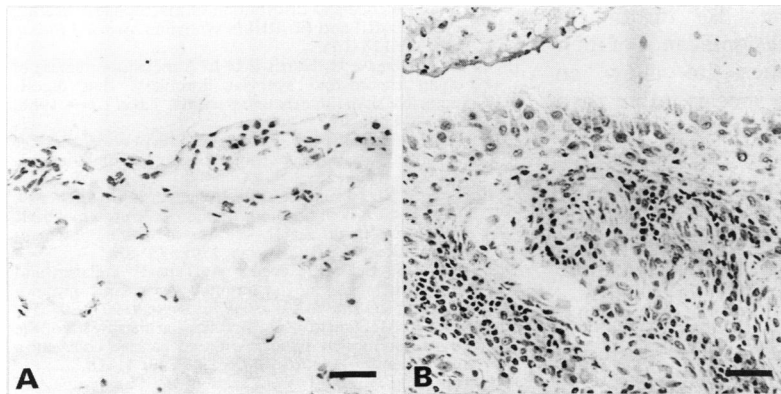
Serial sections stained with haematoxylin and eosin showed the cellular architecture of normal (fig 3A) and RA (fig 3B) synovium. Control tissues incubated with irrelevant Mabs of the same isotypes as the anti-chondroitin sulphate Mabs showed no comparable patterns of staining. Control tissues incubated with the



**Figure 1** Chondroitin-4-sulphate/dermatan sulphate (Ch4S/DS) distribution in normal (A) and rheumatoid (B) synovium (peroxidase developed with diaminobenzidine, bar represents 100  $\mu$ m). Ch4S/DS is distributed homogeneously throughout the interstitial matrix of normal synovium but absent from vessel walls. In rheumatoid synovium, Ch4S/DS is reduced in the lining layer and in the deep layer it is localised to fibrous elements of the matrix and vessel walls (arrows).



**Figure 2** Chondroitin-6-sulphate (Ch6S) distribution in normal (A) and rheumatoid (B) synovium (peroxidase developed with diaminobenzidine, bar represents 100  $\mu$ m). Ch6S is present as a dense narrow band in the lining layer of normal tissue but is absent from the surface (arrow) of rheumatoid tissue. It is also present in vessel walls in both normal and rheumatoid tissues.



**Figure 3** Normal (A) and rheumatoid (B) synovium stained to show cellular distribution (haematoxylin and eosin, bar represents 100  $\mu$ m).

anti-chondroitin Mabs without previous treatment with chondroitinase showed no staining.

### Discussion

Ch4S/DS and Ch6S are structurally identical other than in the position of the sulphate group but this study shows the two chondroitin sulphate species to be localised in distinctly different areas of synovial tissue. Moreover, the

distribution of each differs considerably from that recently reported for hyaluronan,<sup>9</sup> which differs structurally from unsulphated chondroitin only in the position of a hydroxyl group.

The most widely distributed chondroitin sulphate proteoglycans are decorin and biglycan which together constitute 95% of the proteoglycans in connective tissue matrix.<sup>15</sup> Decorin and biglycan codistribute throughout normal and RA synovial matrix and are generally absent from blood vessels.<sup>16</sup> Clearly, Ch4S/DS may be present on and restricted to one or both of these proteoglycans in normal tissue but in RA tissue, blood vessels express a distinct Ch4S/DS-bearing proteoglycan. Ch6S may be present in the normal lining layer as decorin or biglycan or both but a distinct Ch6S-bearing proteoglycan is clearly present on blood vessels in both normal and diseased tissue.

The preferential distribution of interstitial Ch6S to the synovial lining layer and its disappearance from this site in disease is intriguing. The normal synovial lining cell population comprises fibroblast-like cells with a variable minority of macrophages and it seems likely that the Ch6S seen at this site is synthesised by the fibroblastic cells. This suggestion is supported by the finding of high levels of activity in these cells of uridine diphosphoglucose dehydrogenase (UDPGD), which generates glucuronic acid for incorporation into chondroitin sulphate and hyaluronan.<sup>17</sup> (Hyaluronan is also preferentially distributed to the lining layer, although in a much wider and less well-demarcated band<sup>9</sup>). In RA, macrophages are overwhelmingly predominant in the synovial lining layer<sup>18</sup> and the remaining fibroblastic cells show reduced UDPGD activity compared with normal,<sup>17</sup> indicating down-regulation of GAG synthesis. Increased degradation may also occur; the proteoglycan-degrading metalloproteinase, stromelysin, is synthesised by RA synovial cells.<sup>19</sup> It is possible that similar mechanisms operate in OA.

The role of Ch6S in the superficial interstitium of normal synovium is unclear but there are a number of possibilities. First, Ch6S at this site may play no special role and merely represent contamination from synovial fluid but this seems unlikely as Ch6S levels in normal synovial fluid are low.<sup>20</sup> Secondly, the superficial interstitial matrix may be specialised to support the synovial lining cells in their high rates of metabolic activity. Sulphated GAGs bind growth factors<sup>21</sup> and appear to act as a repository for such molecules in tissue. The presence of growth factors bound to Ch6S in the matrix surrounding the synovial cells may be required for optimal functioning of these active cells. Thirdly, the superficial matrix may be specialised to allow the easy passage of hyaluronan from the immediate vicinity of the lining cells, where it appears to be synthesised, towards and into the synovial cavity. The collagen content of the superficial matrix differs from the deep matrix both in amount and type; there is less collagen present and the

predominant species appear to be type IV<sup>22</sup> and type VI whereas types I and III predominate in the deeper zones.<sup>23</sup> The resultant fine collagen network could provide the minimum support necessary to maintain integrity while rendering the matrix loose and open. Ch6S in the intimal layer may serve to saturate GAG binding sites on the matrix structural elements, so preventing hyaluronan from binding and allowing its unimpeded passage to the tissue surface.

Staining for Ch6S, which is present in basement membranes,<sup>5</sup> particularly those of endothelial and vascular smooth muscle cells, identified all blood vessels and individual vessel staining was present in the expected distribution in both normal and diseased tissues. This suggests that Ch6S content of basement membrane remains unaltered in RA despite evidence for increased vascular permeability.

Ch4S/DS is clearly the major chondroitin sulphate species of the deep interstitium, being densely distributed throughout the matrix in both normal and diseased tissue. Ch4S/DS proteoglycan binds collagen,<sup>24</sup> and its uniform presence on the matrix fibrous elements showed the ordered array present in normal tissue and also illustrated graphically the disruption of matrix architecture found in RA. No major zonal variation was found.

Ch4S/DS is known to be expressed on the luminal surface of high endothelial venules where it is thought to play a role in lymphocyte adhesion before movement through the vessel wall.<sup>6</sup> High endothelial venules are present in RA synovium<sup>25</sup> and the numerous Ch4S/DS-positive blood vessels in RA synovium found in this study may represent high endothelial venules.

Although it is possible to hypothesise on the role of each chondroitin sulphate species in its peculiar location, there is insufficient knowledge of the biological significance of their minor structural differences to allow an understanding of why one species rather than the other should be better suited to a particular role. Nevertheless, the striking zonal distributions of Ch4S/DS and Ch6S in synovium and their differential alteration in disease constitute further strong evidence in favour of functional specialisation by these matrix molecules.

The authors acknowledge the support of the Arthritis and Rheumatism Council and the Wellcome Trust.

<sup>1</sup> Varma R S, Varma R, eds. Glycosaminoglycans and proteoglycans in physiological and pathological processes of body systems. Basel, Switzerland: Karger 1982.

- 2 Caterson B, Mahmoodian F, Sorrell J M, *et al.* Modulation of native chondroitin sulphate structure in tissue development and disease. *J Cell Sci* 1990; **97**: 411–17.
- 3 Kanwar Y S, Hascall V C, Farquhar M G. Partial characterisation of newly synthesised proteoglycans isolated from the glomerular basement membrane. *J Cell Bio* 1981; **90**: 527–32.
- 4 Parthasarathy N, Spiro R G. Characterisation of the glycosaminoglycan component of the renal glomerular basement membrane and its relationship to the peptide portion. *J Biol Chem* 1981; **256**: 507–13.
- 5 Couchman J R, Caterson B, Christner J E, Baker J R. Mapping by monoclonal antibody detection of glycosaminoglycans in connective tissues. *Nature* 1984; **307**: 650–51.
- 6 Aruffo A, Stamenkovic I, Melnick M, Underhill C B, Seed B. CD44 is the principal cell surface receptor for hyaluronan. *Cell* 1990; **61**: 1303–13.
- 7 Henderson B, Edwards J C W. *The synovial lining in health and disease*. London: Chapman Hall, 1987.
- 8 Levick J R. Synovial fluid exchange—a case of flow through fibrous mats. *NIPS* 1989; **4**: 198–202.
- 9 Worrall J G, Bayliss M T, Edwards J C W. Morphological localisation of hyaluronan in normal and diseased synovium. *J Rheumatol* 1991; **18**: 1466–72.
- 10 Caterson B, Christner J E, Baker J R, Couchman J R. Production and characterization of monoclonal antibodies directed against connective tissue proteoglycans. *Fed Proc* 1985; **44**: 386–93.
- 11 Caterson B, Christner J E, Baker J R. Identification of a monoclonal antibody that specifically recognises corneal and skeletal keratan sulphate. *J Biol Chem* 1983; **258**: 8848–56.
- 12 Sorrell J M, Mahmoodian F, Schafer I A, Davis B, Caterson B. Identification of monoclonal antibodies that recognize novel epitopes in native chondroitin/dermatan sulfate glycosaminoglycan chains: their use in mapping functionally distinct domains in human skin. *J Histochem Cytochem* 1990; **38**: 393–402.
- 13 Bertolotto A, Palmucci L, Mongini T, Schiffer D, Caterson B. Chondroitin, chondroitin 6-sulphate, chondroitin 4-sulphate and dermatan sulphate proteoglycans in normal and pathological human muscle. *J Neurol Sci* 1987; **81**: 247–59.
- 14 Arnett F C, Edworthy S M, Bloch D A, *et al.* The American Rheumatism Association 1987 revised criteria for the classification of rheumatoid arthritis. *Arthritis Rheum* 1988; **31**: 315–24.
- 15 Gallagher J T. The extended family of proteoglycans: social residents of the pericellular zone. *Curr Op in Cell Bio* 1989; **1**: 1201–18.
- 16 Worrall J G, Wilkinson L S, Bayliss M T, Edwards J C W. Synovial expression of the chondroitin sulphate proteoglycans decorin and biglycan. *Brit J Rheumatol* 1992; **31** (suppl 2): 68.
- 17 Pitsillides A A, Mehdizadeh S, Worrall J G, Wilkinson L S, Edwards J C W. Demonstration of diphosphoglucose dehydrogenase activity in normal and rheumatoid synovial lining cells. *Brit J Rheumatol* 1991; **30** (suppl 1): 6.
- 18 Broker B M, Edwards J C W, Fanger M W, Lydyard P M. The prevalence and distribution of macrophages bearing FcγRI, FcγRII and FcγRIII in synovium. *Scand J Rheum* 1990; **19**: 123–135.
- 19 Okada Y, Nagase H, Harris E D Jr. A metalloproteinase of human rheumatoid synovial fibroblasts that digests connective tissue matrix components. *J Biol Chem* 1986; **261**: 14245–8.
- 20 Barker S A, Hawkins C F, Hewins M. Mucopolysaccharides in synovial fluid: detection of chondroitin sulphate. *Ann Rheum Dis* 1966; **25**: 209–13.
- 21 Folkman J, Klagsbrun M, Sasse J, Wadzinski M, Ingber D, Vlodavsky I. A heparin-binding angiogenic protein—basic fibroblast growth factor—is stored within basement membranes. *Am J Pathol* 1988; **130**: 393–400.
- 22 Pollock L E, Lalor P, Revell P A. Type IV collagen and laminin in the synovial intimal layer: an immunohistochemical study. *Rheumatol Int* 1990; **9**: 277–80.
- 23 Levick J R, McDonald J N. Microfibrillar meshwork of the synovial lining and associated broad banded collagen: a clue to identity. *Ann Rheum Dis* 1990; **49**: 31–36.
- 24 Obrink B, Laurent T C, Carlsson B. The binding of chondroitin sulphate to collagen. *FEBS letters* 1975; **56**: 166–69.
- 25 Freemont A J, Jones C J P, Bromley M, Andrews P. Changes in vascular endothelium related to lymphocyte collections in diseased synovia. *Arthritis Rheum* 1983; **26**: 1427–33.