

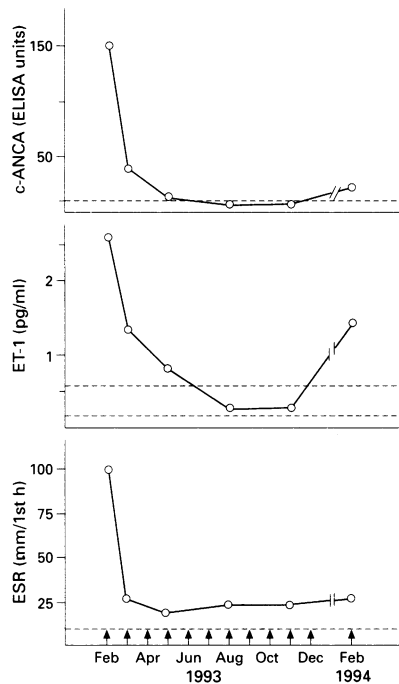
## LETTER TO THE EDITOR

### Wegener's granulomatosis of the elderly: a case report of uncommon severe gangrene of the feet

Wegener's granulomatosis (WG) is a systemic vasculitis which typically affects young subjects, but rare cases of onset in the elderly have been reported.<sup>1,2</sup> The condition is characterised by pulmonary and renal manifestations, and by antineutrophil cytoplasmic antibody (c-ANCA).<sup>1,3</sup> If untreated, WG shows a rapidly fatal course, particularly when complicated by renal failure;<sup>1</sup> however, combined therapy with cyclophosphamide pulse and steroid has drastically changed the prognosis of these patients.<sup>4</sup>

We report the case of an 80 year old man who, in April 1992, first complained of high fever, diffuse discomfort, and weight loss. Multiple lung opacities were observed in chest radiograph and computed tomography (CT) scan; spirometry was normal, and cytological examination of bronchoalveolar aspirations excluded malignancies. In August 1992 an incomplete cavitation of the lung opacities was demonstrated by CT scan; this disappeared at the six month control. The patient subsequently showed severe gangrene of the toes, with progressive impairment in walking. A diagnosis of peripheral occlusive vasculopathy was suggested, but angiography was negative and treatment with high dose nifedipine was ineffective. During the same period, sudden sensorineural deafness occurred.

In January 1993 the patient was first admitted to our hospital. His general condition was severely compromised by fever, mild renal involvement, nasal mucosa ulcers, and progressive gangrene of the feet. Blood pressure was normal and peripheral arterial pulses could be felt. Skin ulcer biopsy disclosed a leucocytoclastic vasculitis. Biological data were: erythrocyte sedimentation rate 103 mm/1st h, haemoglobin 7.6 g/dl, leucocytosis, serum creatinine 1.5 mg/dl (normal value (nv) <1.3) with microscopic haematuria. Among immunological parameters, abnormally high values of c-ANCA (152 ELISA units, nv <10) and plasma endothelin-1 (ET-1) (2.61 pg/ml, nv 0.2-0.6) were found (figure). Diagnosis of WG was thus confirmed and treatment with intermittent cyclophosphamide 1 g pulse and prednisone 50 mg/day was started. After one month, a clear improvement in the gangrene and a significant reduction of c-ANCA and plasma ET-1 values were observed, together with normalisation of serum creatinine and



Main serological parameter variations during treatment with pulses of cyclophosphamide (Cy) 1 g (1) and oral prednisone 50 mg/day. Since December 1993, the patient has taken prednisone 25 mg on alternate days, and pulse Cy therapy has been discontinued because he is well. The dotted line defines the normal range of antineutrophil cytoplasmic antibody (c-ANCA) (by PR-3 ELISA, BIO-CARB, Malmo, Sweden), plasma endothelin-1 (ET-1) (mean  $\pm$  2 SD) (by Endothelin 1/2 RIA, Biomedica Gruppe, Wien, Austria), and erythrocyte sedimentation rate (ESR).

urine analysis. Clinicoserological manifestations further improved during the follow up period. In February 1994, two months after treatment was discontinued, a relapse of fever and foot ulcers, with changes in plasma ET-1 and c-ANCA were observed (figure). Concomitant infectious or neoplastic disorders were excluded and monthly cyclophosphamide pulses were restarted. There was again a marked clinical improvement, and the patient's condition has remained stable.

This case is characterised by very late onset of WG and the presence of severe skin gangrene. In a series of 158 cases of WG,<sup>1</sup> the patients' mean age was 41 years (range 9-78). In older subjects WG can represent a difficult diagnostic and therapeutic challenge, particularly when oligosymptomatic.<sup>2</sup> In our patient, the presenting symptom was lung involvement, which mimicked a neoplasia; thus WG should be included in the differential diagnosis along with other systemic or neoplastic disorders, in order to promote rapid instigation of appropriate treatment. In WG, cutaneous involvement (purpura, nodules, papules, and ulcers) is an uncommon and generally mild manifestation, occurring at any time during the clinical course of disease;<sup>1,5</sup> skin ulcers are

limited and frequently self limiting.<sup>5</sup> In our patient, gangrene was progressive and extremely disabling, and his sudden hearing loss, which was another unusual complication,<sup>6</sup> did not respond to therapy because of the delay between the onset of deafness and diagnosis of WG. In this patient, cyclophosphamide pulses and prednisone were justified by the severe and rapidly progressive gangrene of the feet. Clinical improvement during treatment was mirrored by the normalisation of c-ANCA and plasma ET-1 values (figure). Abnormally high levels of plasma ET-1 have frequently been described in cardiovascular<sup>7</sup> and rheumatic diseases.<sup>8,9</sup> In the latter, plasma ET-1 concentration could be correlated with the presence and severity of the vasculitis.<sup>10</sup>

In conclusion, in WG of the elderly, the efficacy of cyclophosphamide pulse and steroid therapy together with a good correlation between clinical outcome and serological markers was demonstrated. In particular, the variation in plasma ET-1 concentrations suggests the possible usefulness of this variable in clinical follow up monitoring of WG and other systemic vasculitides.

L LA CIVITA  
G JERACITANO  
C FERRI  
Istituto Patologia Medica I,  
University of Pisa, Pisa, Italy

R PEDRINELLI  
G DELL'OMO  
G CATAPANO  
Clinica Medica I, University of Pisa, Pisa, Italy

Correspondence to: Dr Luca La Civita, Istituto Patologia Medica I, University of Pisa via Roma, 67-56126 Pisa, Italy.

- Hoffman G S, Kerr G S, Leavitt R Y, et al. Wegener's granulomatosis: an analysis of 158 patients. *Ann Intern Med* 1992; 116: 488-98.
- Chakravarty K, Scott D G I, Blyth J, Courtney-Harris R G. Wegener's granulomatosis in the elderly: unusual presentations and misdiagnosis. *J Rheumatol* 1994; 21: 1157-9.
- Falk R J, Jennette J C. ANCA and its relationship to vasculitis: disease associations, role in vasculitis, and pathogenesis. *Curr Opin Rheumatol* 1992; 4: 9-12.
- Haubitz M, Frei U, Rother U, Brunkhorst R, Koch K M. Cyclophosphamide pulse therapy in Wegener's granulomatosis. *Nephrol Dial Transplant* 1991; 6: 531-5.
- Patten S F, Tomecki K J. Wegener's granulomatosis: cutaneous and oral mucosal disease. *J Am Acad Dermatol* 1993; 28: 710-8.
- Luqmani R, Jubb R, Emery P, Reid A, Adu D. Inner ear deafness in Wegener's granulomatosis. *J Rheumatol* 1991; 18: 766-8.
- Simonson M S, Dunn M J. Endothelins: a family of regulatory peptides; state-of-the-art lecture. *Hypertension* 1991; 15: 493-6.
- Ferri C, Latorraca A, Catapano G, et al. Increased plasma endothelin-1 immunoreactive levels in vasculitis: a clue to the use of endothelin-1 as a marker of vascular damage? *J Hypertens* 1993; 11: S142-3.
- Morise T, Tacheuchi Y, Takeda R, Karayalcin U, Yachie A, Miyawaki T. Increased plasma endothelin levels in Kawasaki disease: a possible marker for Kawasaki disease. *Angiology* 1993; 44: 719-23.
- Ferri C, La Civita L, Zignego A L, et al. Plasma levels of endothelin-1 in mixed cryoglobulinaemia patients. *Br J Rheumatol* 1994; 33: 689-90.