

# Radiological manifestations of ankylosing spondylitis according to age at onset

M. J. RILEY, B. M. ANSELL, AND E. G. L. BYWATERS

From the M.R.C. Rheumatism Unit, Canadian Red Cross Memorial Hospital, Taplow, and the Department of Medicine, Royal Postgraduate Medical School, London

Although ankylosing spondylitis usually starts in the third decade of life, in both men and women, Wilkinson and Bywaters (1958) found that in 18 per cent. of 222 cases the onset occurred in the second decade (the earliest being at 11 years) and that in 11 per cent. the disease apparently started after the age of 39 years: five patients were seen with symptoms apparently starting at the age of 50 years or more. We noted that disc degeneration might sometimes 'precede ossification, giving an appearance resembling osteophytosis'; this created difficulty in reading the spinal x rays, particularly in these more elderly patients. We have returned to the problem of differing radiological manifestations in different 'age-at-onset' groups because we felt that such a study might throw light on the pathogenesis of the various lesions seen. As Collins (1949) insisted, an osteophyte is essentially an outgrowth of new subperiosteal bone at the vertebral margin, secondary to the anterolateral prolapse of a degenerated disc, but he regarded a syndesmophyte as 'an ossification of the outer fibres of the annulus fibrosus'. de Sèze, Lacapère, and Amoudruz (1952), in their insistence on the subligamentary location of both, have drawn attention to the osteophyte-like appearance—'like a parrot's beak'—of the so-called 'syndesmophyte' in patients with spondylitis of late onset.

If the difference between these two types of new bone formation is that the osteophyte proceeds from the periosteal ring and occupies the corner between disc substance and bone, whereas the syndesmophyte advances into the outer layer of the annulus from the margins of the bone, a study of different age-at-onset groups should provide evidence for the role of disc degeneration in these formations and might also reveal differences between real osteophytes and osteophyte-like growths occurring in ankylosing spondylitis of later onset.

## Materials and methods

The radiographs of all cases of ankylosing spondylitis seen in the Medical Research Council Rheumatism Unit's clinics up to January, 1967, including certain selected cases seen jointly at Hammersmith Hospital, were studied together with their clinical records. In each of 142 cases indexed all available x rays of peripheral joints, root joints (hips and shoulders), pelvis and sacroiliac joints, lateral cervical spine, and postero-anterior and lateral lumbar spine, were read by two of us without knowledge of the patients' identity or age grouping and specified items were recorded on a standard *pro forma* (Fig. 1). The clinical histories were reviewed later and recorded on punch cards. In the final assessment three cases were removed because of inadequate x rays, and four failed to fulfil our criteria for ankylosing spondylitis, namely back pain and stiffness and limitation of movement with bilateral sacroillitis on x-ray examination. These criteria are more selective than those adopted at the Rome meeting of 1961 (Kellgren, Jeffrey, and Ball, 1963) because of the necessity to exclude cases of Still's disease from the youngest age-at-onset group and hyperostotic ankylosing spondylosis from the oldest age-at-onset group. There remained a total of 135 patients, 25 of whom were females. These were divided into six groups by age at onset (Table I); the distribution has a bias towards those with an onset under 21, because of this Unit's particular interest in juvenile rheumatism.

**Table I** Age distribution at onset of ankylosing spondylitis in 135 cases

Age at first symptom (yrs)	Sex		Total
	Male	Female	
Under 16	20	8	28
16-20	23	3	26
21-25	25	6	31
26-30	9	3	12
31-40	20	4	24
41+	13	1	14
Total	110	25	135

ANKYLOSING SPONDYLITIS SURVEY

NAME	YEAR OF X-RAY					
ITEMS TO BE NOTED	<u>Thoracolumbar (post anterior)</u>		<u>Cervical (lateral)</u>		<u>Thoracolumbar (lateral)</u>	
	Right	Left	Anterior	Posterior	Anterior	Posterior
<u>Whole spine</u>						
Kyphosis						
Scoliosis						
<u>Bodies</u>						
Shape: Squaring Wedging						
Width						
Romanus						
Subluxation						
Granuloma						
<u>Disc space</u>						
Height						
Protrusion						
Shape						
Calcification						
Bridging						
<u>Ligaments</u>						
Ossification						
Anterior, Posterior, Lateral						
<u>Apophyseal joints</u>						
Fusion and narrowing						
<u>Root and peripheral joints</u>	Right				Left	
<u>Extra-articular</u>	Right				Left	
Pelvis, symphysis, heels						
Comments.....						

FIG. 1 Standard pro forma (diagram).

The differentiation of 'osteophyte' from 'syndesmophyte' was made on the following radiological grounds. The osteophyte is often associated with disc narrowing and is a marginal *horizontally* disposed bony plate or wedge built up at its base with subperiosteal bone and lying against the protruded disc substance. The syndesmophyte, on the other hand, is seen usually without any disc narrowing or protrusion and consists of a *vertical* plate or wedge of bone in the outer layer of the annulus fibrosus; it will form ultimately a bridge between one vertebral body and the next.

This difference is diagrammatically illustrated as seen in an antero-posterior x-ray projection in Fig. 2 (overleaf).

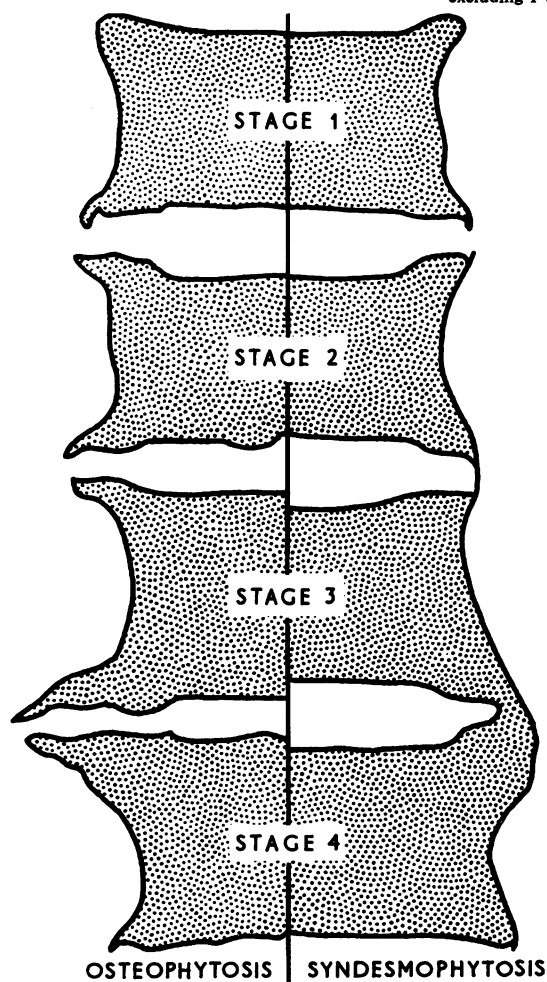
Results

The mode of presentation (Table II, overleaf) showed a marked variation with the age at onset, a peripheral and root joint presentation being common in the under 16 and under 21-year groups, and back presentation predominating from 21 onwards, although in the older group neck pain became more...

**Table II** *Mode of presentation and duration to diagnosis of ankylosing spondylitis*

Age at onset of symptoms (years)	Total cases	Presentation				Years to diagnosis	
		Back pain	Peripheral joints	Root joints	Other	Mean	Range
Under 16	28	2	18	7	1	7.1	1-16
16-20	26	8	13	4	1	8.5	1-31
21-25	31	20	4	6	1	5.0	1-25
26-30	12	9	1	1	1	5.5*	1-50
31-40	24	19	1	1	3	7.4	1-20
41+	14	11	0	0	3	7.8	1-23
Total	135	69	37	19	10		

\* excluding 1 with 50 yrs duration



**FIG. 2** *Criteria for differentiation between 'osteophyte' (left) and 'syndesmophyte' (right). When there was difficulty in differentiation, illustrated top left—the earliest stage of an osteophyte—this was registered for the purposes of this paper as a syndesmophyte—corresponding to the F1 and F2 lesions described by Meijers, van Voss, and François (1968), who found them almost equally distributed between rheumatoid arthritis, ankylosing spondylitis, and generalized osteoarthritis.*

frequent, occurring in five of 38 cases. The duration to diagnosis (Table II) was therefore slightly shorter in the 21 to 30 age-at-onset group (mean 5.2 years) than in the older and younger groups. Complaints of back pain in the over-31 group had been frequently thought to be due to degenerative or disc disease, and in the under 21s the peripheral arthritis had usually been diagnosed as Still's disease (definite in sixteen cases and 'probable Still's' in two). Two other cases in this group had ulcerative colitis with spondylitis. Including these two, in the whole series, there were seven with ulcerative colitis and spondylitis, fairly evenly distributed between the various age-at-onset groups (four female and three male), as well as three with regional enteritis, and three with psoriasis in addition to spondylitis.

#### Radiological findings

Analysing the radiological changes present in the last available x rays in each case, regardless of disease duration, we have compared three groups, with an age at onset under 21 years, between 21 and 30 years, and over 31 years. The mean duration of the disease from the onset of symptoms to the latest x rays was 13.8 years in the under-21 group, 12.3 years in the 21 to 30 group, and 11.7 years in the over-31 group; these are only very slight differences.

Radiological peripheral and root joint involvement (Table III) during the course of ankylosing spondylitis was far commoner in the younger age groups.

The metatarsophalangeal joints were the most frequently involved of the peripheral joints and were the only such joints affected in twelve of twenty of the under 21s; six had hands and feet involved, one the hands only, and one a knee. Of the five cases in the 21 to 30 group, three had foot involvement only, and two had hand and foot lesions. In the over-31 group, one had arthritis of the feet only and the other had a more widespread polyarthritis associated with psoriasis.

The root joints involved were predominantly hips. Of the nineteen cases under 21, only six had shoulder

**Table III** Radiological joint involvement in ankylosing spondylitis

Age at onset (yrs)	Total cases	Joints				Heel lesions	
		Peripheral		Root			
		No.	Per cent.	No.	Per cent.	No.	Per cent.
Under 21	54	20	37	19	35	10	18
21-30	43	5	12	6	14	3	7
31+	38	2*	5	5	13	2	5

P < 0.01      P < 0.02      P < 0.01

\* One case with psoriasis

involvement, and of the six in the 21 to 30 group only one. Hips were the only root joints affected in the over-31 group.

Heel lesions (sub-Achillean erosions and/or 'active' subcalcaneal spurs) also occurred more frequently in the young.

The spinal films—the cervical and lumbo-dorsal spine (postero-anterior and lateral)—were analysed separately and the proportion of cases in each age group affected by individual lesions was determined.

'Romanus' lesions in the neck were rarely seen in cases with an onset under 21 years (Table IV) in contrast to older groups. In the lumbo-dorsal spine (Table V), Romanus lesions were again seen in a higher proportion of cases in the older groups and in only 35 per cent. of the under-21s.

*Syndesmophyte formation and bridging* (Table VI) was common in all groups, increasing slightly with age and seen most frequently in the postero-anterior films of the lumbo-dorsal spine. The overall incidence of cases with osteophyte formation (Table VII, overleaf) was much lower, but all regions showed an increase with the age at onset, particularly in the postero-anterior views of the lumbo-dorsal spine.

Apophyseal joint lesions had a similar prevalence in all age-at-onset groups, 63 per cent. of the patients showing neck involvement and 82 per cent. lumbar

**Table IV** Cases with neck lesions in ankylosing spondylitis, 1967

Age at onset (yrs)	Total cases	Neck lesions			
		Underdeveloped vertebral bodies		Romanus lesions	
		No.	Per cent.	No.	Per cent.
Under 21	40	5	12	9	22
21-30	31	0	0	11	35
31+	29	0	0	12	41

N.S.

**Table V** Number and percentage of cases with dorso-lumbar vertebral body lesions (lateral x ray)

Age at onset (yrs)	Total cases	Dorso-lumbar lesions					
		Squaring		Romanus		Wedging	
		No.	Per cent.	No.	Per cent.	No.	Per cent.
Under 21	43	19	44	15	35	3	7
21-30	38	21	55	16	42	5	13
31+	32	20	62	20	62	5	16

N.S.

N.S.

N.S.

joint involvement. Ossification of the posterior interspinous ligaments was present in 39 per cent. of cases and there was no difference between the three age-at-onset groups. Underdevelopment of vertebral bodies was present only in five of the forty cases with onset below the age of 21 (Fig. 3, overleaf). The overall incidence of squaring (Table V) was 54 per cent. with only a slight increase with age; anterior wedging, usually in the dorsal region, was less frequent but showed a similar tendency.

As the preceding results are based upon all the available x rays and the duration of the disease had

**Table VI** Cases with bridging and syndesmophyte formation in 1967

Age at onset (years)	Neck				Lumbo-dorsal						
	Total	Number involved		Total	Postero-anterior		Lateral		Total	Number involved	
		No.	Per cent.		No.	Per cent.	No.	Per cent.			
										No.	Per cent.
Under 21	40	25	62	49	38	77	43	23	53		
21-30	31	22	71	42	35	83	38	24	63		
31+	29	23	79	36	34	95	32	26	81		

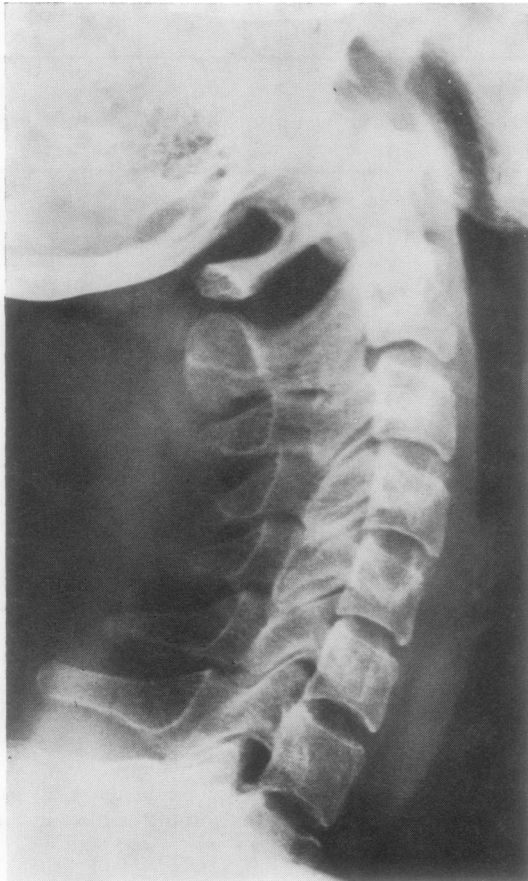N.S.

N.S.

P < 0.05

**Table VII** *Cases with osteophyte formation*

Age at onset (years)	Neck			Lumbo-dorsal							
	Total	Number involved		Postero-anterior				Lateral			
		No.	Per cent.	Total	Number involved		Total	Number involved			
					No.	Per cent.		No.	Per cent.		
Under 21	40	3	7	49	7	14	43	3	7		
21-30	31	5	16	42	8	19	38	3	8		
31+	29	9	31	36	19	55	32	10	31		
		P < 0.05				P < 0.01				P < 0.01	



**FIG. 3** *Under-development of cervical vertebral bodies in S.M., a female aged 25 years, with moderate limitation of neck and gross limitation of back movements. Onset in 1951 at age 14 with pain and swelling of the foot, ankle, and knee. Diagnosed as ankylosing spondylitis in 1961. In 1963 x-ray examination showed bilateral sacroiliitis and squaring of vertebrae. Erythrocyte sedimentation rate 34 mm. Hg; differential agglutination and latex tests negative.*

varied from less than 1 to 55 years, we extracted all films taken approximately 10 years (range 8 to 12) from the onset of symptoms (57 cases) and again compared the incidence of lesions and in addition their extent in the affected cases (Tables VIII to XIV).

**Table VIII** *Romanus lesions and osteophyte formation in the neck 10 years from onset*

Age at onset (yrs)	Total cases	Lesions			
		Romanus		Osteophytes	
		No.	Per cent.	No.	Per cent.
Under 21	24	7	29	0	
21-30	11	3	27	2	18
31+	9	5	55	2	22

**Table IX** *Bridging and syndesmophyte formation in the neck at 10 years from onset*

Age at onset (yrs)	Total cases	Cases involved		Mean no. of joints affected/involved case
		No.	Per cent.	
Under 21	24	13	54	2.6
21-30	11	8	73	2.5
31+	9	6	66	2.8

**Table X** *Apophyseal joint involvement in the neck at 10 years from onset*

Age at onset (yrs)	Total cases	Cases involved		Mean no. of joints affected/involved case
		No.	Per cent.	
Under 21	24	11	46	4.2
21-30	11	8	73	3.7
31+	9	4	44	2.7

**Table XI** Squaring and Romanus lesions in lateral lumbo-dorsal spine at 10 years

Age at onset (yrs)	Total cases	Lesions			
		Squaring		Romanus	
		No.	Per cent.	No.	Per cent.
Under 21	26	9	35	9	35
21-30	11	6	54	6	54
31+	14	7	50	7	50

**Table XII** Osteophyte formation in postero-anterior lumbo-dorsal spine at 10 years from onset

Age at onset (yrs)	Total cases	Cases affected	
		No.	Per cent.
Under 21	30	0	
21-30	13	2	15
31+	14	8	57

At 10 years from the onset the incidence of squaring and Romanus lesions was similar to the overall figures cited previously with a similar increase in the older groups (Table VIII and IX). There were no osteophytes in the under-21 group at 10 years; in the over-31s, the incidence in the postero-anterior lumbo-dorsal spine was 57 per cent. (Tables VIII and XII).

Cases showing apophyseal joint involvement (Tables X and XIV) in the lumbo-dorsal spine were less frequent in the under-21s, but the actual mean number of affected sites was only slightly less than in the 21 to 30 group and was more than in the over-31s in spite of the lower incidence. In the neck (Table X), more joints were affected per involved case in the young. In contrast to this (Tables IX and XIII), bridging and syndesmophyte formation in the lumbo-dorsal region not only affected more patients in the older groups but the extent was greater, the mean number of bridges and syndesmophytes in affected cases being nine per patient in the over-31s as opposed to three per patient in the under-21s.

Apophyseal joint involvement (Table X) in the neck occurred in about half the cases. The severity as judged by the mean number of affected joints was greatest in the under-21s. The incidence of bridging and syndesmophyte formation (Table XI) in juveniles was slightly less common than in the other groups, but when present was similar in extent.

**Table XIII** Bridging and syndesmophyte formation in postero-anterior lumbo-dorsal spine at 10 years

Age at onset (yrs)	Total cases	Cases involved		Mean no. of joints affected/involved case
		No.	Per cent.	
Under 21	30	16	53	3
21-30	13	11	92	8.1
31+	14	14	100	9.0

**Table XIV** Apophyseal joint involvement of lumbo-dorsal spine at 10 years from onset

Age at onset (yrs)	Total cases	Cases involved		Mean no. of joints affected/involved case
		No.	Per cent.	
Under 21	30	20	66	5.8
21-30	13	11	85	7.4
31+	14	12	86	4.0

However, in the younger age-at-onset groups, bony apophyseal joint lesions might occur with minimal syndesmophyte formation, whereas in the older group bridging was often marked with only minimal apophyseal joint changes evident on x ray (Fig. 4, overleaf).

Radiotherapy was not thought to influence these results, since in each age-at-onset group, except the youngest (Table XV, overleaf), the proportion treated was similar—about one-third. In the youngest group (under 16 at onset) the spine was seldom irradiated.

## Discussion

Perhaps the most obvious radiological difference between these three age-at-onset groups is the preponderance in the youngest group of changes in the peripheral and root joints throughout the course of the disease. This was also noticed in the series of Wilkinson and Bywaters (1958) where such involvement occurred in 40 per cent. of those under the age of 20 years, and in 22 per cent. in all other age groups. The metatarsophalangeal joints were those most frequently involved in all age groups: they were the only peripheral joints involved in sixteen of the 27 cases. Hips were also far more commonly affected than shoulders. This predilection for the joints of the lower limbs was also noted by Polley and Slocumb

**Table XV** *Radiotherapy according to age at onset*

Age at onset (yrs)	Radiotherapy			Per cent. given radiotherapy
	Given	Not given	Total	
Under 16	7	21	28	25 } 28
16-20	8	18	26	
21-25	12	19	31	39 } 28
26-30	0	12	12	
31-35	4 } 4 }	16	24	33
36-40				
41-50	5 } 0 }	9	14	36
Over 50				
Total	40	95	135	30

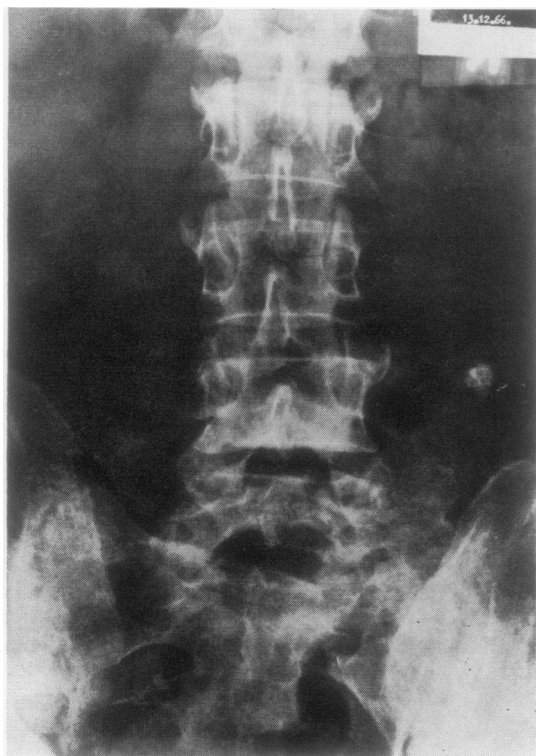


FIG. 4 *S.D.*, a man aged 60 years in 1966 with a history of 20 years' vague backache. Note well-marked syndesmophytes and well-preserved apophyseal joint spaces.

(1947); of their 1,035 cases of ankylosing spondylitis, 23 per cent. had peripheral joint involvement, in 65 per cent. of these it appeared in the lower limbs only, in 31 per cent. in both upper and lower, and in only 4 per cent. in the upper limbs only.

A more interesting difference between those whose disease started in youth and those whose disease started later in life is the lesser frequency of Romanus lesions and the comparative rarity of 'osteophytes' in the younger compared with the older groups. Apophyseal joint involvement was equally common

in all three groups, as was ossification of the posterior interspinous ligaments. The apophyseal neck joints tended to be involved more frequently and to a greater extent in the young, in contradistinction to the lumbar spine.

The analysis of *x* rays taken approximately 10 years from the onset of the disease confirmed the differences already described in the overall assessment. An attempt, however, was made to assess the degree of involvement in affected cases by recording the number of involved joints and of syndesmophytes present in each affected case. There were no significant differences between the age-at-onset groups, but it appeared that although the apophyseal joint involvement, as measured by the number of affected joints, was similar in all groups, bridging and syndesmophyte formation was both commoner and more extensive in the older group. It was particularly noticeable in the lumbo-dorsal spine and the neck. Possibly in the older group spinal movement may be limited earlier and by less severe lesions than in the young, and this limitation, less obvious to the patient, may itself lead to syndesmophyte production.

These differences between age-at-onset groups could be due, *firstly* to bias in initial selection, *secondly* to inclusion of other nosological entities, or *thirdly* to different pathological reactions to the same morbid stimulus. We incline to the third view, for reasons which follow:

(1) Many circumstances may bias a hospital collection of cases. These seem equal for each age group, including those of referral: the delay from onset to definitive diagnosis was considerable in all three groups. This period was shorter in the 21 to 30 age group (mean 5.2 years) than in the under-21s (7.8 years) and the over-31s (7.6 years), perhaps because of the accepted idea that this disease presents as back pain; in the young age-at-onset group it presented as peripheral arthritis and was often diagnosed as Still's disease. In the older group, back pain, although usually the presenting symptom,

was frequently attributed to other origins, such as disc prolapse or degeneration.

(2) We do not believe that we have included cases of Still's disease in the youngest age-at-onset group, since our patients remain under observation long enough for these changes to declare themselves. As mentioned by Ansell (1969), nine of 149 with a diagnosis of definite Still's disease had developed ankylosing spondylitis as defined here by the 15-year follow-up, and these cases are included in this series. These were, by definition of age, all in the under-16 group, but the later development of bilateral severe sacroiliitis and back limitation allowed the criteria for ankylosing spondylitis outlined above to be applied. Eight of the nine cases were male. Eight children in this group of 28 were recognized from the start as having ankylosing spondylitis because of the early appearance of back symptoms.

As has been stressed by numerous authors, what turns out ultimately to be ankylosing spondylitis may start long before 15 years of age and its manifestation at that age may well be atypical (Edström, Thune, and Wittbom-Cigén, 1960; Chaussé and Ribeyrol, 1966; Jacobs, 1963; Louyot, Gaucher, Manivit, and Combebias, 1967; Delbarre and Martin, 1967; Doury, 1967; Bloch-Michel, 1967). Our findings confirm this. The youngest ages at onset appear to be a case of Edström's starting at 5 years, one of Ellefsen (1967) at 6 years, and one of Schaller, Bitnum, and Wedgwood (1969) at 7 years. Our youngest patient started at the age of 3 years (see Fig. 5). We cannot include the claim of Lucchesi and Lucchesi (1957) (from 2 years of age upwards!) because of their inadequate criteria and unusual sex incidence. Thus the differentiation between ankylosing spondylitis and Still's disease can be extremely

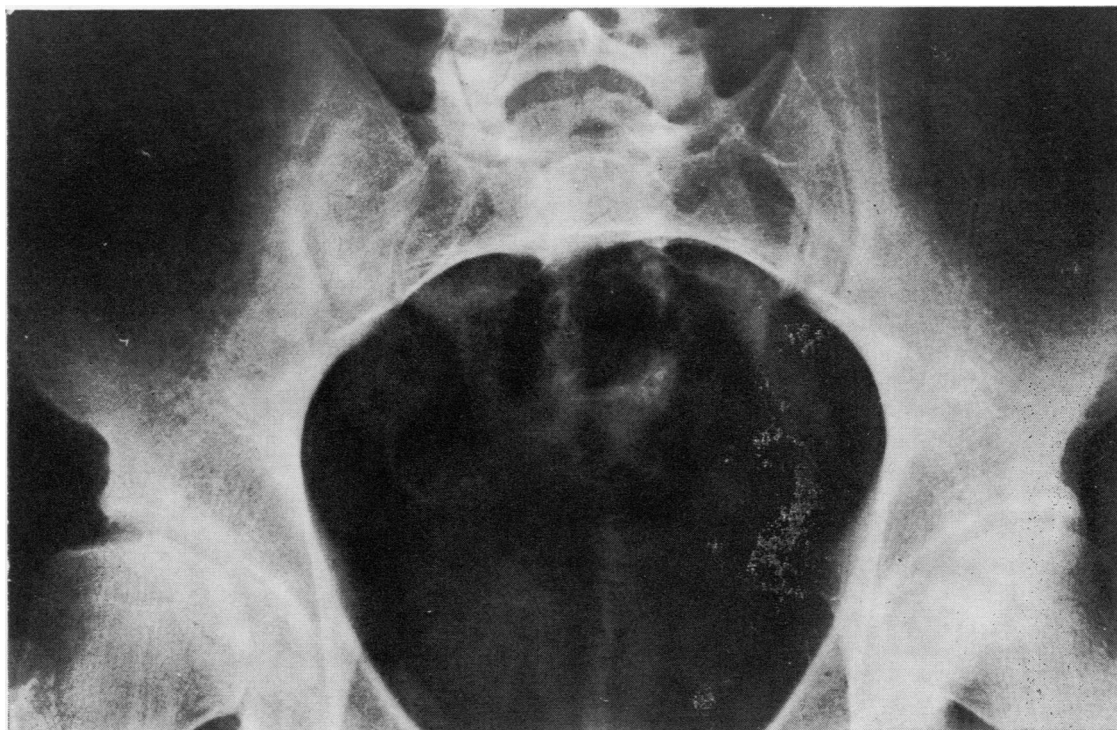


FIG. 5 P.C., a male aged 3 years in 1946 at onset. Minimal but definite sacroiliac changes were seen in 1969 at age 26; these had been unchanged for 9 years since 1960, and had not been present in 1948. The disease started in 1946 with pain and swelling of the right knee which was treated in plaster for 3½ years as 'tuberculosis'. At age 10 the left knee became involved, and 5 years later biopsy showed synovial membrane 'compatible but not absolutely typical of rheumatoid arthritis' (E.G.L.B.). This was followed by recurrent iritis, the development of slight joint limitation of the right hip, left elbow, and knees, and growth defects of three toes. At this time the

erythrocyte sedimentation rate was 8 mm./hr, the Waaler-Rose titre 1:2, and the latex test negative. He remained well for the next 9 years apart from mild backache in 1961 and mild limitation of back movement in 1963, progressing to 1969, when he could reach to 6 in. from the floor. Chest expansion has remained full. X rays have shown mild sacroiliitis, and slight residual deformity of the femoral heads and elbow joints, and growth lesions of the toes. The spine shows no lesion except minimal anterior spondylitis at one joint T12-D1, and the patient leads a normal life.



difficult even with prolonged observation, since sacroiliitis can occur in about one-fifth to one-sixth of cases of Still's disease (Bywaters and Ansell, 1965) without other signs of ankylosing spondylitis and without the development of spinal lesions either clinically or radiologically, at least up to 10 years from onset. Involvement of the cervical apophyseal joints, with erosive changes and in many cases with fusion, also can occur in up to two-thirds of cases of Still's disease (Ansell and Bywaters, 1961) and in cases with neck involvement the proportion with sacroiliac changes was 45 per cent. The sacroiliac lesion is seldom as severe or as symmetrical as in ankylosing spondylitis and is not usually accompanied by gross sclerosis or erosions. Thus, some earlier reports of 'ankylosing spondylitis' in juveniles (*e.g.* perhaps Lucchesi and Lucchesi, 1957) may include cases without lumbar spinal involvement and with ill-defined sacroiliac changes only. This is insufficient evidence of ankylosing spondylitis in children. It is therefore in this age group that criteria to differentiate between the two diseases are urgently needed, and it is unfortunately the one section in which the Rome criteria (Kellgren and others, 1963) are inadequate for this purpose, in that iritis and sacroiliac change are common to both diseases. Iritis occurred in 25 per cent. of those who were under 16 years old at the time of onset and in 15 per cent. of the remainder, including 14 per cent. of those starting after the age of 40.

In the small but interesting group in which this disease apparently started after the age of 41, differentiation from senile hyperostotic spondylosis is important, since this has been shown to occur almost entirely after this age (Bywaters, Doyle, and Oakley, 1966). Some of these patients who were older at onset may have had an asymptomatic course for many years, as exemplified by Commander D. F., who presented in 1965 at the age of 76 with a 6-week history of back pain following a fall; he had no previous symptoms, apart from iritis 2 years previously; on examination the spine was completely rigid and x rays (Fig. 6) showed a collapse of L4 and severe bamboo spine—obviously of longer duration than 6 weeks, but masked by the upright posture expected in members of the Arméd Forces. Others, however, would appear to have radiological changes consistent with the duration of their clinical symptoms, as in the case of J. H., who developed backache in 1959 at the age of 44; a diagnosis of ankylosing spondylitis was made 7 years later in 1966 and the radiological changes were compatible with a clinical duration of 7 years (Fig. 7).

If these cases with apparent onset after 41 years of age all had a prolonged asymptomatic course following real onset at an earlier age, one might

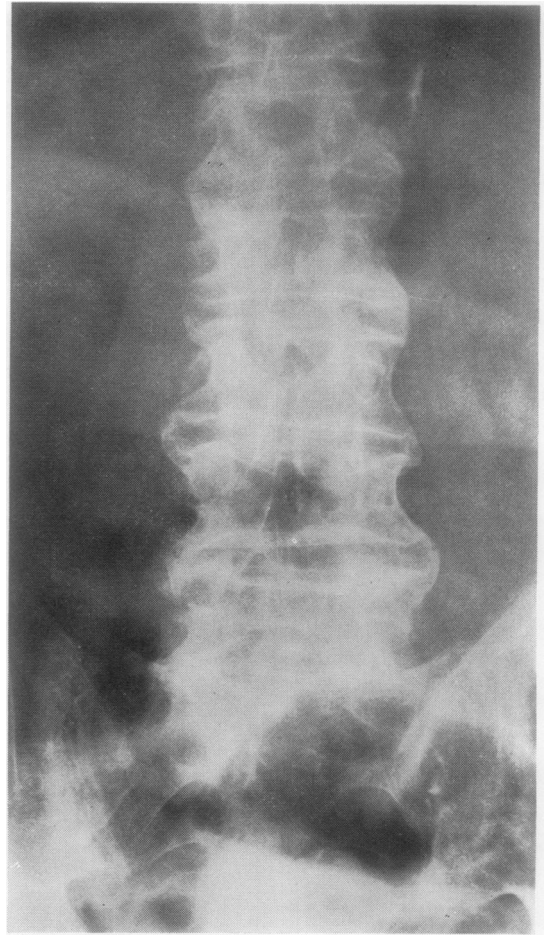


FIG. 6 D.F., a man aged 76 years, had back pain for 6 weeks after a fall. He had iritis at age 74. The back was rigid and x rays showed marked bridging and partial collapse of L4 and L5.

expect to find marked differences in the degree of radiological changes between this group and those with a slightly earlier onset; this would also be apparent in the analysis of the x rays taken 10 years after onset. The differences from the 21 to 40 year group, however, are comparatively small and in most instances are not statistically significant; obviously underdevelopment of vertebral growth can occur only in the youngest group in which the disease is active before the cessation of vertebral epiphyseal growth; the infrequency of Romanus lesions in the under-21s is possibly related to the presence of ring epiphyses in the earlier years of their disease, although in only two cases were epiphyses still present at the time of review. Martel, Holt, and Robinson (1962) have drawn attention, however, to the considerable remodelling which also occurs

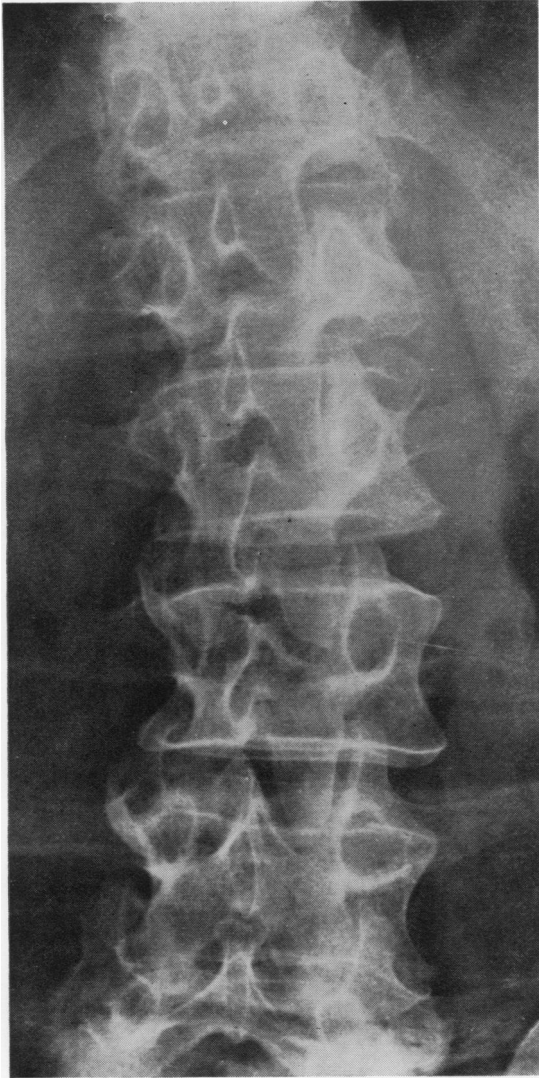

FIG. 7 *J.H.*, a man aged 44 years at onset; x rays showed early syndesmophyte formation and well-preserved apophyseal joint spaces 7 years later.

during adult life. None of the other spinal lesions usually associated with ankylosing spondylitis showed any significant correlation with age at onset.

(3) The most striking difference between the three groups was the increased incidence of 'osteophytes' with advancing age at onset, well illustrated in T.C. (Fig. 8). Whether, as we think, the syndesmophyte is the sequel of local inflammation as Romanus and Ydén (1955) have held (and certainly many are seen to develop at the site of Romanus lesions), or alternatively as others have thought, is secondary to spinal immobility following apophyseal joint involve-

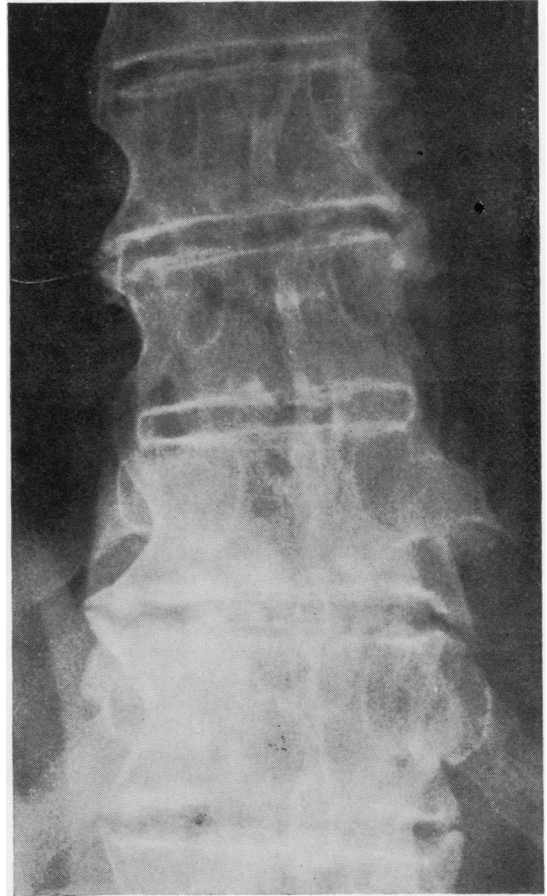


FIG. 8 *T.C.*, a man aged 49 years at the onset of low back pain after a road accident. 4 years later x rays show complete bridging of D8-9 and 10-11 disc spaces with osteophyte formations at D11-12 disc space right and atypical syndesmophytes at D11-12 left and D12-L1 right and left.

ment (Collins, 1949), its form is due to its following the margin of the disc and involving the superficial fibres of the annulus fibrosus; thus the classical syndesmophyte would occur only if the disc space and disc were of normal shape. If it developed at a site of previous disc degeneration or protrusion, then its appearance would be similar to an osteophyte. This would partly explain the increased incidence of 'osteophytes' in the older age-at-onset cases. These might, however, be due to degenerative disease of the spine developing before ankylosing spondylitis or on the other hand to greater mechanical stresses consequent on ankylosis on unaffected sections of the spine with the development of degenerative changes and osteophytosis at these sites.

Thus the increased incidence of what we have read as osteophytes in older age-at-onset groups may be explained in several ways:

(i) It may be a reflection of the increasing incidence with age of degenerative spinal disease and osteophytosis in the general population;

(ii) It may be due to mechanical trauma specifically conditioned by localized ankylosis; such stresses may be more injurious in the older age groups.

(iii) These 'osteophytes' may be really syndesmophytes by origin but modified by the age changes which normally lead to osteophytosis.

In any one case, and indeed at any one site, each or any of these three possibilities may be operative. We incline to the view that the last hypothesis may provide the best explanation in a majority of cases.

### Summary

In an attempt to throw light on the difference in origin and on the relationship between osteophytes and syndesmophytes, an analysis has been made of the radiological changes in 135 cases of ankylosing

spondylitis at follow-up, classified according to age at onset and site of lesion. The age at onset varied from 3 years and a total of 28 patients starting before the age of 16 to a group of thirteen patients starting after the age of 40 and including individuals with an apparent onset at 53, 57, and 76 years. Apparent duration of symptoms before examination was similar in all age-at-onset groups. Peripheral and root joint involvement was common in the younger groups and Romanus lesions (anterior spondylitis) were comparatively uncommon. 'Osteophytosis' was more frequently seen with increasing age-at-onset. A separate analysis was made of *x* rays taken 10 years from onset and this showed similar results. The neck was more frequently involved in the younger group, where apophyseal joint fusion might occur with minimal syndesmophyte formation. The opposite was the case in the older groups. It seemed probable that syndesmophytes forming in older patients might take on the appearance of osteophytes, influenced by age changes.

### References

- ANSELL, B. M. (1969) *Proc. roy. Soc. Med.*, **62**, 912 (Still's disease followed into adult life).  
 — AND BYWATERS, E. G. L. (1961) 'Proc. 10th Int. Congress Rheumatology, Rome', vol. 2, p. 241 (Radiological abnormalities in the cervical spine in juvenile rheumatoid arthritis).  
 BLOCH-MICHEL, H. (1967) 'Monographies Internationales de Rhumatologie', No. 2, p. 155 (Les spondylarthrites ankylosantes à début infantile).  
 BYWATERS, E. G. L., AND ANSELL, B. M. (1965) *Z. Rheumaforsch.*, **24**, 122 (Sacroiliitis in juvenile chronic polyarthrititis).  
 —, DOYLE, F. H., AND OAKLEY, N. (1966) *Arthr. and Rheum.*, **9**, 495 (Senile hyperostotic ankylosing spondylosis (Forestier and Quérol) in diabetes mellitus).  
 CHAUSSÉ, J. D., AND RIBEYROL, J. (1966) *Rhumatologie*, **18**, 197 (Ankylosing spondylitis originating in childhood).  
 COLLINS, D. H. (1949) 'The Pathology of Articular and Spinal Diseases'. Arnold, London.  
 DELBARRE, F., AND MARTIN, J. L. (1967) 'Monographies Internationales de Rhumatologie', No. 2, p. 165 (Les spondylarthrites infantiles et juveniles).  
 DOURY, P. (1967) *Idem*, p. 195 (La spondylarthrite ankylosante à début infantile au Maroc).  
 EDSTRÖM, G., THUNE, S., AND WITTBOM-CIGÉN, G. (1960) *Acta rheum. scand.*, **6**, 161 (Juvenile ankylosing spondylitis).  
 ELLEFSEN, F. (1967) *Ibid.*, **13**, 14 (Juvenile ankylosing spondylitis).  
 JACOBS, P. (1963) *Arch. Dis. Childh.*, **38**, 492 (Ankylosing spondylitis in children and adolescents).  
 KELLGREN, J. H., JEFFREY, M. R., AND BALL, J. (1963) 'The Epidemiology of Chronic Rheumatism', vol. 1, p. 326. Blackwell, Oxford.  
 LOUYOT, P., GAUCHER, A., MANIVIT, P., AND COMEBIAS, J. F. (1967) *Ann. méd. Nancy*, **6**, 1320 (Spondylarthrite ankylosante chez deux jumeaux monozygotes).  
 LUCCHESI, M., AND LUCCHESI, O. (1957) *Rheumatismo*, **13**, 88 (Infantile rheumatoid spondylitis).  
 MARTEL, W., HOLT, J. F., AND ROBINSON, W. D. (1962) *Ann. rheum. Dis.*, **21**, 199 (A late effect on the cervical spine in ankylosing spondylitis).  
 MEIJERS, K. A. E., HEERMA VAN VOSS, S. F. C., AND FRANÇOIS, R. J. (1968) *Ibid.*, **27**, 333 (Radiological changes in the cervical spine in ankylosing spondylitis).  
 POLLEY, H. F., AND SLOCUMB, C. H. (1947) *Ann. intern. Med.*, **26**, 240 (Rheumatoid spondylitis: A study of 1,035 cases).  
 ROMANUS, R., AND YDÉN, S. (1955) 'Pelvo-spondylitis Ossificans'. Munksgaard, Copenhagen.  
 SCHALLER, J., BITNUM, S., AND WEDGWOOD, R. J. (1969) *J. Pediat.*, **74**, 505 (Ankylosing spondylitis with childhood onset).  
 SÉZE, S. DE, LACAPÈRE, J. P., AND AMOUDRUZ, J. (1952) *Rev. Rhum.*, **19**, 107 (Osteophytes et prétendus syndesmophytes vertebraux).  
 WILKINSON, M., AND BYWATERS, E. G. L. (1958) *Ann. rheum. Dis.*, **17**, 209 (Clinical features and course of ankylosing spondylitis).