

Occasional survey

Roy Cameron Lecture, 1971

Pathology, pathogenesis, and aetiology of rheumatoid arthritis*

L. E. GLYNN

MRC Rheumatism Research Unit, Canadian Red Cross Memorial Hospital, Taplow, Maidenhead, Berkshire, and the Kennedy Institute of Rheumatology, London

The three outstanding anatomical features of rheumatoid arthritis are inflammation with progressive deformity of joints, subcutaneous nodules especially over pressure points and sites of friction, and vascular lesions both necrotizing and obliterative.

Inflammation

The early stages of joint inflammation have for obvious reasons been much less well studied than the later. Nevertheless, a sufficient number of early lesions has now been documented to permit a clear picture of this early phase (Kulka, Bocking, Ropes, and Bauer, 1955). Thus, even by the end of the first week of clinical involvement, the histological changes of acute inflammation are well established. These include increased vascularity, endothelial swelling of vessels with some polymorphonuclear exudation, oedema and fibrin deposition both within the synovial membrane and upon its surface, and hyperplasia of the lining cells. In the normal joint these cells are of two kinds which can be readily distinguished with the electron microscope (Barland, Novikoff, and Hamerman, 1962):

(A) Cells with complex elongated processes, the filopodia, and many membrane-bound vesicles rich in acid hydrolases, *i.e.* lysosomes;

(B) Cells less complex in their surface structure and much poorer in lysosomes but richly endowed with rough endoplasmic reticulum.

The A cells are actively phagocytic and the B cells secretory in function. Since at least half the lining cells are of A or intermediate type, it is evident that the normal joint is liberally provided with scavengers, and if function determines structure we must conclude that normal wear and tear, even of a healthy joint, results in considerable quantities of detritus to be dealt with by the synovial phagocytic system. The ultimate fate of material dealt with by this phago-

cytic system is unknown: some at least passes *via* lymphatics to the local lymph nodes, which in rheumatoid arthritis are often enlarged and present a picture of non-specific reactive hyperplasia.

Hyperplasia of the lining cells remains a conspicuous feature of the lesion even after months or years. It is most conspicuous in the depths of crypts which result from folding of the overgrown membrane and may form a stratified structure seven or more cells thick. On the more exposed parts of the surface the hyperplasia is less pronounced, probably because of shedding of surface cells, and in these areas the surface is frequently covered by fibrin, which may be continuous with threads of similar material permeating the underlying synovial intima.

Even within the first week the affected synovium shows considerable increase in cellularity which becomes progressively greater with continuing activity. At first this is mainly the result of increase in number and size of the fixed tissue cells with a small admixture of lymphocytes, monocytes, and polymorphs. Later the lymphocytic component becomes more obvious with a special tendency to aggregate around or alongside small blood vessels while an increasing number of plasma cells infiltrates the loose tissue between these aggregates. Meanwhile, the villous processes of the membrane normally present in the various recesses of the joint become increased in size and number so as to constitute a conspicuous feature when the joint is opened. These too show the lining cell hyperplasia and cellular infiltration characteristic of the rest of the membrane, and in addition a particular tendency for the follicular aggregations of lymphocytes to develop reaction centres of pale-staining blast type cells closely resembling the germinal centres of the follicles of antigenically-stimulated lymph nodes (Fig. 1, opposite).

Further progression of joint damage appears to be associated with the aggressive activity of granulation

Accepted for publication February 2, 1972.

* Based on the Sir Roy Cameron Memorial Lecture of the Royal College of Pathologists delivered at the Royal College of Physicians, London, on May 5, 1971.

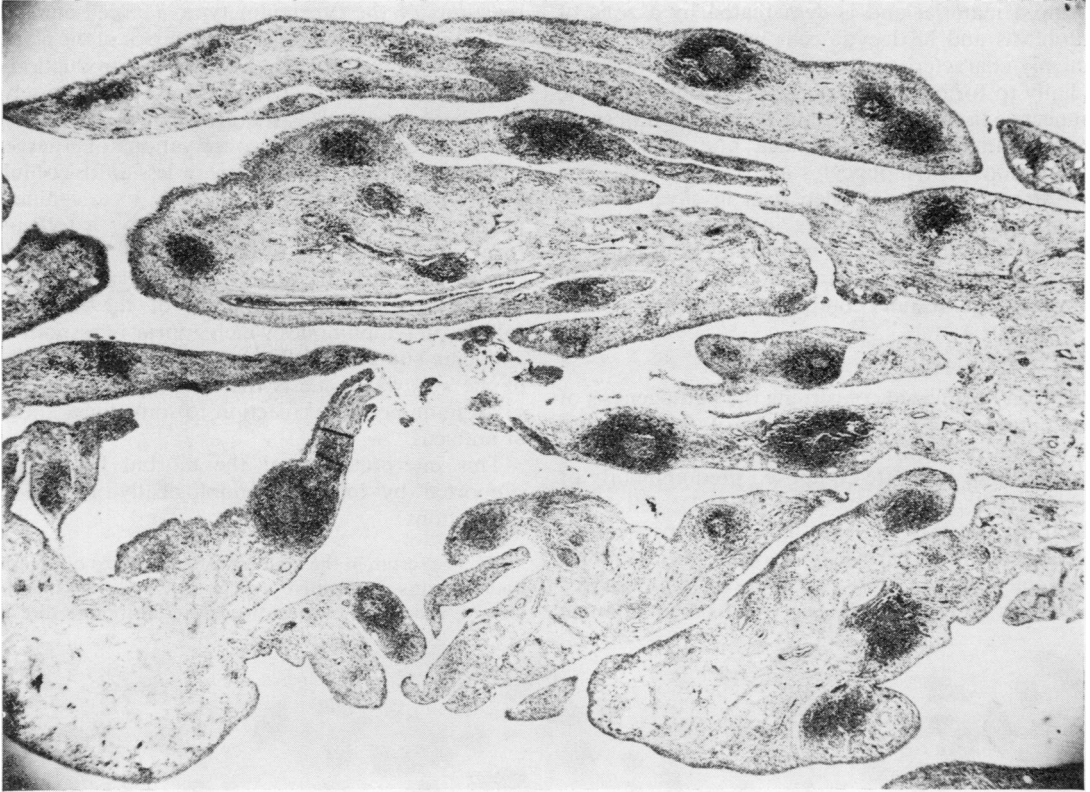


FIG. 1 Synovial membrane from an affected joint of a patient with rheumatoid arthritis. There is a striking degree of villous hyperplasia and several focal infiltrations of lymphocytes. Many of the foci show germinal centres. Haematoxylin and eosin. $\times 18$

tissue which extends across the surface of the articular cartilage while simultaneously undermining it from its margins. In this latter situation the adjacent bone is eroded with the aid of osteoclasts resulting in the so-called 'hook erosions', which impart a characteristic feature to the *x*-ray picture especially of the small joints in the hands and feet.

The progressive destruction of the joint structures, bone, cartilage, ligaments, and capsule is presumably accomplished by means of proteolytic and other enzymes released in the main from lysosomes of the infiltrating inflammatory cells, especially in the polymorphs and macrophages. Until the discovery of tissue collagenase, the dissolution of collagenous structures, which undoubtedly occurs, presented an insoluble problem in view of their resistance to the common tissue proteases at pH levels likely to occur *in vivo*. The discovery of collagenase, at first in metamorphosing tadpoles (Gross and Lapierre, 1962) and later in inflamed synovial tissue (Evanson, Jeffrey, and Krane, 1968), showed that enzymes capable of digesting native collagen at neutral pH do occur, especially where collagen is being absorbed.

Vascular lesions and nodules

The vascular lesions of rheumatoid arthritis are of two distinct types: an obliterating endarteritis seen especially in the arteries of the fingers, and a necrotizing arteritis characterized by fibrinoid necrosis of intima and media and affecting small muscular vessels almost anywhere. The necrotizing vasculitis is rare but is probably the commonest underlying cause of peripheral neuritis in rheumatoid arthritis.

Apart from the involvement of joints the most characteristic feature of adult rheumatoid arthritis is the subcutaneous nodule. This occurs most frequently over the elbows but can occur over any point of pressure or friction. Nodules may reach several centimetres in diameter and are extremely persistent but may shrink or even disappear during clinical remission or in response to steroid therapy. Their structure is remarkable. Typically they show a yellowish opaque core of necrotic tissue surrounded by dense translucent fibrous tissue which merges into the surrounding connective tissue. Histologically, the necrotic centre has the staining characters of so-called

fibrinoid material and is demarcated by a zone of fibroblasts and histiocytic cells which usually show a highly characteristic orientation of their long axis radially to form a pallasade. More peripherally, the connective tissue shows several aggregations of small vessels with swollen endothelia and perivascular aggregations of lymphocytes and plasma cells. The central necrotic areas, when seen in silver preparations, show collagen fibres in various stages of disintegration intermingled with amorphous material in which specific immunological stains reveal fibrin, immunoglobulins, and complement components.

Pathogenesis

What can be inferred concerning the pathogenesis of rheumatoid lesions from a study of their morbid anatomy? In the joints the most impressive feature is the cellular infiltrate composed predominantly of lymphocytes and plasma cells (Fig. 2), cell types which for the last 30 years have been increasingly identified as being primarily involved in immunological reactions. At least two types of lymphocytes have been distinguished: one involved in immune

reactions of the tuberculin type, *i.e.* cell-mediated reactions, the other possibly a precursor of the plasma cell line and therefore involved in the production of humoral antibodies. The plasma cells themselves have been accepted as the principal source of antibodies since the classical observations of Fagraeus (1948). In addition to the more or less diffuse cellular infiltration, the synovial membrane in a significant proportion of rheumatoid joints shows a follicular form of aggregation of lymphocytes around the central collection of paler germinal type cells. The picture is strongly reminiscent of the secondary follicles in lymph nodes which appear in response to antigenic stimulation. The straightforward histology of the synovial tissue is therefore highly suggestive of an immunological reaction to some local antigen or antigens.

This interpretation of the morbid histology is supported by many immunologically-oriented investigations:

(1) The serum in the majority of adult cases of rheumatoid arthritis is positive when tested for rheumatoid factors, which are now known to be antibodies directed

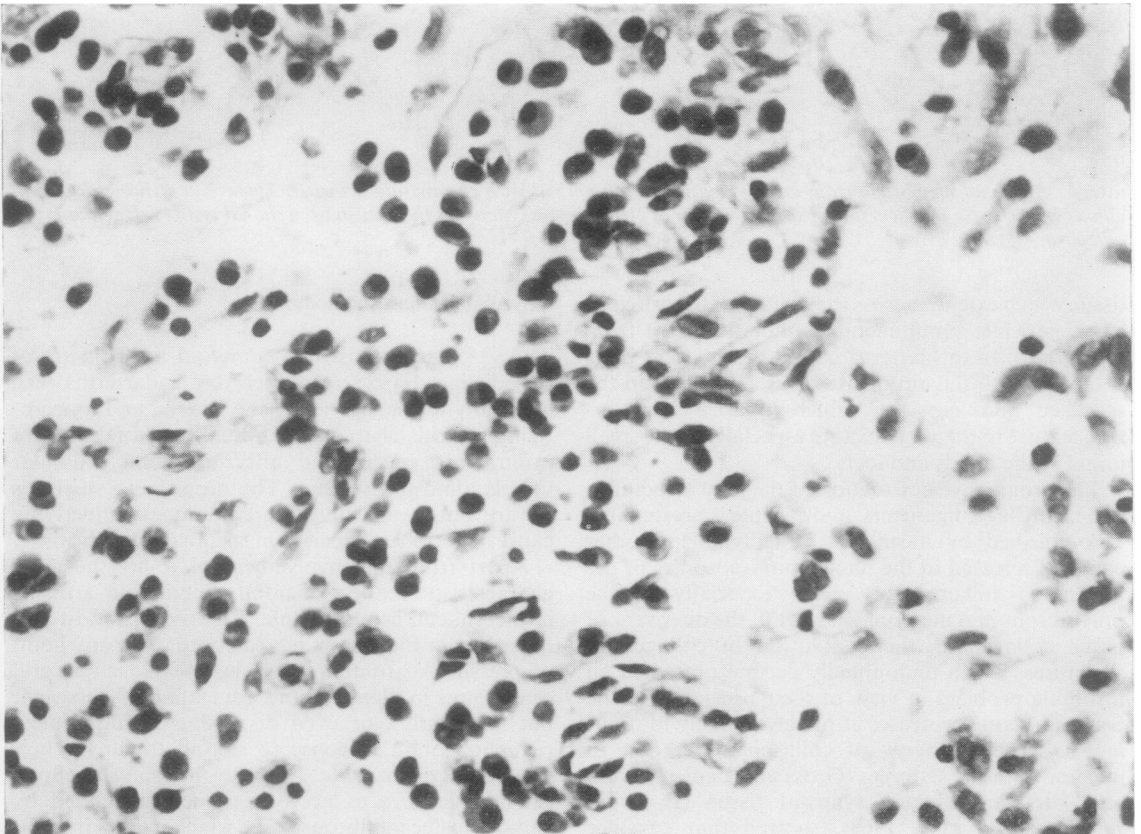


FIG. 2 Heavy infiltration of plasma cells in the synovial membrane obtained by biopsy of a rheumatoid joint. Haematoxylin and eosin. $\times 500$

against the individual's own gamma globulins (Glynn, 1968). Although some of these factors are capable of reacting with native gamma globulin, the most important factor reacts in the main with denatured globulin. The detection of these factors in the great majority of adult cases of rheumatoid arthritis when tests of high sensitivity are employed emphasizes the involvement of the immunological apparatus in the pathogenesis of this disease.

(2) By specific staining of the plasma cells in the synovium they have been shown to contain immunoglobulins of the IgG or IgM class (Mellors, Heimer, Corcos, and Korngold, 1959).

(3) The immunoglobulin in some of these plasma cells has the reactivity of rheumatoid factor and can be revealed by treating appropriate sections with fluorescein-labelled aggregated (denatured) IgG (the usual reactant for rheumatoid factor) (Mellors, Nowoslawski, Korngold, and Sengson, 1961).

(4) Complexes of antigen and antibody have been revealed by simultaneous staining with differently labelled reagents for the two components, *e.g.* with fluorescein and rhodamine (Bonomo, Tursi, Trizi, Gillardi, and Dammacco, 1970). Moreover, specific staining for the third component of complement β_{1c} has also revealed its presence in association with these complexes (Bonomo and others, 1970).

(5) The simultaneous estimation of the level of complement in serum and joint fluid by several investigators has established that the ratio of the fluid to the serum level is significantly lower than the corresponding ratio in non-rheumatoid joint effusions, thus implying local consumption (Hedberg, 1963).

(6) Kunkel and his colleagues at the Rockefeller University, New York, have recently shown that soluble complexes of antigen with antibody give specific precipitin reactions with the *q* fraction of CI. The use of this test has confirmed the presence of such complexes in rheumatoid synovial effusions (Agnello, Winchester, and Kunkel, 1970).

(7) The participation of a similar mechanism in the development of the subcutaneous nodules is suggested by the plasma cell reaction in their vicinity and the demonstration of immunoglobulins and β_{1c} in the necrotic centres of the lesions.

(8) Now that tuberculosis and chronic suppurative diseases have largely disappeared from the Western world rheumatoid arthritis is the commonest precursor or associate of amyloid degeneration. Although the precise metabolic disturbance underlying this degeneration is unknown, there can be little doubt that it is somehow related to prolonged immunological stimulation.

(9) The predominance of polymorphonuclear cells in the synovial fluid in rheumatoid arthritis has long been a problem in view of the absence of any demonstrable pyogenic infection. The chemotactic effect of complement fixed to immune complexes so clearly demonstrated by Cochrane (1968) is probably the answer.

(10) Necrotizing arteritis has many features in common with the experimental lesions originally produced in rabbits given massive injections of foreign serum (Rich and Gregory, 1943). The demonstration of fixed gamma

globulin and β_{1c} in the human lesion supports the view that this form of arteritis is the result of local deposition of immune complexes.

These ten observations together with the histopathology provide convincing evidence of the participation of some immunological reaction in the pathogenesis of rheumatoid arthritis.

Experimental production of rheumatoid-like lesions

The crucial test for any pathogenetic hypothesis is the reproduction of the corresponding lesions by experimental methods based on the pathogenesis in question.

NODULES

About 12 years ago Dr. S. K. Banerjee of Calcutta and I became interested in rheumatoid nodules, not primarily for their immunological significance, but because of the apparent persistence within them of masses of fibrin. Experience of other inflammatory lesions has shown that fibrin is usually removed with considerable expedition by a combination of proteolysis by tissue enzymes and organization by ingrowth of fibroblasts and capillaries. Why does this not occur in the rheumatoid nodule?

We therefore studied in experimental animals the removal and organization of fragments of fibrin implanted subcutaneously and found, perhaps not surprisingly, that there is a striking difference between the reaction to homologous fibrin and heterologous fibrin (Banerjee and Glynn, 1960). For example, a fragment of rabbit fibrin measuring approximately $1.0 \times 0.5 \times 0.5$ cm. implanted in a rabbit undergoes extensive organization in 7 days and by the 28th day can be identified only with difficulty as a minute fibrocellular body. The result with heterologous fibrin is strikingly different, so that despite some early cellular invasion in the first few days, by 28 days the implant is virtually intact and acellular but encapsulated by a broad band of fibroblasts and histiocytes. The tendency for the marginal cells to become oriented radially is particularly well shown in some areas and inevitably calls for comparison with the similar cellular arrangement around the necrotic centre of a rheumatoid nodule.

The similarity is equally striking when the more peripheral reactions are compared. In both lesions the peripheral areas show aggregations of thin-walled vessels with swollen endothelial cells and perivascular aggregations in which lymphocytes and plasma cells predominate.

We are satisfied for the following reasons that the differences in the reaction to the two varieties of fibrin is due to the antigenic behaviour of the heterologous material:

(1) The differences which take several days to appear occur earlier when the implant is repeated.

(2) Plasma cells known to be the principal producers of immunoglobulins are a striking feature, but only around the foreign implants.

(3) Humoral antibodies to the foreign fibrin and other serum proteins can be readily detected in the recipient's serum by the end of the first week.

(4) If a heterologous fibrin implant is repeated on two or three occasions, the host vessels in the vicinity may undergo acute necrotizing inflammation with fibrinoid necrosis of the wall and dense polymorph infiltration, *i.e.* lesions characteristic of the Arthus reaction.

The similar appearance of an implant of foreign fibrin to a rheumatoid nodule and the obvious immunological associations suggest the possibility that the rheumatoid nodule is also the expression of an immunological reaction to some local antigen. It also suggested to us the possibility of testing directly whether a similar local reaction within the joint could lead to a rheumatoid type of arthritis.

PRODUCTION OF EXPERIMENTAL IMMUNE ARTHRITIS

In view of the successful simulation of a rheumatoid nodule by implantation of foreign fibrin, it seemed

reasonable to retain this as the antigen in our work on immune arthritis. Rabbits were therefore immunized with human fibrin in Freund's complete adjuvant and subsequently challenged by the intra-articular injection of a sonicated suspension of the fibrin alone into one or both knees. Two major facts emerged from these experiments:

(1) Virtually all the features of the rheumatoid joint could be reproduced by this method (Dumonde and Glynn, 1960), namely lining cell and villous hyperplasia, perivascular lymphocytes and diffuse plasma cells, lymphoid follicles, pannus, erosion, and new bone formation (Figs 3 and 4).

(2) Inflammation remained active for several months, *i.e.* presumably after the antigen had been completely eliminated.

Up to this point we have shown, therefore, that the main individual lesions of rheumatoid arthritis, namely the nodules, vasculitis, and arthritis can arise from local immunological reactions and in view of the histology of the natural disease probably do arise in this way. But we still have no indication as to the nature of the offending antigen or antigens.

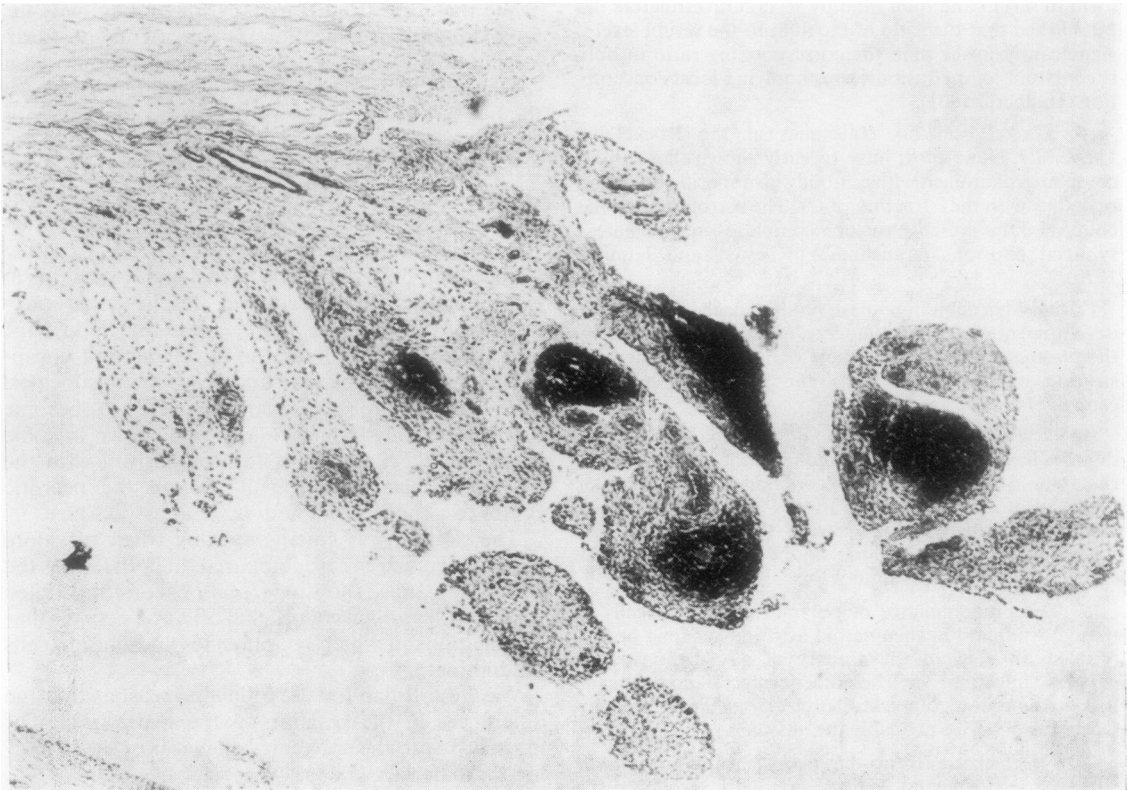


FIG. 3 *Synovial membrane from the knee joint of a rabbit with experimental immune arthritis of 8 weeks' duration. Note the villous hyperplasia and follicular aggregations of lymphocytes. Haematoxylin and eosin. × 70*

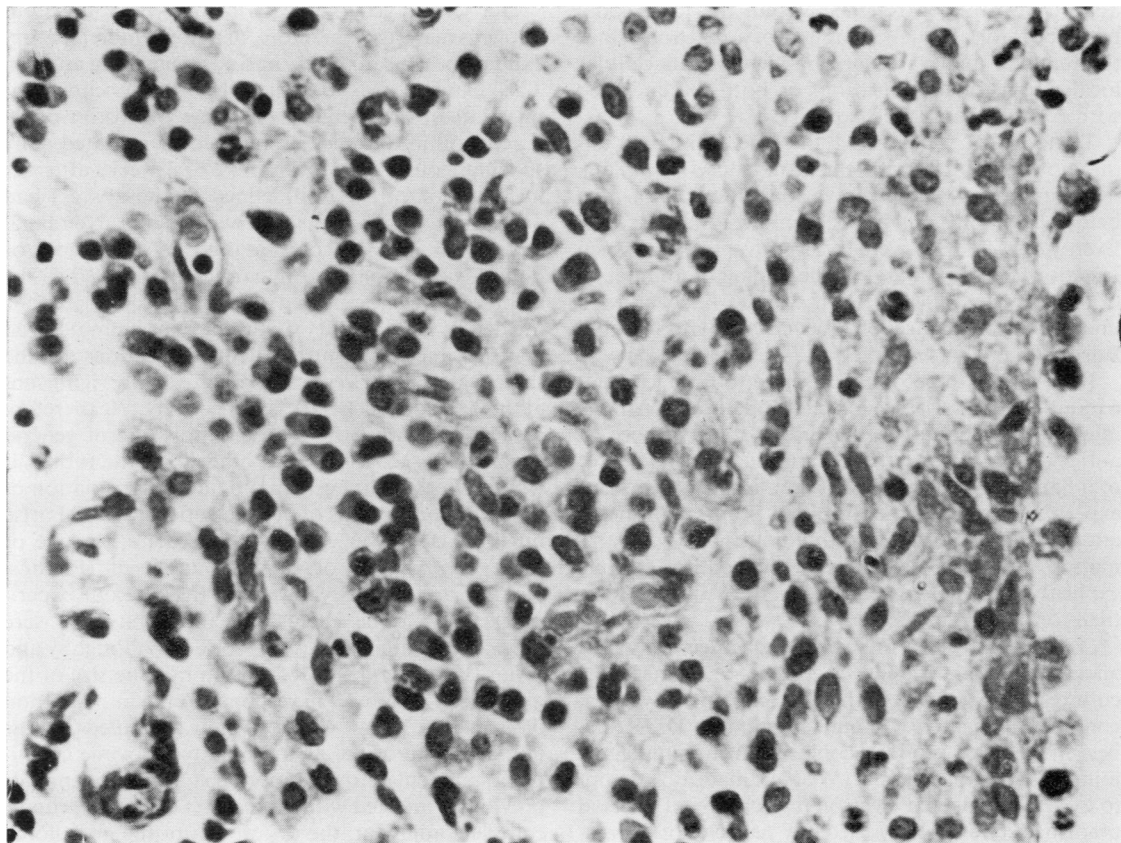


FIG. 4 Heavy infiltration of plasma cells in the synovial membrane of a rabbit with experimental immune arthritis of 12 weeks' duration. Haematoxylin and eosin. $\times 500$

Retention of antigen

Before considering this aspect of the problem, let us consider the second fact that emerged from our experimental arthritis, namely that the inflammation in the injected joint may persist till well after the initiating antigen has been eliminated. This conclusion, if correct, is of such far-reaching importance to the whole realm of chronic inflammation that it became essential to monitor the retention of antigen by the most sensitive methods available. We have therefore studied the retention of antigen in the rabbit knee joint in various circumstances by the use of ovalbumin labelled with ^{125}I (Consdon, Doble, Glynn, and Nind, 1971). This has a half-life of 60 days, and we therefore hoped to be able to say with some confidence when the antigen was entirely eliminated. Unfortunately, even with such a labelled antigen, the precise time of complete elimination could not be determined because the elimination is exponential, and with the decay of the label it was not possible clearly to distinguish retained traces of radioactivity from the background level. Nevertheless, two facts of some significance emerged:

(1) The retention of antigen in the joint of the immunized animals is considerably greater than in the non-immunized especially during the first few days, but is still obvious at 4 weeks when the level in the latter has fallen from 8 mg. (the injected dose) to about 1 μg . whilst in the former some 20 μg . are still present.

(2) Further elimination in the immunized animal could still be followed for several months but ceased to be reliably detected at about 6 months.

The important question still unanswered is what significance is to be attached to levels of 1 μg . antigen distributed throughout the whole knee joint. The answer to this question was sought in two ways:

(1) To establish the minimal dose of antigen capable of eliciting in the immunized animal an inflammatory reaction still readily detectable 4 to 8 weeks after challenge. This dose was established at about 100 μg .; with 10 μg . and 1 μg . only insignificant traces of inflammation if any, were detected.

(2) Although the dose of 1 μg . injected into the knee joint appeared incapable of eliciting a significant inflammatory response, it is still possible that a similar

quantity of antigen retained within the joint could be responsible for an inflammatory reaction, since the retained material might by virtue of its cellular localization, or modification, or both, be endowed with enhanced antigenic capacity.

To test this we injected the knee joints of unimmunized rabbits with the usual dose of 10 mg. ovalbumin and waited for various intervals of time before beginning our usual immunization schedule. Even when 4 weeks were allowed to elapse between injection of the joint and the beginning of immunization, animals killed several weeks later showed unequivocal evidence of chronic synovitis (Webb, Ford, and Glynn, 1971).

It is evident, therefore, that for periods up to about 6 months the persistence of active inflammation in the injected joint could be the result of persistence of antigen. But, in view of the somewhat limited degree of inflammation shown by the animals in the previous experiment and the presumed continuation of antigen elimination, it is highly unlikely that inflammation persisting for 1 year or more is entirely explicable on this basis. Two other possibilities have therefore been considered:

(1) The activation of some latent infection in the affected animal. Standard aerobic and anaerobic cultures of material from the affected joints have been continually negative. A single attempt by Dr. Klineberger Nobel to grow mycoplasma from an affected joint was also unsuccessful. We have made no attempt to isolate a virus, but electron microscopy of affected tissue has so far not revealed any particles of a virus-like nature.

(2) If the continuing inflammation is not the result of persistent antigen or of an infecting agent, one is forced to conclude, especially in view of the immunological character, that the continuing inflammation is the result of some endogenous antigen appearing within the affected tissues. In other words an auto-antigen.

Autogenous antigens

We have sought in two ways to show whether an inflammatory arthritis could be induced in rabbits by means of autogenous antigens.

In our earlier experiments with fibrin we included animals immunized and challenged with their own fibrin in place of foreign fibrin. Although the incidence of arthritis was much less with the autogenous material, about 5 per cent. of animals did develop an unequivocal arthritis. Since inflammatory exudates are highly complex mixtures of serum and tissue constituents in various stages of denaturation and disintegration, it seemed probable that auto-immunization might well arise to one or more of these constituents independently of any immunological response to fibrin.

Our second group of experiments with autogenous antigens made use, therefore, of a sterile inflammatory exudate both as immunizing and challenging antigen. This exudate was obtained by the subcutaneous injection of a 1 per cent solution of croton oil in arachis oil into a pocket prepared by repeated daily subcutaneous injection of air; 2 to 3 weeks after the injection of oil, a well-defined sterile abscess had developed which was excised under Nembutal anaesthesia and the contents used for autologous or homologous immunization and challenge. When the arthritis in the immunized animals was compared for incidence and severity with that in unimmunized controls receiving intra-articular injections of the same material, the results were statistically significant at the 0.01 and 0.0001 levels respectively. We therefore concluded that, if these observations are of general significance, *i.e.* for species other than the rabbit, it would appear that accentuation and perpetuation of inflammatory lesions of diverse aetiology could arise on the basis of an autoimmune reaction to one or more components of the exudate itself (Phillips, Kaklamanis, and Glynn, 1966). Because our experiments were done exclusively in rabbits we were particularly interested in the work of Willoughby and Ryan (1970), who showed that in rats the size of the granuloma produced in response to the implantation of a cotton pellet was strikingly modified by the immune state of the animal relative to some constituent antigen of the granuloma. Thus, in animals previously injected with granuloma extra in Freund's complete adjuvant, the dry weight of the granuloma was some 125 per cent. greater than in the untreated animals, whereas in animals presumably tolerant to the granuloma antigen, as a result of neonatal injection, the mean granuloma weight was only 27 per cent. of the control weight.

The independent demonstration in two animal species of an enhanced inflammatory reaction as a result of procedures aimed at immunization with inflammatory material suggests that the phenomenon is of general validity. The suggestion, therefore, that the persistence of the inflammatory process in rheumatoid arthritis could be the result of an immune response to some local product of the inflammatory exudate is based upon more than mere speculation.

There is not only the experimental evidence just presented; the presence of rheumatoid factors, themselves autoantibodies to various determinants on the immunoglobulin G molecule, testifies to the capacity of the rheumatoid subject to mount an autoimmune response of the kind here postulated. That is not to suggest that denatured gamma globulin is the offending antigen responsible for chronicity, although there is some evidence that its presence in a joint can excite severe inflammatory response in a rheumatoid individual (Hollander, McCarty, Astorga, and Castro-Murillo, 1965; Rawson, Abelson, and

Hollander, 1965; Restifo, Lussier, Rawson, Rockey, and Hollander, 1965).

Initiation of the inflammatory response

In addition to the question as to the nature of the antigen responsible for the perpetuation of inflammation, we are still left with the question what initiates the inflammatory response in the first instance. We have already pointed out that, even in the earliest lesions, the histology is highly suggestive of an immune response, but at this stage the probability is that the antigen is exogenous and presumably micro-organismal. The last few years have seen a multiplicity of claims to the isolation of various organisms with the imputation that here at last is the cause of rheumatoid arthritis. If, however, what I have already said is applicable to man, it may well be that there is no single micro-organism that can be acclaimed as the cause of rheumatoid arthritis. It is, in our present state of knowledge, just as probable that several individual organisms can share the initiating role provided that they can enter and establish themselves within the synovial membrane and there constitute an effective antigenic stimulus. Mycoplasmata, viruses, diphtheroids, *Listerella*, all have their proponents and they could all be right in some instances; but these are the initiators and as such are perhaps less important than the factors leading to perpetuation.

Conclusion

Our present interpretation of classical chronic rheumatoid arthritis is, therefore, that it is a two-phase disease in which by no means all patients enter the second phase. Phase one results from some systemic infection by an organism with a tendency to settle in joints, where it excites an inflammatory reaction largely as a result of a local immune response. This phase may last some 6 months, possibly even 12 months, but with the elimination of the antigen eventually subsides. Continuation of disease activity beyond this date could theoretically arise from re-infection with another initiating agent, but in most instances it results from the development of autoimmunization to some antigen or antigens engendered by the initial inflammation itself. The well-known natural disease in pigs, which is due to infection with *Erysipelothrix insidiosus*, seems to follow precisely this pattern. It has been known for many years that systemic infection of pigs with this organism results in a chronic polyarthritis which resembles rheumatoid arthritis in many of its anatomical features and which apparently long outlasts the ability to demonstrate living organisms in the joints (Collins and Goldie, 1940). Dr. M. Ajmal, working in the Department of pathology at the Royal Veterinary College in London, has recently confirmed that even the most strenuous

attempts may fail to isolate living organisms from many of the affected joints (Ajmal, 1969). Moreover, with a strain adapted to rabbits, he was not only able to confirm these results but showed that despite the termination of the infective phase by penicillin, to which these organisms are highly sensitive, the arthritis continued unaffected. Similar results were also obtained in pigs with experimentally-induced infection terminated with penicillin. Thus, in an experimentally infected pig with arthritis, treatment with penicillin for 6 days starting on the 10th day after infection completely eliminated the infection, as shown by failure to isolate the organisms from any of the tissues. Nevertheless, the arthritis remained active as could be seen from the histology of a joint from an animal killed some 150 days later. It is conceivable that this continuing activity is the result of the persistence of antigenic bacterial residues in the synovial tissues and we are at present looking for these employing for the purpose fluorescein-labelled antibodies. A still more sensitive method which we hope to apply is the use of ¹⁴C-labelled *Erysipelothrix* for the induction of the arthritis. Once again, failure to identify antigenic residues despite continuing activity of inflammation would suggest the participation of an autoogenous antigen.

Having thus arrived at the conclusion that chronic rheumatoid arthritis is a two-phase disease, it is of interest to see what light this throws upon some of its clinical peculiarities. It has been noted by many observers (Duthie, Brown, Truelove, Baragar, and Lawrie, 1961; Bywaters and Dresner, 1952) that the prognosis is much better in patients seen within 12 months of the onset than in those seen later. Since there is not at present any specific treatment available, this observation is unlikely to be merely the result of earlier treatment. On the two-phase hypothesis, however, the better prognosis of the cases seen earlier is to be expected, since these would include not only those destined to enter phase two but also those who will not enter that phase. Patients seen after the first year will obviously consist mainly of patients already in phase two, and hence the worse prognosis. A similar explanation presumably underlies the well-established correlation between the presence of rheumatoid factor (seropositive cases) and disease severity, including prognosis, since the presence of rheumatoid factor may be taken as direct evidence that the disease has already entered the autoimmune second phase.

Evidence for the existence of rheumatoid arthritis confined to phase one has come particularly from epidemiological studies in Great Britain and the United States of America, especially those studies in which whole communities have been investigated for the presence of rheumatoid disease. In both countries the investigators have been impressed by the high incidence of a so-called benign form of

polyarthritis which has most of the clinical features of the classical disease but from which recovery is complete within one year or less (Lawrence, 1964; Cathcart and O'Sullivan, 1969). This benign polyarthritis I would interpret as phase one of the disease which has failed to enter phase two owing to the patient's resistance to the development of autoimmunity. Patients with the self-limiting arthritis

associated with rubella infection may also be regarded as belonging to this category.

As a morbid anatomist, I like to think that, in the study of diseases of unknown aetiology, it is still possible to find in the pure anatomy of the lesions clues to both pathogenesis and aetiology, but whether in rheumatoid arthritis we have followed these clues with accuracy and insight time alone will judge.

References

- AGNELLO, V., WINCHESTER, R. J., AND KUNKEL, H. G. (1970) *Immunology*, **19**, 909 (Precipitin reactions of the C1q component of complement with aggregated γ -globulin and immune complexes in gel diffusion)
- AJMAL, M. (1969) *Res. vet. Sci.*, **10**, 579 (*Erysipelothrix rhusiopathiae* and spontaneous arthritis in pigs)
- BANERJEE, S. K., AND GLYNN, L. E. (1960) *Ann. N.Y. Acad. Sci.*, **86**, 1064 (Reactions to homologous and heterologous fibrin implants in experimental animals)
- BARLAND, P., NOVIKOFF, A. B., AND HAMERMAN, D. (1962) *J. Cell Biol.*, **14**, 207 (Electron microscopy of the human synovial membrane)
- BONOMO, L., TURSI, A., TRIZIO, D., GILLARDI, U., AND DAMMACCO, F. (1970) *Immunology*, **18**, 557 (Immune complexes in rheumatoid synovitis: a mixed staining immunofluorescence study)
- BYWATERS, E. G. L., AND DRESNER, E. (1952) *Quart. J. Med.*, **21**, 463 (Prognosis in rheumatoid arthritis)
- CATHCART, E. S., AND O'SULLIVAN, J. B. (1969) *Ann. N.Y. Acad. Sci.*, **168**, 41 (A longitudinal study of rheumatoid factors in a New England town)
- COCHRANE, C. G. (1968) *J. Allergy*, **42**, 113 (The role of immune complexes and complement in tissue injury)
- COLLINS, D. H., AND GOLDIE, W. (1940) *J. Path. Bact.*, **50**, 323 (Observations on polyarthritis and on experimental *Erysipelothrix* infection of swine)
- CONSDEN, R., DOBLE, A., GLYNN, L. E., AND NIND, A. P. (1971) *Ann. rheum. Dis.*, **30**, 307 (Production of a chronic arthritis with ovalbumin. Its retention in the rabbit knee joint)
- DUMONDE, D. C., AND GLYNN, L. E. (1962) *Brit. J. exp. Path.*, **43**, 373 (The production of arthritis in rabbits by an immunological reaction to fibrin)
- DUTHIE, J. J. R., BROWN, P. E., TRUELOVE, L. H., BARAGAR, F. D., AND LAWRIE, A. A. (1961) 'Course and prognosis in rheumatoid arthritis', in 'Atti X Congresso della Lega Internazionale contro il Reumatismo, 1960', vol. 1, p. 113. Minerva, Medica, Rome
- EVANSON, J. M., JEFFREY, J. J., AND KRANE, S. M. (1968) *J. clin. Invest.*, **47**, 2639 (Studies on collagenase from rheumatoid arthritis synovium in tissue culture)
- FAGRAEUS, A. (1948) *J. Immunol.*, **58**, 1 (The plasma cellular reaction and its relation to the formation of antibody *in vitro*)
- GLYNN, L. E. (1968), in 'Clinical Aspects of Immunology', ed. P. G. H. Gell and R. R. A. Coombs, 2nd ed., p. 848. Blackwell Scientific Publications, Oxford
- GROSS, J., AND LAPIERE, C. M. (1962) *Proc. nat. Acad. Sci. (Wash.)*, **48**, 1014 (Collagenolytic activity in amphibian tissues)
- HEDBERG, H. (1963) *Acta rheum. scand.*, **9**, 165 (Studies on the depressed hemolytic complement activity of synovial fluid in adult rheumatoid arthritis)
- HOLLANDER, J. L., MCCARTY, D. J. Jr., ASTORGA, G., AND CASTRO-MURILLO, E. (1965) *Ann. intern. Med.* **62**, 271 (Studies on the pathogenesis of rheumatoid joint inflammation. I)
- KULKA, J. P., BOCKING, D., ROPES, M. W., AND BAUER, W. (1955) *Arch. Path.*, **59**, 129 (Early joint lesions of rheumatoid arthritis)
- LAWRENCE, J. S. (1964) 'The epidemiology of rheumatic diseases', in 'Textbook of the Rheumatic Diseases', ed. W. S. C. Hopeman, 3rd ed., p. 91. Livingstone, Edinburgh
- MELLORS, R. C., CEIMER, R., CORCOS, J., AND KORNGOLD, L. (1959) *J. exp. Med.*, **110**, 875 (Cellular origin of rheumatoid factor)
- , NOWOSLAWSKI, A., KORNGOLD, L., AND SENGSON, B. L. (1961) *J. exp. Med.*, **113**, 475 (Rheumatoid factor and the pathogenesis of rheumatoid arthritis)
- PHILLIPS, J. M., KAKLAMANIS, P., AND GLYNN, L. E. (1966) *Ann. rheum. Dis.*, **25**, 165 (Experimental arthritis associated with autoimmunization to inflammatory exudates)
- RAWSON, A. J., ABELSON, N. M., AND HOLLANDER, J. L. (1965) *Ann. intern. Med.*, **62**, 281 (As above, Hollander *et al.*, part II)
- RESTIFO, R. A., LUSSIER, A. J., RAWSON, A. J., ROCKEY, J. H., AND HOLLANDER, J. L. (1965) *Ibid.*, **62**, 285 (as above, part III)
- RICH, A. R., AND GREGORY, J. E. (1943) *Bull. Johns Hopk. Hosp.*, **72**, 64 (The experimental demonstration that periarteritis nodosa is a manifestation of hypersensitivity)
- WEBB, F. W. S., FORD, P. M., AND GLYNN, L. E. (1971) *Brit. J. exp. Path.*, **52**, 31 (Persistence of antigen in rabbit synovial membrane)
- WILLOUGHBY, D. A., AND RYAN, G. B. (1970) *J. Path.*, **101**, 233 (Evidence for a possible endogenous antigen in chronic inflammation)