

Case report

Rheumatoid plantar synovial cysts

HARRY BIENENSTOCK

From the Department of Rheumatic Diseases, the Hospital for Special Surgery, Cornell Medical Center, New York, N. Y.

Bienenstock, H. (1975) *Annals of the Rheumatic Diseases*, 34, 98. Rheumatoid plantar synovial cysts. A patient is described with rheumatoid arthritis and a painful synovial cyst, which originated from a metatarsophalangeal joint and presented as a swelling on the plantar surface of the foot. The cyst was successfully excised.

Rheumatoid synovial cysts are known to occur in a variety of locations. This report describes a rheumatoid protrusion cyst originating on the plantar aspect of the foot.

Case report

A 64-year-old woman with widespread rheumatoid arthritis of 15 years' duration presented herself to the Arthritis Clinic because of increasing pain and deformity of both feet. She had been treated with salicylates, parenteral and oral corticosteroids, and gold salts in the past without remission of her disease. Her treatment programme when first seen consisted of prednisone 5–10 mg/day, dextropropoxyphene 65 mg q.i.d., and indomethacin 25 mg t.i.d. For at least 10 years she had noted ulnar deviation of the fingers and painful deformities of both feet. A painful cyst-like swelling had been present on the volar surface of the left foot for about 4 years. It had been injected with corticosteroids on a number of occasions without change in size or relief of pain.

On physical examination the patient was moderately obese. Her blood pressure was 160/80 mmHg. General medical examination was unremarkable. There was marked bilateral ulnar deviation of the fingers at the metacarpophalangeal joints. The metacarpal heads were easily palpable with complete dislocation of the metacarpophalangeal joints of all fingers. In addition, there was considerable soft tissue swelling of the dorsum of the right wrist. A single firm nodule was present on the lateral aspects of each proximal ulna. There was subluxation of the heads of all the metatarsophalangeal joints. A 2 × 4 cm, tense, tender mass in which numerous nodules could be felt was present on the plantar surface of the left forefoot encompassing the second and third metatarsophalangeal joints and extending proximally the length of the metatarsals (Fig. 1). Pressure on the plantar mass resulted in protrusion of a small, cystic swelling between the third and fourth toes on the dorsum of the left foot.

LABORATORY DATA

Hg 13.7 g/dl, WBC $7.4 \times 10^9/l$ (7400/mm³), ESR 57 mm/h (Westergren). Latex fixation—the latex fixation test is positive in titre of 1:5120, fluorescent antinuclear antibodies

studies showed a 2+ speckled pattern. Roentgen examination of the hands showed extensive erosions and subluxations of the metacarpophalangeal joints of the hands and metatarsophalangeal joints of the feet. A large, soft tissue shadow extended from the second to fourth metatarsophalangeal joints on the left (Fig. 2). Aspiration of the mass on the plantar aspect of the foot yielded 1 cm³ of cloudy yellow fluid. Five ml renographin was injected

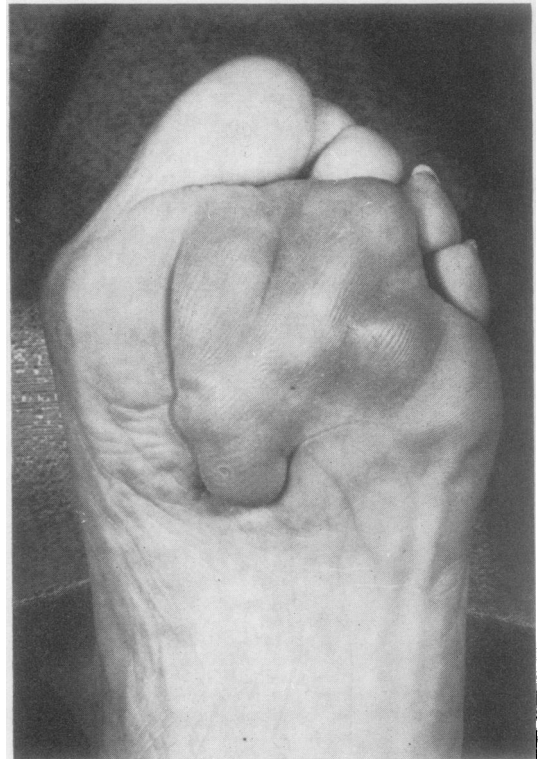


FIG. 1 Multinodular mass on the plantar surface of the left foot

Accepted for publication May 28, 1974.

Address for reprints: Dr. Harry Bienenstock, Coney Island Hospital, Ocean and Shore Parkways, Brooklyn, New York 11235, U.S.A.

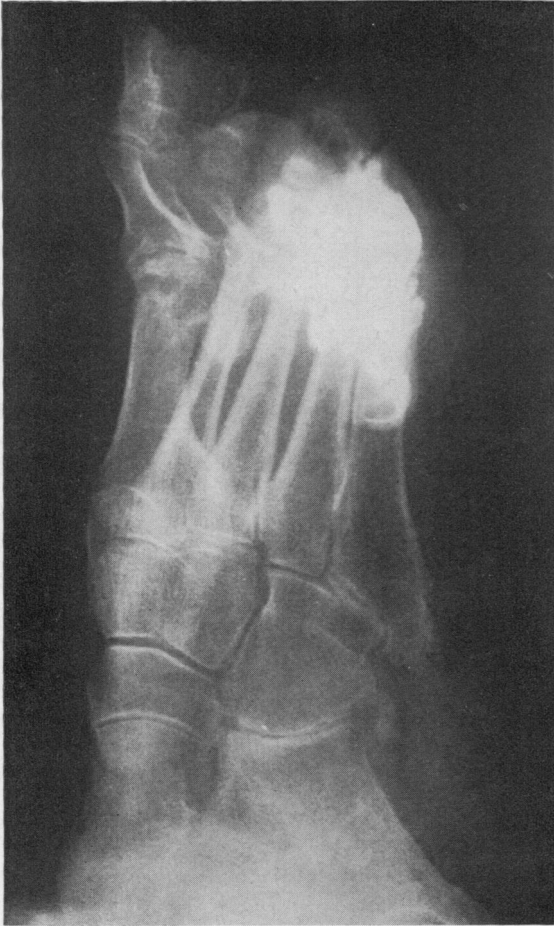

FIG. 2 Outline of the cystic mass after injection of contrast material

through the same needle. A large irregular mass that extended to the dorsum of the foot was outlined.

The patient was referred for foot surgery. At operation, the dislocated metatarsal heads were excised and hemiphalangectomies performed on the second through the fifth toes bilaterally. Considerable redundant bursal tissue was noted as well as marked synovial outpouchings

from the capsules of the joints. These outpouchings were more prominent on the left side and accounted for much of the subcutaneous swelling on the patient's foot. This excess tissue was excised at surgery. The patient is now able to walk with considerably less discomfort and the cystic swellings have not recurred.

Discussion

Various cystic subcutaneous swellings have been described in rheumatoid disease by Palmer (1969). Included were small protrusion cysts over the dorsal surface of the metacarpophalangeal joints, distension of flexor tendon sheaths on the ventral aspect of the fingers, and involvement of all groups of tendon sheaths of the wrists. Other locations particularly prone to cystic swelling are the knee (Baker, 1885; Harvey and Corcos, 1960; Kogstad, 1965) and the hip (Coventry, Polley, and Weiner, 1959), where symptoms may be localized to the joint or may be referred to adjacent structures by compression (Watson and Ochsner, 1967). Ehrlich has described anticubital fossa cysts that bear strong anatomical similarity to popliteal cysts (Ehrlich, 1972). Synovial outpouchings of flexor tendon sheaths of the feet have not been described in rheumatoid disease. The findings in this case resemble those observed in rheumatoid disease of the flexor tendon sheaths of the hand in a number of ways. Hand protrusion cysts are usually seen in patients with long-standing rheumatoid disease. Distension of the flexor tendon sheaths on the ventral surface may produce generalized enlargement of the finger. Attempts to aspirate fluid from the cysts are usually unsuccessful, but the lesions may be outlined by injection of contrast material. An increase in hydrostatic pressure within the cyst may result in a blow-out with herniation of synovial membrane through the overlying capsule.

The nodulocystic plantar mass that dissected to the dorsum of the foot in this case was found to consist of proliferative synovium, redundant bursal tissue, and numerous synovial outpouchings. The progressive nature of these lesions suggests that early excision of plantar synovial cysts may prove to be the treatment of choice.

References

- BAKER, W. M. (1885) *St. Barts Hosp. Rep.*, **21**, 177 (The formation of abnormal synovial cysts in connection with the joints)
- COVENTRY, M. B., POLLEY, H. F., AND WEINER, A. D. (1959) *J. Bone Jt Surg.*, **41A**, 721 (Rheumatoid synovial cyst of the hip)
- EHRlich, G. E. (1972) *Ibid.*, **54A**, 165 (Antecubital cysts in rheumatoid arthritis—a corollary to popliteal (Baker's) cysts)
- HARVEY, J. P., AND CORCOS, J. (1960) *Arthr. and Rheum.*, **3**, 218 (Large cysts in the lower leg originating in the knee occurring in patients with rheumatoid arthritis)
- KOGSTAD, O. (1965) *Acta rheum. scand.*, **11**, 194 (Baker's cyst)
- PALMER, D. G. (1969) *Ann. intern. Med.*, **70**, 61 (Synovial cysts in rheumatoid disease)
- WATSON, J. D., AND OCHSNER, S. F. (1967) *Amer. J. Roentgen.*, **99**, 695 (Compression of the bladder due to 'rheumatoid' cysts of the hip joint)