

Cardiac valvular disease in chronic inflammatory disorders of connective tissue

Factors influencing survival after surgery

D. B. YATES AND J. T. SCOTT

From Charing Cross Hospital and Kennedy Institute of Rheumatology, London

Yates, D. B., and Scott, J. T. (1975). *Annals of the Rheumatic Diseases*, **34**, 321–325. **Cardiac valvular disease in chronic inflammatory disorders of connective tissue. Factors influencing survival after surgery.** Three cases of cardiac valvular disease complicating chronic inflammatory disorders of connective tissue are described. Each underwent surgical valve replacement.

The outcome in the first case, a patient with aortitis complicating Reiter's syndrome and in good health otherwise, has been excellent. The other two patients, one with rheumatoid arthritis and vasculitis, the other with systemic lupus erythematosus and nephritis, died after operation as the result of their systemic disease.

The importance of systemic features in assessing this type of patient is emphasized.

A comprehensive review of aortic incompetence in rheumatoid arthritis, by Iveson, Thadani, Ionescu, and Wright (1975), has drawn attention to the feasibility of valve replacement despite the presence of severe joint disease. The local cardiac lesion and the state of the joints are obviously highly relevant factors in prognosis, but in assessing patients with connective tissue disease for surgery the presence of other systemic lesions, so often present in these patients, must be borne in mind because they may themselves determine the individual outcome.

This point is illustrated by the following three cases.

Case reports

CASE 1 REITER'S SYNDROME

A male first presented in 1955 at the age of 22 with arthritis, iritis, and circinate balanitis. A diagnosis of Reiter's syndrome was made (and more recently he has been shown to possess HL-A27 antigen). His joint symptoms persisted, though well controlled by symptomatic treatment, and from time to time there were infrequent exacerbations of iritis.

In 1969, at the age of 36, a soft early diastolic aortic murmur was heard on routine examination, although at this time the patient had no symptoms referable to the cardiovascular system. Specific serological tests for

syphilis were negative. Over the next 2 years there was a remission of arthritis and iritis but he complained of increasing exertional dyspnoea. He was now found to have a collapsing pulse (blood pressure 150/50 mmHg), and the diastolic murmur had become much louder. There was moderate left ventricular hypertrophy. Cardiac angiography revealed moderately severe aortic incompetence with a dilated aorta. There was no evidence of any other valvular disease, and the patient underwent aortic valve replacement with a glutaraldehyde homograft. Operative findings were those of severe aortic regurgitation with a large aortic root and slightly irregular dilatation of the posterior aspect of the aorta. The aortic wall was thickened with glairy-looking tissue between media and adventitia. The intima appeared normal, but all three aortic valve leaflets were shrivelled.

Histological examination of the aorta showed marked fibrous thickening of the adventitia. The media was disrupted by infiltrations of lymphocytes and plasma cells associated with endarteritis (Fig. 1).

The patient made an uneventful recovery and, apart from two exacerbations of arthritis, has remained well over the 4-year period since operation.

CASE 2 RHEUMATOID ARTHRITIS

A female developed seropositive erosive rheumatoid arthritis in 1961 at the age of 48. Her course during the following 12 years was characterized by a remarkable profusion of rheumatoid nodules, at one time a total of 69 being clinically detectable, including two within the

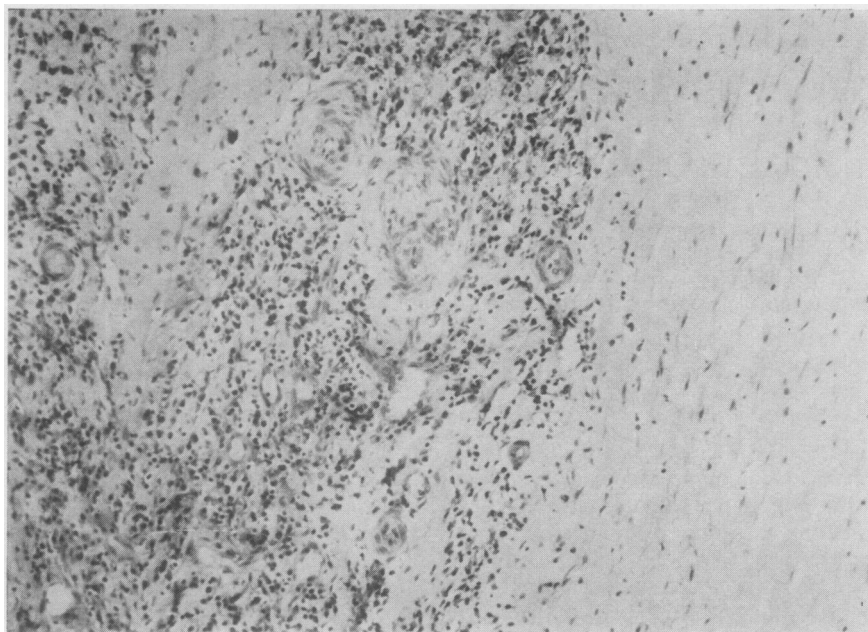


FIG. 1 Case 1. Section through aortic wall, showing mononuclear cell infiltration and endarteritis within the media. $\times 117$

sheath of rectus abdominis. A further feature was recurrent ulceration of the legs, but at no stage were there any other clinical signs of vasculitis.

She had no symptoms referable to the cardiovascular system and at a routine clinic visit in 1972 it was specifically noted that no cardiac murmurs were present. Ten days later, however, she was admitted to hospital with acute pulmonary oedema. Examination showed a collapsing pulse and a loud early diastolic murmur along the left sternal edge. A diagnosis of aortic regurgitation was confirmed by cardiac catheterization. Severe heart failure was barely controlled with medical treatment and she was unable to walk because of dyspnoea. Aortic valve replacement was therefore carried out using a Starr prosthesis. At the time of operation, her rheumatoid disease appeared to be in partial remission on a daily drug regimen of prednisolone 8 mg, phenylbutazone 300 mg, and aspirin 2.6 g; the skin ulceration had healed several months before.

At operation the external appearance of the aorta was normal, but there was a marked diastolic thrill over the valve and the left ventricle was enlarged. The aortic intima appeared normal but the aortic cusps were thickened, mostly at their bases. Nodules were visible at the base of the right coronary cusp, and the valve ring was distorted. The nodules showed the classical histological appearance of rheumatoid granulomata (Fig. 2). The prosthesis was successfully inserted and the patient made an uneventful recovery during the immediate post-operative period.

Her subsequent cardiac condition was seen to be greatly improved. She was not in heart failure and diuretics were discontinued without difficulty. To reduce complications with anticoagulant therapy, aspirin and phenylbutazone were replaced by ibuprofen 1.2 g daily in addition to prednisolone. Two days after the operation, however, the patient again complained bitterly of pain from her

arthritis which was objectively more severe. Within one week of operation she had developed 23 new subcutaneous nodules and the skin of the legs began to break down at the sites of previous ulceration (Fig. 3).

Before operation DAT was 1:64 or 1:128. After operation it fell to 1:2. Massive exchange of the patient's plasma with donor blood took place during the operation, but the DAT remained negative for 10 weeks, during which the recrudescence of arthritis, nodules, and ulceration occurred. The titre subsequently rose to its preoperative level. The inter-relationship of these events is unknown.

This situation—striking improvement in cardiac status with florid activity of arthritis, nodules, and ulceration—continued for 9 months. Over this period, arthritis was controlled symptomatically with prednisolone, ibuprofen, and analgesics. Gold therapy was started, but there was no alteration in nodules or ulceration. Eventually, the ulcerated areas of skin became infected. Despite intensive antibiotic therapy, the patient developed overwhelming septicaemia from which she died.

CASE 3 SYSTEMIC LUPUS ERYTHEMATOSUS

A female first presented in 1965 at the age of 22 with polyarthralgia of small joints and no other symptoms. She gave a history of definite rheumatic fever at the age of 5 and a soft apical midsystolic murmur was now detected, but its significance was felt to be uncertain. Investigations confirmed a diagnosis of systemic lupus erythematosus: ESR 35 mm/h, LE cells and antinuclear factor strongly positive, proteinuria 1 g/24 h, blood urea 6.64 mmol/l (40 mg/100 ml), creatinine clearance 110 ml/min. Renal biopsy showed a membranous glomerulonephritis and other changes compatible with lupus nephritis.

Over the next year she developed exertional dyspnoea and cardiac failure. Indices of renal function were unchanged, but the cardiac signs altered significantly; there was now a loud apical pansystolic murmur with additional

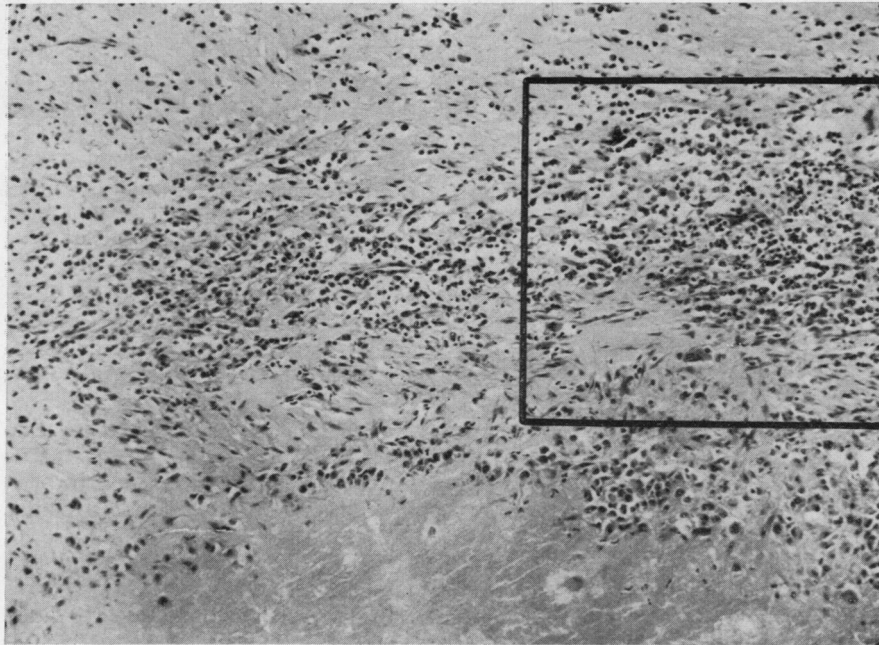
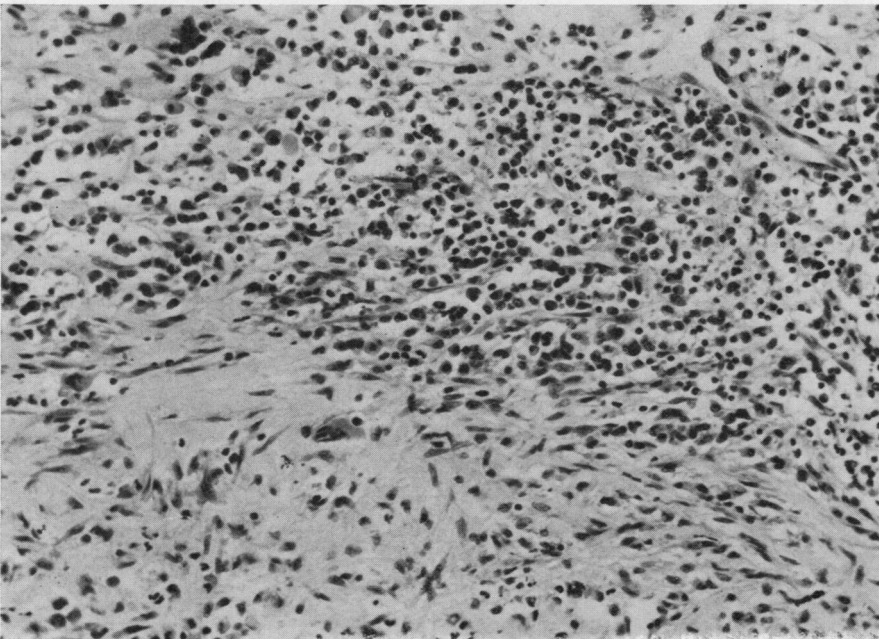


FIG. 2 Case 2. Transverse section through base of aortic valve cusp, showing fibrinoid necrosis and infiltration with mononuclear cells. (a) $\times 99$;



(b) enlargement of area outlined on (a) $\times 171$

signs of left atrial enlargement. She was otherwise well on treatment with prednisolone 10–15 mg daily and her heart failure was satisfactorily managed with diuretics for the next 4 years. At the age of 27, however, renal function rapidly deteriorated. Blood urea rose to 16.6 mmol/l (100 mg/100 ml), creatinine clearance fell to 58 ml/min, and proteinuria increased to 6.5 g/24 h. Renal function showed no improvement after a month of cyclophos-

phamide treatment which had to be stopped because of alopecia and severe depression. During the following 2 years, repeated attacks of pulmonary oedema and progressive renal failure necessitated several hospital admissions, and at the age of 29 cardiac catheterization showed severe obstruction of the mitral valve from mixed stenosis and incompetence with pulmonary hypertension. Mitral valve replacement was considered to be urgent.

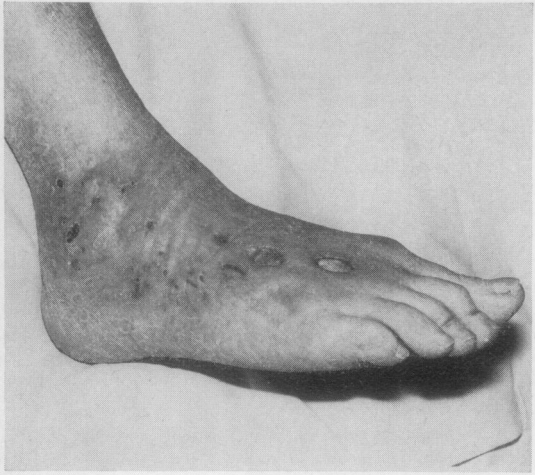

FIG. 3. *Case 2. Recrudescence of ulceration 3 weeks after operation*

At operation, a heavily calcified mitral valve (Fig. 4) was replaced by a Starr-Edwards prosthesis. The patient was on cardiopulmonary by-pass for 2 hours and the operation itself was uneventful, with adequate maintenance of blood pressure and acid-base balance at all times. Twelve hours after operation, however, the patient became anuric and showed no response to bolus injections of 1 g frusemide. Peritoneal dialysis was unsuccessful and the patient died from complications of renal failure within 48 hours of operation.

Discussion

It is unusual for cardiac valvular disease complicating the chronic inflammatory disorders of connective tissue to be sufficiently severe to require surgical intervention and at the same time to be feasible in the face of the patient's general condition. The three cases briefly described here well illustrate the crucial importance of the latter in determining prognosis.

Case 1 presented the features of aortic disease well known to accompany a minority of patients with Reiter's syndrome (Paulus, Pearson, and Pitts, 1972). Cardiac involvement became severe, necessitating valve replacement, but other features of his disease were relatively mild and his subsequent progress has been excellent.

The technical results of operation were also extremely satisfactory in Case 2, with striking improvement in cardiac function, but uncontrolled vasculitis and septicaemia led to death 9 months later.

The aetiology of the mitral valve disease in Case 3 is uncertain. The presence of calcific mitral stenosis with a definite history of rheumatic fever in childhood favours a diagnosis of chronic rheumatic mitral disease. On the other hand, the marked deterioration in cardiac symptoms and signs which accompanied the onset and progress of undoubtedly active lupus suggests that the cardiac lesion may have been at least partly the result of chronic lupus endocarditis (Brigden, Bywaters, Lessof, and Ross, 1960). In either

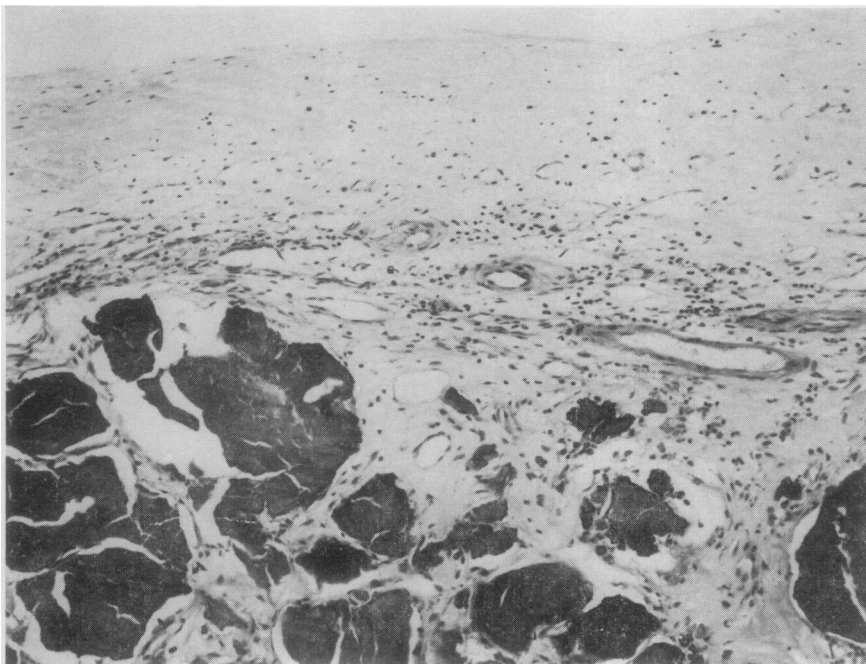


FIG. 4 *Case 3. Transverse section through mitral valve leaflet near the base. Large deposits of calcium are seen.*
×108

case, the outcome of operation was determined not by cardiac disease itself but by renal failure secondary to lupus nephritis.

There is little doubt that Cases 2 and 3 would have succumbed without surgical intervention, so that the risks of operation had to be taken. The varying outcome of these three cases do, however, emphasize the careful attention which must be paid to all

aspects of disease when assessing such patients for cardiac surgery.

The operations were carried out by Mr. Arthur Makey (Charing Cross Hospital) and Mr. Matthew Paneth (Brompton Hospital). We are grateful to our cardiological colleagues, Drs. A. M. Harris, S. H. Ikram, and P. G. F. Nixon, for their help in the investigation of these patients.

References

- BRIGDEN, W., BYWATERS, E. G., LESSOF, M. H., AND ROSS, I. P. (1960) *Brit. Heart J.*, **22**, 1 (The heart in systemic lupus erythematosus)
- IVESON, J. M. I., THADANI, U., IONESCU, M., AND WRIGHT, V. (1975) *Ann. rheum. Dis.*, **34**, 312 (Aortic valve incompetence and replacement in rheumatoid arthritis)
- PAULUS, H. E., PEARSON, C. M., AND PITTS, W. (1972) *Amer. J. Med.*, **53**, 464 (Aortic insufficiency in five patients with Reiter's syndrome: a detailed clinical and pathologic study)