



Strategies and Techniques for Liver Magnetic Resonance Imaging: New and Pending Applications for Routine Clinical Practice

Kristina I. Ringe¹, Jeong Hee Yoon²

¹Department of Diagnostic and Interventional Radiology, Hannover Medical School, Hannover, Germany

²Department of Radiology, Seoul National University Hospital, Seoul, Korea

<https://doi.org/10.3348/kjr.2022.0838>
Korean J Radiol 2023;24(3):180-189

The publisher and authors would like to draw the reader's attention to an error in the following article.

Strategies and Techniques for Liver Magnetic Resonance Imaging: New and Pending Applications for Routine Clinical Practice. Korean J Radiol 2023;24(3):180-189.

On page 186, the revised version should be as below.

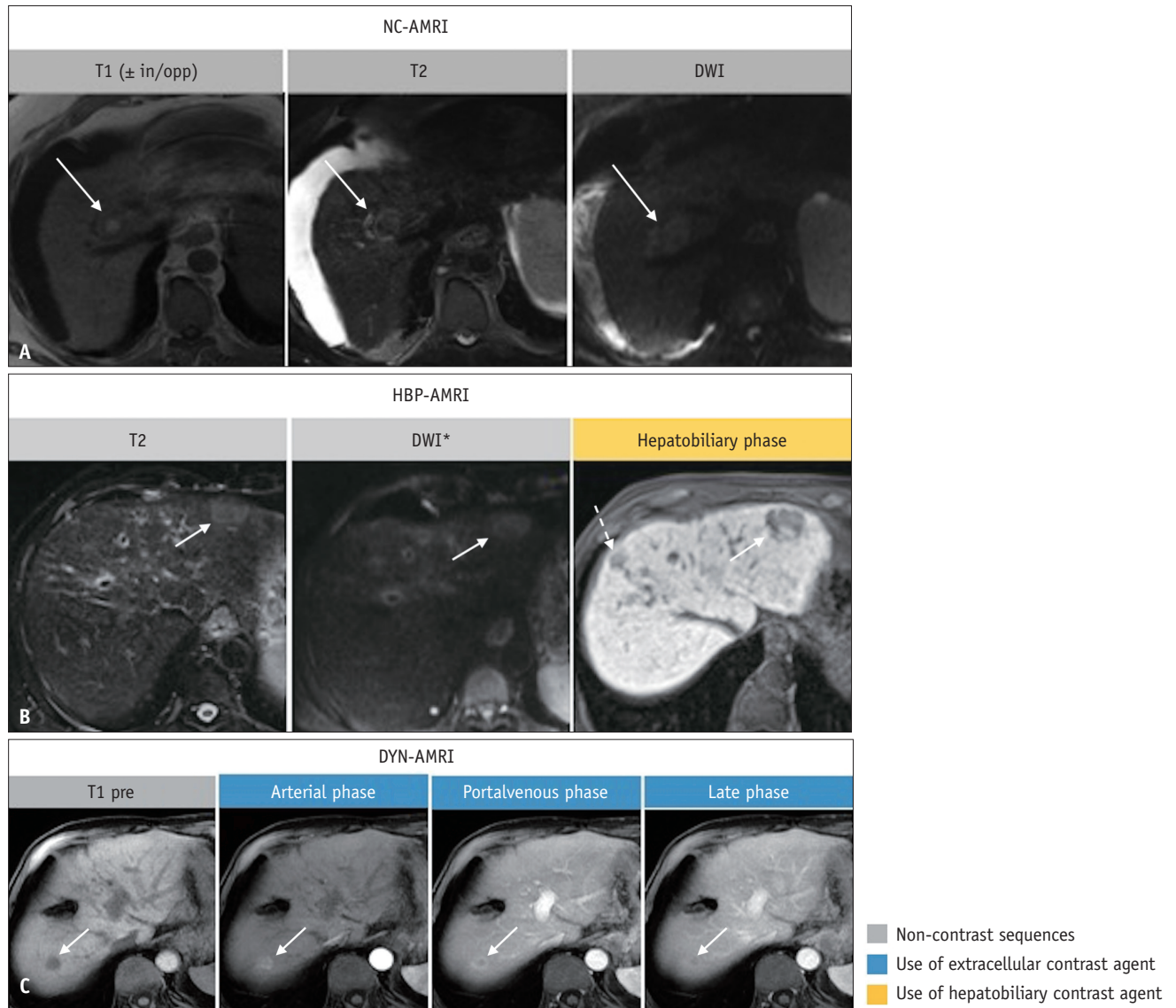


Fig. 4. Abbreviated magnetic resonance imaging (AMRI) in three different patients with hepatocellular carcinoma. Non-contrast (NC)-AMRI (**A**), hepatobiliary (HBP)-AMRI (**B**) and dynamic (DYN)-AMRI (**C**) in three different patients with hepatocellular carcinoma (arrows in **A-C**). In the hepatobiliary phase an additional lesion can be appreciated (dashed arrow in **B**). *There is no consensus on whether diffusion-weighted imaging (DWI) should be a part of this protocol or not. in/opp = in and opposed phase imaging, pre = pre-contrast