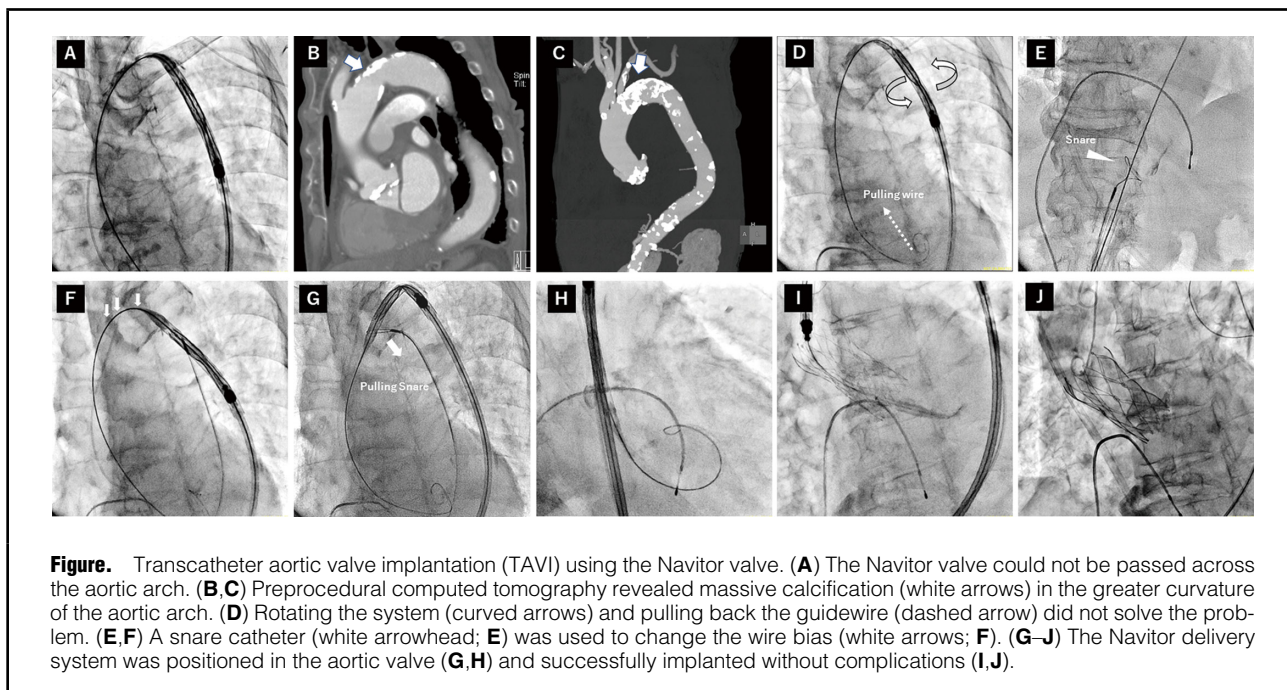


## Snare Technique Used to Pass a Navitor Transcatheter Heart Valve Through a Heavily Calcified Aortic Arch

Ryotaku Kawahata; Masanori Yamamoto, MD; Ai Kagase, MD; Takahiro Tokuda, MD



An 89-year-old man was admitted to the Nagoya Heart Center because of symptomatic severe aortic stenosis. For treatment, we decided on transfemoral transcatheter aortic valve implantation (TF-TAVI) using the Navitor valve (Abbott, St. Paul, MN, USA). However, the Navitor valve could not cross the aortic arch (Figure A). Computed tomography showed heavy deposition of calcium in the aortic arch (Figure B,C). We tried to pass the entire system by rotating the delivery system and pulling back the extra-stiff guidewire (Figure D), none of which solved the problem. Therefore, we decided to use a snare catheter (OSPIKA, Rheinfelden, Germany) to catch the proximal edge of the device (Figure E). We pulled back the snare carefully, avoiding the joint capsule part of the device, before crossing the aortic arch in the same manner as for the other self-expandable series (Figure F), resulting

in successful delivery of the device to the aortic arch (Figure G). The snare could be removed after crossing the device into aortic valve (Figure H). TF-TAVI was performed without any adverse events (Figure I,J). Although the Navitor system is designed for high deliverability via difficult access routes, physicians are aware that even this system may be challenging to deliver across an aortic arch with heavy calcium deposition. The snare technique described here is a possible solution, changing the wire bias to deliver the catheter with, for example, a Navitor valve for TF-TAVI.

### Disclosures

M.Y. has received lecture fees from Edwards, Medtronic, Boston, Abbott, and Daiichi-Sankyo. The other authors have no conflicts of interest to disclose.

Received December 21, 2022; revised manuscript received February 15, 2023; accepted February 24, 2023; J-STAGE Advance Publication released online March 25, 2023 Time for primary review: 23 days

Department of Cardiology, Nagoya Heart Center, Nagoya (R.K., M.Y., A.K., T.T.); Department of Cardiology, Toyohashi Heart Center, Toyohashi (M.Y.); and Department of Cardiology, Gifu Heart Center, Gifu (M.Y.), Japan

Mailing address: Masanori Yamamoto, MD, Department of Cardiology, Toyohashi Heart Center, 21-1 Gobutori, Oyama-cho, Toyohashi 441-8530, Japan. email: masa-nori@nms.ac.jp

All rights are reserved to the Japanese Circulation Society. For permissions, please email: cr@j-circ.or.jp  
ISSN-2434-0790

