

# Welders' pneumoconiosis: tissue elemental microanalysis by energy dispersive x ray analysis

A FUNAHASHI, D P SCHLUETER, K PINTAR, E L BEMIS,\*  
K A SIEGESMUND

*From the Departments of Medicine and Pathology of the Clement J Zablocki Veterans Administration Medical Center, Milwaukee, Wisconsin, and the Departments of Medicine, Pathology, and Anatomy of the Medical College of Wisconsin, Wisconsin, USA*

**ABSTRACT** Histological examination on lung tissue obtained from 10 symptomatic welders was performed by two certified pathologists without the knowledge of the patients' clinical condition. In all cases, there was some degree of interstitial fibrosis; in five the degree of fibrosis was considered to be moderate to pronounced. The tissue was also analysed by energy dispersive x ray analysis and elemental contents were compared with age matched controls. There was a large amount of iron in the lungs of welders but the silicon content did not differ from the control subjects. No specific foreign element was detected. It is concluded that (1) interstitial pulmonary fibrosis is seen in some welders and (2) the cause of fibrosis does not appear to be coexisting silicosis.

Since the first description by Doig in 1936, welders' pneumoconiosis has been considered to be benign.<sup>1,2</sup> Nevertheless, in several reports welders' pneumoconiosis has been associated with clinical symptoms and physiological abnormalities.<sup>3-8</sup> Since welders are often exposed to a variety of inorganic materials including silica, which is known to be highly fibrogenic to the lung, coexisting silicosis has been suggested as an aetiological factor in symptomatic welders. There are few data, however, regarding the actual dust burden in the lungs of welders. Energy dispersive x ray analysis (EDXA) is a relatively new method of elemental analysis which allows a simultaneous, multi-elemental analysis while samples are being examined by either scanning electron microscope (SEM) or scanning transmission electron microscope (STEM). We have previously used this method of analysis to study interstitial pulmonary fibrosis associated with silicosis and found it to be useful in discriminating fibrosis secondary from silicosis of other causes.<sup>9</sup> This report is based on a study of 10 welders who had respiratory symptoms and abnormal chest radiographs. Nine had open lung biopsies for diagnosis and in one case the tissue was obtained at necropsy. The tissue specimens were then processed for tissue elemental analysis by EDXA.

## Material and methods

All 10 cases had been seen at one of the metropolitan Milwaukee hospitals. Clinical records and the results of pulmonary function studies were available. In most cases the chest radiographs were available for review, in the remainder official interpretations by the radiologist were used. Forced expiratory spirometry was performed on a Stead-Wells spirometer and lung volume measurements were performed by the helium dilution method. Diffusing capacity (DLCO) was measured by a single breath holding method. Predicted values for spirometry were taken from Morris *et al.*,<sup>10</sup> lung volumes from Boren *et al.*,<sup>11</sup> and DLCO from Burrows *et al.*<sup>12</sup> The decision for biopsy was made by the attending physicians and pulmonary consultants concerned. No biopsy was performed for the purpose of this investigation.

Histological specimens were stained by haematoxylin-eosin and Prussian blue and examined independently by two certified pathologists with no prior knowledge of the clinical history. They were asked to grade the pathological findings into six categories: (1) fibrosis, (2) alveolar wall thickening, (3) cellular infiltrates, (4) iron content, (5) bronchiolar changes, and (6) vascular changes. The pathological changes were graded as absent, minimal, slight, moderate, or pronounced. The method of study by SEM and EDXA has been reported.<sup>13</sup> Briefly, paraffin embedded specimens were cut at 40  $\mu\text{m}$  thickness and

\*Dr Bemis died on 13 January 1984.

Table 1 Individual patient profiles, chest x ray abnormalities, and pulmonary function results

	Age	Sex	Occupation	Duration (years)	Symptoms	Radiograph report	Pulmonary function			
							FVC	FEV <sub>1</sub> (% predicted)	FEV <sub>1</sub> /FVC	DLCO
1	36	M	Welder	12	Cough, dyspnoea	Diffuse nodular	76	72	76	56
2	56	M	Welder	26	Dyspnoea	Diffuse nodular	67	64	71	80
3	55	M	Gas Cutter	24	Dyspnoea	Reticulonodular	58	64	79	84
4	36	M	Welder	15	Dyspnoea	Diffuse nodular	73	72	78	73
5	31	M	Gas Cutter	8	Dyspnoea	Diffuse nodular	86	93	87	93
6	47	M	Welder	23	Cough	Reticulonodular	67	68	81	72
7	60	M	Welder	40	Dyspnoea	Diffuse nodular	82	87	80	104
8	60	M	Welder	30	Cough	Diffuse nodular	91	77	64	—
9	49	M	Gas cutter	10	Dyspnoea	Diffuse nodular	87	86	78	95
10	63	M	Welder	40	Dyspnoea	Diffuse nodular	76	70	68	113

deparaffinised by passage through graded alcohols and finally floated in water. The specimens were then placed on an electromagnetically pure carbon stub and air dried. They were examined by a JSM-35C scanning electron microscope equipped with an Ortec S1 solid state detector. The analyses were performed with magnification of 100 which allowed an analysis of 1 mm in each area. A total of five area analyses was performed and the results were expressed as element/sulphur ratio, as described previously, in order to compensate for differences in tissue mass in each area of analysis.<sup>13</sup> Si/S and Fe/S ratio were then

compared with 10 age matched controls and 10 cases of well established silicosis previously studied in our laboratory. Student's *t* test was used for statistical analysis.

### Results

Table 1 shows individual patient profiles, chest radiographic abnormalities, and pulmonary function results. Age ranged from 31 to 63 (mean 49.3) and the duration of welding from eight to 40 years (mean 22.8). All were symptomatic and complained of dys-

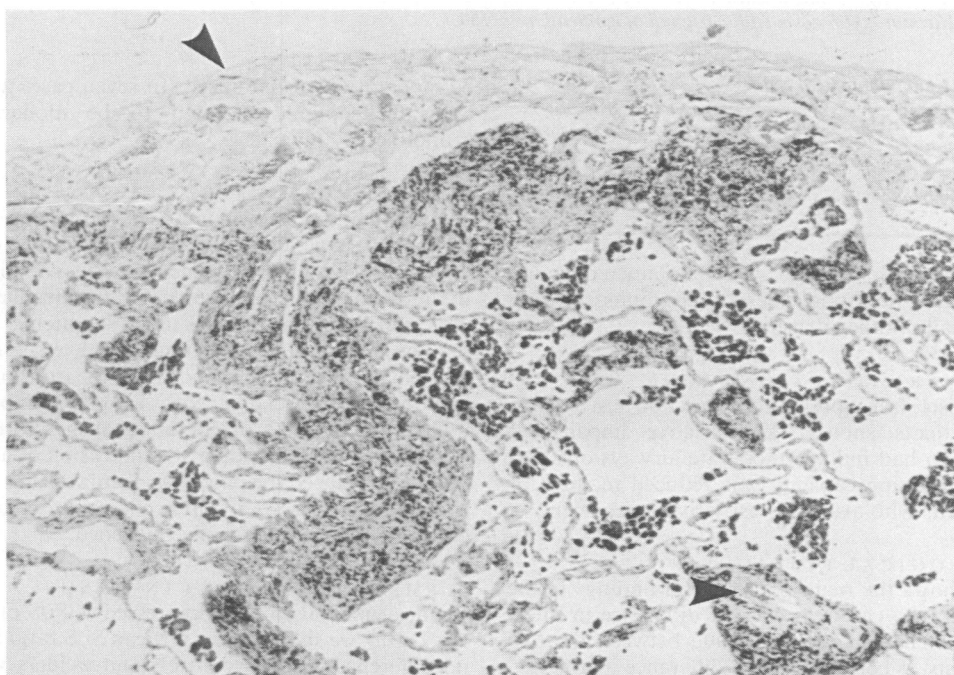

Fig 1 Lower magnification shows lung periphery with pleura. Delicate intra-alveolar septa are next to thickened septa with deposition of iron and fibroplasia. There is focal fibrosis of pleura and thickening of blood vessels (arrowheads). (Haematoxylin-eosin stain, original magnification  $\times 50$ .)

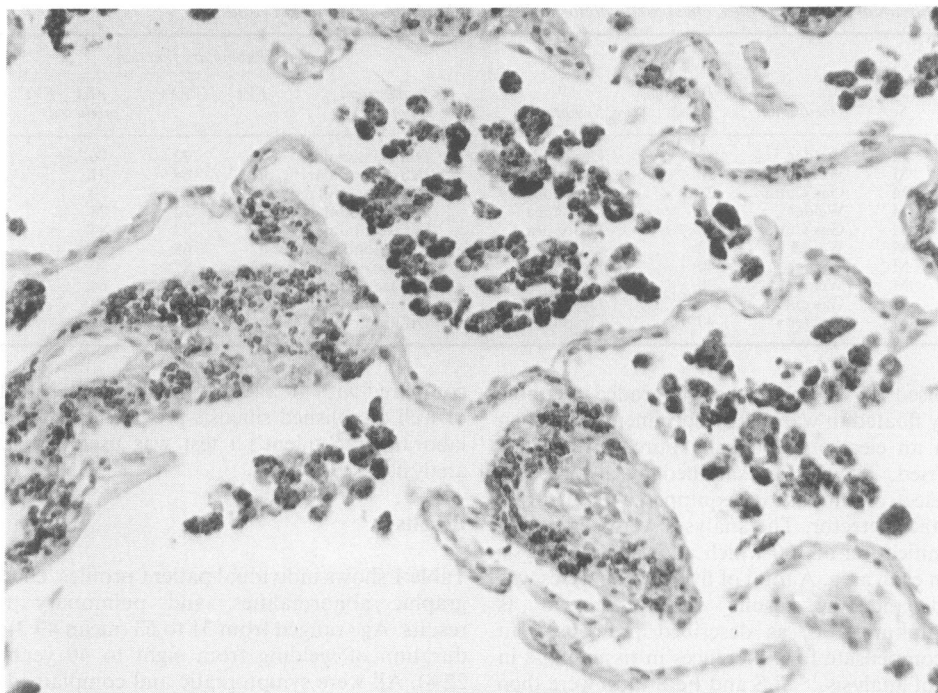


Fig 2 Higher magnification shows focal fibrosis of septa and pleura with iron deposition. (Haematoxylin-eosin stain, original magnification  $\times 160$ .)

Table 2 Main pathological changes

	Min	Slight	Mod	Pronounced
Fibrosis	2	3	4	1
Alveolar wall thickening	2	3	4	1
Iron content	0	1	4	5

pnoea, except cases 6 and 8 who complained of cough only. All had abnormal chest radiographs showing diffuse small nodular densities.

#### PULMONARY FUNCTION STUDY

Table 1 also shows pulmonary function test results. Seven patients showed a restrictive impairment whereas two had mild to moderate airways obstruction.<sup>8,10</sup> Diffusing capacity was reduced in three of nine patients who also had restrictive impairment.

#### PATHOLOGICAL FINDINGS

Table 2 shows the main pathological findings in the 10 cases. In no case was there a difference in interpretation of more than one grade between the two pathologists. When there was a difference in grading, the lower grade was used to express the degree of pathological changes. All had some degree of fibrosis. In five cases the degree of fibrosis was considered to

be moderate to pronounced. In seven cases alveolar wall thickening was noted to be moderate to pronounced.

#### ILLUSTRATIVE CASE

Figures 1 and 2 show lung tissue from one subject (case No 7) in which the degree of fibrosis was considered to be slight. The specimen showed iron pigments in the alveolar macrophages and in the alveolar septa. The iron deposition in the tissue is patchy, located mainly subpleurally and around blood vessels and the bronchial walls. The deposition of iron in these locations is associated with a mild lymphocytic infiltration and with proliferation of myofibroblasts. The resulting small nodularity and fusion of adjacent nodules produced the patchy appearance. The lumina of the affected vessels are often compromised or obliterated. The pleura is focally thickened.

#### ELEMENTAL CONTENT IN TISSUE

Tissue elemental contents expressed as Si/S ratio and Fe/S ratio are shown in fig 3. Mean Si/S ratio showed no difference between controls and welders whereas patients with silicosis had a significantly ( $p < 0.005$ ) higher ratio than controls and welders. The mean Fe/S ratio was slightly higher in patients with silicosis

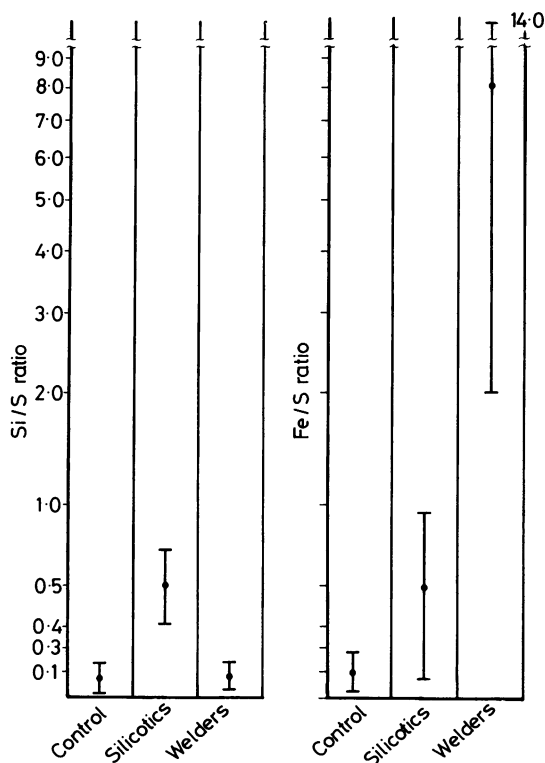


Fig 3 Silicon/sulphur ratio (Si/S) and iron/sulphur ratio (Fe/S) in three groups of subjects.

than in controls but the difference did not attain statistical significance. The Fe/S ratio is significantly higher in welders as compared with controls and patients with silicosis ( $p < 0.0025$ ). No other elements were found to be raised in the welders.

## Discussion

In 1936 Doig described abnormal chest radiographs in six of 16 welders; all six were asymptomatic.<sup>1</sup> Enzer and Sanders reported the first pathological description of welders' pneumoconiosis in a subject who had an abnormal chest radiograph and died from an accident.<sup>14</sup> They found little fibrosis despite a large accumulation of iron in the alveolar spaces. In 1948 Doig reported that the radiographic abnormalities in two of his original series of patients cleared after they were removed from exposure.<sup>15</sup> Morgan and Kerr studied seven welders with radiographic abnormalities.<sup>16</sup> Three of these seven cases had mild respiratory symptoms. Histological examination showed a large amount of iron, primarily in the alveolar space with little interstitial fibrosis. In one case there was consid-

erable fibrosis but tuberculosis was also present and he had had exposure to other dusts. Spectrographic study of the lung tissue showed an increased amount of silica along with increased iron. The cause of fibrosis was attributed to his pulmonary tuberculosis. The authors concluded that welders' siderosis is a benign condition and "those welders described in the literature, in whom obstructive airway disease and associated carbon dioxide retention was present, were most probably suffering from the effect of concomitant bronchitis and emphysema." A review of the published reports showed that many symptomatic welders indeed had obstructive ventilatory impairment on their pulmonary function studies and histological examination showed emphysematous changes.<sup>3-6</sup> In the present series all subjects had clinical symptoms of dyspnoea or cough. The most prevalent pulmonary function abnormality found was that of restrictive impairment except in subjects 8 and 10 in whom a mildly reduced FEV<sub>1</sub>/FVC ratio indicated some airways obstruction. The degree of obstruction, however, was not considered severe enough to explain their symptoms and the patients underwent open lung biopsies. Furthermore, all our subjects showed interstitial fibrosis to some degree which is not a feature of obstructive airways disease. In 1967 Meyer *et al* reported a case of pulmonary fibrosis in arc welders.<sup>7</sup> A spectrographic analysis of the lung tissue showed that silica was 30% of the total iron content. Since welding rod coating material may contain elements such as titanium, silicon, magnesium, manganese, calcium, and copper and the patient had no history of exposure to silica, the authors concluded that the fibrosis observed was due to coexisting silicosis from exposure to fumes from the electrode coating. This view was supported by Patel and Kumat who also reported a case of welders' pneumoconiosis with interstitial fibrosis.<sup>8</sup> In the present study the results of elemental analysis by EDXA showed that the silicon content of the welders' lung tissue was similar to that of controls. This finding would support the contention that coexisting silicosis due to coating material was not the cause of interstitial fibrosis. Recently, Stettler *et al* used an electron probe microanalyser together with a scanning transmission electron microscope to study the lung tissue from two welders.<sup>17</sup> The first case had minimal fibrosis but the second case had "more extensive interstitial fibrosis." They analysed particles in the lung greater than 0.2  $\mu\text{m}$  and found that most particles contained iron, chromium, manganese, or nickel and that a small percentage of these particles was classified as silicate or silica. In 1978 Guidotti *et al* also studied the lung tissue of a welder who had severe interstitial fibrosis with EDXA together with SEM.<sup>18</sup> They also used a high magnification (2000  $\times$ )

and analysed particles seen inside the individual cells and found them to contain iron and silicon. Both Stettler *et al* and Guidotti *et al* emphasised the usefulness of in situ microanalysis of small particles seen in the lung tissue.<sup>17,18</sup> We have used a similar technique to analyse black particles seen in cases of pulmonary interstitial fibrosis, and found that these particles contain chromium, iron, cobalt, and nickel.<sup>14</sup> In the present study we used a lower magnification that allowed us to cover a larger area for analysis. We believe that the higher magnifications used by Stettler *et al*, Guidotti *et al*, and in our previous study of interstitial fibrosis are useful in identifying the elemental composition of individual particle(s) of smaller size (less than 1  $\mu\text{m}$ ) but are not suitable to estimate the overall dust burden of the tissue.<sup>9</sup> Interstitial fibrosis is a reaction of lung tissue to various insults. Therefore, the interstitial fibrosis seen in our patients is possibly a mere coexistence of welders' siderosis and idiopathic pulmonary fibrosis. If, however, idiopathic pulmonary fibrosis developed in the lung with benign welders' siderosis in which iron particles are seen in the alveolar space, one would expect those particles to remain in the alveolar space. The fact that many iron containing particles are seen in the fibrosed alveolar septa would suggest that the observed fibrosis is a reaction to those particles. Further investigation is warranted in this interesting clinical entity to see if heavy metals contained in iron particles are indeed responsible for the fibrosis seen in these patients. From the clinician's standpoint, it is important to recognise that welders who have no exposure to silica or asbestos may develop interstitial fibrosis leading to respiratory symptoms and physiological abnormalities although it is uncommon. We conclude therefore that (1) welders' pneumoconiosis may be associated with interstitial fibrosis; (2) the association of welders' pneumoconiosis and interstitial fibrosis appears to be more than coincidental; and (3) the cause of interstitial fibrosis in this group of welders with pneumoconiosis did not appear to be due to associated silicosis, since silica concentrations in the lung were within normal limits.

This study was supported by a Veterans Administration research grant.

## References

- 1 Doig MB, McLaughlin ALG. X-ray appearance of the lungs of electric arc welders. *Lancet* 1936;i:771-5.
- 2 Park WR. *Occupational lung disease*. London: Butterworth, 1982:113-7.
- 3 Charr R. Respiratory disorders among welders. *JAMA* 1953;132:1520-2.
- 4 Charr R. Respiratory disorders among welders. *Am Rev Respir Dis* 1955;71:877-84.
- 5 Charr R. Pulmonary changes in welders. A report of three cases. *Ann Intern Med* 1956;44:806-12.
- 6 Friede E, Rachow DO. Symptomatic pulmonary disease in arc welders. *Ann Intern Med* 1961;54:121-7.
- 7 Meyer E, Kratzinger SF, Miller WH. Pulmonary fibrosis in arc welder. *Arch Environ Health* 1967;15:462-8.
- 8 Patel KC, Sheth SM, Kamat SR. Arc welders' lung. *J Postgrad Med* 1977;23:35-8.
- 9 Funahashi A, Schlueter DP, Pintar K, Siegesmund KA. Value of in situ elemental microanalysis in the histologic diagnosis of silicosis. *Chest* 1984;85:506-9.
- 10 Morris JF, Koski A, Johnson LV. Spirometric standard for healthy non-smoking adults. *Am Rev Respir Dis* 1971;103:57-67.
- 11 Boren HG, Kory RC, Syner JC. The Veterans Administrations-Army Cooperative study of pulmonary function II. The lung volume and its subdivision in normal man. *Am J Med* 1966;43:96-113.
- 12 Borrow B, Kask JE, Niden AH. Clinical usefulness of the single-breath pulmonary diffusing capacity test. *Am Rev Respir Dis* 1961;84:789-806.
- 13 Funahashi A, Pintar K, Siegesmund KA. Identification of foreign material in lung by energy dispersive x-ray analysis. *Arch Environ Health* 1975;30:285-9.
- 14 Enzer N, Sander OA. Chronic lung changes in electric arc welders. *Journal of Industrial Hygiene and Toxicology* 1938;20:333-50.
- 15 Doig AT, McLaughlin ALG. Clearing of x-ray shadows in welder's siderosis. *Lancet* 1948;i:789-91.
- 16 Morgan WKC, Kerr HD. Pathologic and physiologic studies of welder's siderosis. *Ann Intern Med* 1963;55:293-304.
- 17 Stettler LE, Groth DH, Mackay GR. Identification of stainless steel welding fume particulates in human lung and environmental samples using electron probe microanalysis. *Am Ind Hyg Assoc J* 1977;39:76-82.
- 18 Guidotti TL, DeNee PB, Abraham JL, Smith JR. Arc welders pneumoconiosis: application of advanced scanning electron microscopy. *Arch Environ Health* 1978;33:117-24.
- 19 Siegesmund KA, Funahashi A, Pintar K. Identification of metal in lung from a patient with interstitial pneumonia. *Arch Environ Health* 1974;28:345-9.