

# Histologic re-evaluation of a population-based series of renal cell carcinomas from The Netherlands Cohort Study according to the 2022 ISUP/WHO classification

SELENA ODEH<sup>1\*</sup>, IRYNA V. SAMARSKA<sup>1\*</sup>, ANDRES MATOSO<sup>2-4</sup>, JEROEN A.A. VAN DE POL<sup>5</sup>, MARCELLA M.L.L. BALDEWIJNS<sup>1,6</sup>, CHRISTINA A. HULSBERGEN-VAN DE KAA<sup>7,8</sup>, JALEESA VAN DER MEER<sup>1</sup>, GUIDO ROEMEN<sup>1</sup>, ERIK GEELKENS<sup>1</sup>, MANON VAN ENGELAND<sup>1</sup>, AXEL ZUR HAUSEN<sup>1</sup>, LEO J. SCHOUTEN<sup>5</sup> and KIM M. SMITS<sup>1</sup>

<sup>1</sup>Department of Pathology, School for Oncology and Reproduction (GROW), Maastricht University Medical Center, 6200 MD Maastricht, The Netherlands; Departments of <sup>2</sup>Pathology, <sup>3</sup>Urology and <sup>4</sup>Oncology, Johns Hopkins University, Baltimore, MD 21218, USA; <sup>5</sup>Department of Epidemiology, School for Oncology and Reproduction (GROW), Maastricht University Medical Center, 6200 MD Maastricht, The Netherlands; <sup>6</sup>Department of Histopathology, University of Leuven, 3000 Leuven, Belgium; <sup>7</sup>Department of Pathology, Radboud University Medical Center, 6500 HB Nijmegen; <sup>8</sup>Laboratory of Pathology East Netherlands (LABPON), 7550 AM Hengelo, The Netherlands

Received October 13, 2022; Accepted January 4, 2023

DOI: 10.3892/ol.2023.13760

**Abstract.** The aim of the present study was to re-evaluate 457 renal cell carcinoma (RCC) cases from the Netherlands Cohort Study on Diet and Cancer (NLCS), a large population-based cohort, according to the new 2022 ISUP, Genitourinary Pathology Society and World Health Organisation (WHO) classifications to assess whether newly recognized subtypes of RCC could be found among these

cases. These cases were initially evaluated according to the 2004 WHO classification, the Fuhrman grading system and the 3rd version of the Tumor-Node-Metastasis (TNM). Data on tumor size, laterality and date of diagnosis, among other clinicopathological characteristics, were obtained through record linkage with the Netherlands Cancer Registry and the Pathologisch-Anatomisch Landelijk Geautomatiseerd Archief. Digital slides from the NLCS were reviewed by two urogenital pathologists according to the new ISUP grading and the 2022 WHO classification (5th edition). Immunohistochemistry staining for carbonic anhydrase IX was performed on cases with ambiguous morphology. A total of 373 cases of clear cell RCC (ccRCC), 61 cases of papillary RCC (pRCC), 13 cases of chromophobe RCC, 3 cases of collecting duct carcinoma and 4 cases of oncocytoma were identified. The subtyping showed no discrepancy with the previous diagnoses. A comparison of the WHO/ISUP grading to the original Fuhrman grading showed a similar grading in 245 (56.5%) cases of the total ccRCC and pRCC cases. The staging according to the novel TNM classification 8th edition showed a restaging in 286 cases (65.5%). Lymphovascular (microvascular) invasion (LVI) and tumor necrosis (TN) were present in 14.4% and 33.5% of the total number of cases, respectively. Furthermore, the presence of sarcomatoid differentiation in 5.1% and rhabdoid differentiation in 4.2% of the cases was observed. In conclusion, none of the newly accepted and emerging/provisional RCC entities were identified in the NLCS cases, which could be attributed to the high mean age (71.4 years) at diagnosis of the patients included in the present study. A restaging of the NLCS cases using the TNM 8th edition and regrading using ISUP grading was performed, which showed that it is possible to report on newer features, such as sarcomatoid differentiation and LVI, even in an old sample collection.

*Correspondence to:* Dr Kim M. Smits, Department of Pathology, School for Oncology and Reproduction (GROW), Maastricht University Medical Center, P.O. Box 616, 6200 MD Maastricht, The Netherlands  
E-mail: kim.smits@maastrichtuniversity.nl

\*Contributed equally

*Abbreviations:* RCC, renal cell carcinoma; ISUP, International Society of Urological Pathologists; WHO, World Health Organization; TNM, Tumor-Node-Metastasis; TN, tumor necrosis; LVI, lymphovascular (microvascular) invasion; NLCS, Netherlands Cohort Study on Diet and Cancer; GUPS, Genitourinary Pathology Society; NCR, Netherlands Cancer Registry; PALGA, Pathologisch-Anatomisch Landelijk Geautomatiseerd Archief; ccRCC, clear cell RCC; pRCC, papillary RCC; chRCC, chromophobe RCC; FH, fumarate hydratase; FFPE, formalin-fixed-paraffin-embedded; RD, rhabdoid differentiation; CAIX, carbonic anhydrase IX; SDH, succinate dehydrogenase; UISS, University of California, Los Angeles integrated staging system

*Key words:* newly described RCC entities, LVI, necrosis, rhabdoid and sarcomatoid features, ISUP grading, TNM 8th edition

## Introduction

Renal cell carcinoma (RCC) is a heterogeneous group of types of kidney cancer that arise from renal tubular epithelial cells. These types of cancer display divergent epigenetic and genetic abnormalities and are amongst the 10 most common types of cancer worldwide (1-4). Genetic factors such as the Von Hippel-Lindau and protein polybromo-1 genes have been associated with the pathogenesis of RCC (5). Over the last two decades, the classification of RCCs have undergone major changes based on histological presentation and molecular pathology and, in 2004, the World Health Organisation (WHO) classification recognized numerous histological RCC subtypes (6,7) with distinct genetic, biological and clinical behaviors (3,8). The most frequent subtypes of all cases of RCC are clear cell RCC (ccRCC, ~75%) (3,5), papillary RCC (pRCC, ~15%) (9,10) and chromophobe RCC (chRCC, ~5%) (11).

The growing understanding of the morphology, immunohistochemistry (IHC), genomics and epidemiology of RCC has allowed for an improved insight into the tumor biology and characterization of this disease (4,12-15). Therefore, in 2013, the International Society of Urological Pathology (ISUP) Vancouver consensus proposed a new classification of renal neoplasia including newly characterized RCC subtypes and other additional emerging/provisional entities (14-17). The new classification of RCC was revised by the WHO Renal Tumor Panel in 2015, with the results published in the 4th (14) and 5th (14,15) editions of the WHO Classification of Tumors of the Urinary System and Male Genital Organs Bluebook in 2016 and 2022 respectively.

Among the newly recognized epithelial renal tumors were fumarate hydratase (FH)-deficient RCC, succinate dehydrogenase (SDH)-deficient RCC, tubulocystic RCC, acquired cystic disease-associated RCC and clear cell papillary RCC (12,15,18,19). The aforementioned entities are now considered separate entities as their morphologies, immune-profiles and molecular characteristics have been adequately recognized (4,12,19,20). Previously, some of these entities were identified as unclassified types of RCC with aggressive features in younger adults with a mean age of  $\leq 35$  years (21-23). Other tumor types have been proposed as emerging/provisional entities; however, they have not yet been recognized by the WHO as separate entities due to a lack of sufficient evidence (14,19,24). Furthermore, certain oncocytic renal tumors have been described (19), such as eosinophilic vacuolated tumor and low-grade oncocytic renal tumor. High-grade oncocytic tumor has also been proposed to represent a potentially new renal entity (19,25). These new entities show divergent prognoses, varying from indolent to aggressive renal tumors (26) with correlated treatment implications. Moreover, correct diagnosis of the hereditary forms of these tumors has implications for affected family members (27). Therefore, accurate classification is important for prognosis, therapeutic treatment and genetic counselling (28).

In addition to the newly proposed and recognized subtypes, the Vancouver consensus proposed a new ISUP grading (16,29). The ISUP grading is similar to the well-established Fuhrman grading (30), i.e., it is also a four grade system, but relies on nucleolus identification to determine WHO/ISUP grade 1-3

and the presence of polymorphic giant tumor cells, sarcomatoid or rhabdoid differentiation (RD) features for assigning grade 4 (15,18). This new grading system was recommended to replace the Fuhrman grading as it is a more reproducible system (31,32).

Tumor-Node-Metastasis (TNM) staging has been considered the gold standard when predicting the prognosis of patients with RCC and for the guidance of patient management, surveillance and treatment (33). Moreover, it is continuously revised to improve its prognostic accuracy and predictive ability, and the 8th edition (12,34) is presently used by clinicians and pathologists (12,33,34).

In addition to TNM staging (35) and Fuhrman grading (36), tumor necrosis (TN) has been considered to be a prognostic factor (37) and evidence for this has been published for ccRCC and chRCC, independent of tumor stage and grade (14,37-39). Moreover, lymphovascular (microvascular) invasion (LVI), excluding that within the perinephric or renal fat which is already described in the pT3a part of TNM staging, has been reported to correlate with survival, independent of tumor size, grade or type (40,41).

Considering these developments, the aim of the present study was to review pathological slides of kidney tumors from the Netherlands Cohort Study on Diet and Cancer (NLCS) (42-44) in order to reclassify them by morphotype, TNM stage, ISUP grade, LVI and necrosis, according to the ISUP and the 2022 WHO classification (5th edition). A further aim was to assess whether newly accepted entities could be identified in this dataset of elderly patients. To the best of our knowledge, this is the first study to report such a re-evaluation on a large, unselected population-based series of RCCs with extensive clinical data.

## Materials and methods

*Study population.* A total of 457 cases of RCC from the NLCS were reviewed. The NLCS is a prospective cohort study that has previously been described in detail (44-46). In summary, this series was initiated in September 1986 and included 120,852 men and women, aged 55-69 years at diagnosis. The collection of the samples was limited to cases diagnosed before the 31st of December 2008. Follow-up for cancer occurrence was available through computerized record linkage with the Netherlands Cancer Registry (NCR) and Pathologisch Anatomisch Landelijk Geautomatiseerd Archief (PALGA), a national database of pathology reports (47) as described previously (46). After 22.3 years of follow-up, 659 histologically confirmed RCC cases were eligible for collection of formal in-fixed-paraffin-embedded (FFPE) tumor tissue from 51 pathology laboratories throughout The Netherlands. Data on tumor characteristics, such as laterality, date of diagnosis, TNM stage, initial treatment and other clinicopathological characteristics were obtained through record linkage with the NCR (46). Pathology reports were used to record the tumor size and to verify the staging information from the cancer registry.

*Tissue collection.* FFPE tumor tissues were collected after ethical approval by the Medical Ethical Committees of Maastricht University (Maastricht, The Netherlands), PALGA

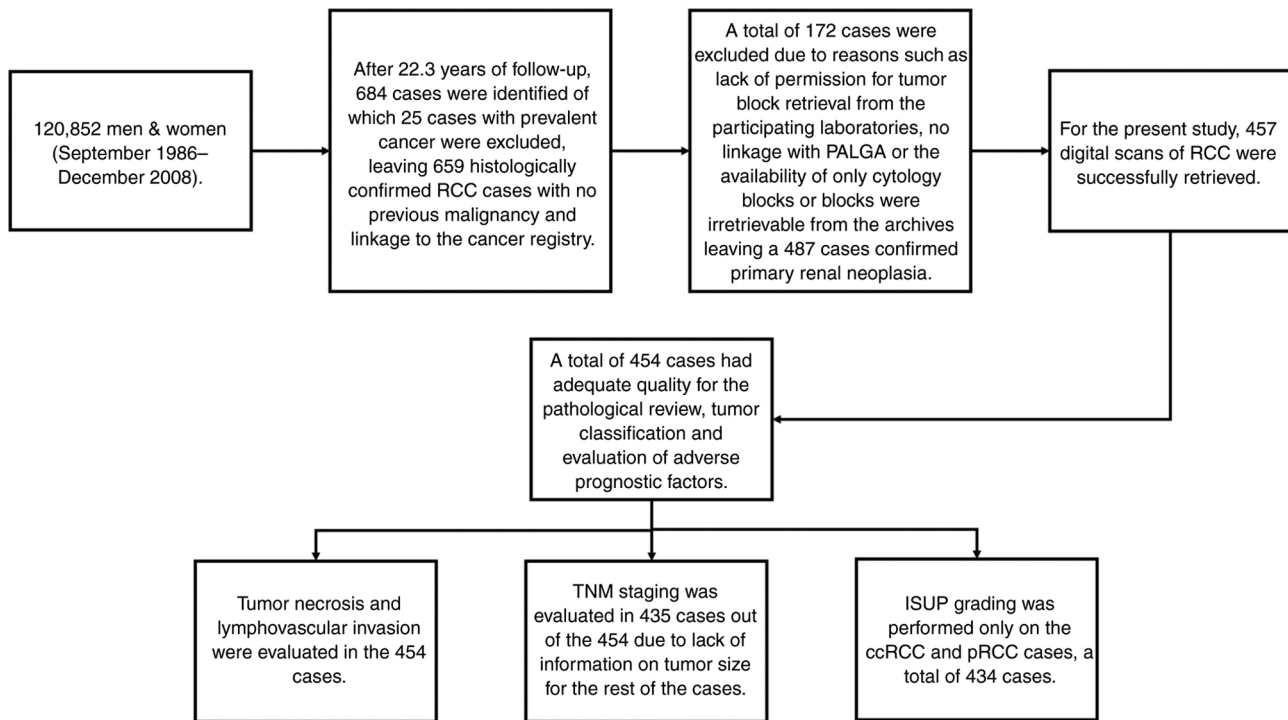


Figure 1. Flow chart showing the Netherlands Cohort Study on Diet and Cancer series from collection to the second pathology review performed in the current study. RCC, renal cell carcinoma; ISUP, International Society of Urological Pathologists; TNM, tumor-node-metastasis; ccRCC, clear cell RCC; pRCC, papillary RCC; PALGA, Pathologisch-Anatomisch Landelijk Geautomatiseerd Archief.

and the NCR. Tissue collection was performed at the time of diagnosis for the cases diagnosed between 1986–1996 and was later extended to include cases diagnosed between 1997–2008 (45,47). Urothelial cell carcinomas were excluded and only histologically confirmed epithelial cancers were included. This resulted in the collection of a total of 487 cases of confirmed primary renal neoplasia.

**Original pathology review.** The original tumor blocks were retrieved from all participating laboratories and hematoxylin and eosin (H&E) slides were made at the laboratories of Maastricht University Medical Center (Maastricht, The Netherlands) and Radboud university (Nijmegen, The Netherlands). H&E-stained slides of all collected FFPE tumor tissues were assessed by two experienced urogenital pathologists, to confirm tumor histological subtype based on the 2004 WHO classification (33). Nuclear grading was performed according to the Fuhrman grading system. After revision, cases showing <10% malignant cells or cases that were reclassified as urothelial cell carcinomas were excluded, leaving a total of 487 confirmed RCC cases.

**Second pathology review according to the new classifications of renal tumors, using the new ISUP grading and the 8th TNM edition.** For the present study, 457 digital scans of RCC cases were retrieved for inclusion in the re-evaluation which applied the new 2022 ISUP/WHO classification. Fig. 1 shows the NLCS cases from the collection to the second pathology review. These scans were originally made from the tumor slides that were selected by the pathologists as those being the most representative of the tumor subtype. The scans were made

using a Ventana iScan HT scanner (series number, BI12N7070; Roche Tissue Diagnostics), in the diagnostics facility at the Department of Pathology at the Maastricht University Medical Center, which met an internal standard quality assurance check procedure (48). If the quality of the digital slides were inadequate for the evaluation of the nucleus details, the original H&E slides were re-scanned and evaluated for a second time. Two experienced urogenital pathologists both confirmed that all digital slides included in the present study were of the quality required for the re-evaluation process.

All tumors were re-evaluated and reassigned according to histological subtype, nuclear grade, TN, sarcomatoid differentiation, RD, novel nuclear ISUP grade and LVI, using the latest TNM version and, ISUP and WHO diagnostic criteria (4,15,16,20), independently by a urogenital pathologist at Maastricht University Medical Center and an expert urogenital pathologist from the Johns Hopkins University School of Medicine (Baltimore, USA). A total of two autopsy cases were included in the pathological revision but were excluded from the TNM reclassification. Furthermore, data on tumor size were used to assign the pathological T stage according to the TNM 8th edition. Both pathologists were blinded for the outcomes of previous pathological reviews.

**IHC.** IHC staining for carbonic anhydrase IX (CAIX) was performed on ccRCC cases that warranted further subtyping confirmation. The staining was performed on RCC tissue sections (3–4  $\mu$ m) from the FFPE tissue blocks. Firstly, the slides were deparaffinized at room temperature in xylene, rinsed in a decreasing alcohol concentration series and then rinsed in water. Samples were thereafter treated at room temperature with

0.3% hydrogen peroxide in methanol for 20 min. Afterwards, the slides were washed 3x at room temperature in 1X PBS. Subsequently, the antigen retrieval pretreatment was performed using 1X citrate antigen retrieval buffer (pH 6.0, 10X diluted in water; Dako; Agilent Technologies, Inc.; cat. no. S2369) in the microwave for 20 min at 600 watt. Staining was performed on an Autostainer Plus Link 48 System (Agilent Technologies, Inc.). All steps were performed at room temperature. Samples were covered with Endogenous Peroxidase Blocking Reagent (Agilent Technologies, Inc.) for 5 min and then washed with 1X PBS. The slides were then incubated for 20 min with rabbit anti-CAIX primary antibody (1:1,000; cat. no. NB100-417; Novus Biologicals, LCC) diluted in Agilent antibody diluent (cat. no. K8006; Agilent Technologies, Inc.). Secondary detection and visualization were performed using the EnVision FLEX+ detection system (cat. no. K8002; Agilent Technologies, Inc.). In brief, slides were incubated for 20 min with labelled polymer (EnVision FLEX-HRP; Agilent Technologies, Inc.) and then the slides were incubated for 10 min with substrate buffer and DAB chromogen solution. Counterstaining with hematoxylin for 90 sec at room temperature, subsequent dehydration in an increasing alcohol series and cover slips were added using a Leica Histocore (Leica Microsystems, Inc.). Slides were evaluated by a urogenital pathologist (IS) using a light microscope.

*Statistical analysis.* In the present study, the  $\chi^2$  test was performed using SPSS 28 (IBM Corp.).

## Results

*Patient characteristics.* A total of 457 patients were included in the present study. There was a predominance of male patients (62.6%). The age at diagnosis of the included patients ranged from 56-88 years with a mean age of 71.4±6.3 years. The mean tumor size was 67.2±31.7 mm (Table I).

*Pathological review and classification of the tumors.* A total of three scans from the 457 cases were excluded due to poor quality and digital scans of the representative sections for 454 cases were available for revision. These scans were independently reviewed and classified based on morphological criteria by two pathologists based on the 2022 WHO classification, the ISUP recommendations and the Genitourinary Pathology Society (GUPS) update on renal neoplasia. The subtyping showed a 100% overlap with the previous diagnoses. The renal cell neoplasia included 373 ccRCC cases (82.1%), 61 pRCC cases (13.4%), 13 chRCC cases (2.9%), 3 cases of collecting duct carcinoma (0.7%) and 4 cases of oncocytoma (0.9%) (Table II). In 30 ccRCC cases, the diagnosis was confirmed by IHC staining for CAIX, which showed a box-like staining pattern (Fig. 2). Furthermore, none of the tumors demonstrated features compatible with FH-deficient RCC, SDH-deficient RCC, eosinophilic solid and cystic RCC or other recently described entities (12).

*Tumor grade according to the new ISUP grading system and reporting on sarcomatoid and rhabdoid features.* Initially, all 434 ccRCC and pRCC cases were graded according to the Fuhrman grading system by two pathologists (Tables I and III). Tumors were assigned grade 1 in 54 cases (12.4%), grade 2 in

Table I. Clinical characteristics of patients included in the present study.

Clinical characteristic	Number
Number of patients, n	457
Mean age at diagnosis (range), years	71.4 (56-88)
Sex, n (%)	
Male	286 (62.6)
Female	171 (37.4)
Mean tumor size ± SD, mm	67.2±31.7
Original histological review, n (%)	
Clear cell	375 (82.1)
Papillary	62 (13.6)
Chromophobe	13 (2.8)
Collecting duct carcinoma	3 (0.7)
Oncocytoma	4 (0.9)
Pathological T stage <sup>a</sup> , n, (%)	435 (95.2)
1	22 (5.1)
1a	1 (0.2)
1b	3 (0.7)
2	262 (60.2)
3	1 (0.2)
3a	73 (16.8)
3b	69 (15.9)
4	4 (0.9)
Fuhrman grade <sup>b</sup> , n (%)	434 (95.0)
1	54 (12.4)
2	196 (45.2)
3	143 (32.9)
4	41 (9.4)

<sup>a</sup>Clinical data on tumor size was available for 435 cases, <sup>b</sup>Fuhrman grading was performed on clear cell and papillary cases only. T stage, tumor stage.

196 cases (45.2%), grade 3 in 143 cases (32.9%) and grade 4 in 41 cases (9.4%). All ccRCC and pRCC cases were regraded using the new WHO/ISUP grade by two pathologists blinded to the original Fuhrman grading (Tables II and III). This resulted in the assignment of ISUP grade 1 in 93 cases (21.4%), grade 2 in 191 cases (44.0%), grade 3 in 108 cases (24.9%) and grade 4 in 42 cases (9.7%). Comparison of the two grading systems showed the same tumor grade in 245 cases (56.5%), whereas a different grade was reported in 189 cases (43.5%) (Table III). Of the 454 cases histologically reviewed, sarcomatoid differentiation was identified in 23 patients (5.1%) and RD in 19 (4.2%).

*Adverse prognostic factors.* TN and LVI were also assessed and evaluated in the 454 cases. TN was identified in 152 cases (33.5%) and, tumor necrosis (TN) was evaluated as the percentage of tumor necrosis in relation to the total tumor volume as previously described (49,50). A total of 35 tumors (23.0% of the 152 cases) exhibited a TN of ≤5%, 84 tumors (55.3% of the 152 cases) showed 6-49% TN, 29 tumors (19.1% of the 152 cases) showed 50-89% TN, and 4 tumors (2.6% of

Table II. Clinical characteristic results of the re-evaluation of the histology of a population-based series of RCC cases from the NLCS 1986-2008, according to the 2022 ISUP grading systems and WHO classification.

Clinical characteristic	Number (%)
Histological review <sup>a</sup> , n (%)	454 (99.3)
Clear cell	373 (82.2)
Papillary	61 (13.4)
Chromophobe	13 (2.9)
Collecting duct carcinoma	3 (0.7)
Oncocytoma	4 (0.9)
Pathologic T stage <sup>b</sup> , n (%)	435 (95.8)
1a	94 (21.6)
1b	115 (26.4)
2	4 (0.9)
2a	50 (11.5)
2b	25 (5.7)
3	1 (0.2)
3a	73 (16.8)
3b	69 (15.9)
4	4 (0.9)
Sarcomatoid differentiation, n/total (%)	23/454 (5.1)
Rhabdoid differentiation, n/total (%)	19/454 (4.2)
Lymphovascular invasion, n/total (%)	64/454 (14.1)
Necrosis present, n (%)	152/454 (33.5)
Necrosis present per morphotype, n necrosis present/n total cases of the morphotype (%)	
ccRCC, n (%)	111/373 (29.8)
pRCC, n (%)	38/61 (62.3)
chRCC, n (%)	2/13 (15.4)
CDC, n (%)	1/3 (33.3)
Oncocytoma, n (%)	0/4 (0.0)
ISUP grade for ccRCC and PRCC <sup>c</sup> , n (%)	434 (95.6)
1	93 (21.4)
2	191 (44.0)
3	108 (24.9)
4	42 (9.7)

<sup>a</sup>3 scans excluded due to poor quality, <sup>b</sup>tumor size available for 435 cases. Cases noted as Tumor-Node-Metastasis 2 or 3 which were not further specified as 2a, 2b, 3a or 3b, lacked the needed information on tumor size and therefore the original staging information from the cancer registry was used. <sup>c</sup>ISUP was performed on ccRCC and pRCC cases only. ccRCC, clear cell renal cell carcinoma; CDC, collecting duct carcinoma; ISUP, International Society of Urological Pathologists; NLCS, Netherlands Cohort Study on Diet and Cancer; pRCC, papillary RCC; T stage, tumor stage; WHO, World Health Organization.

the 152 cases) showed  $\geq 90\%$  TN. TN was present more often in pRCC (38/61, 62.3%) compared with ccRCC (111/372, 29.8%) ( $\chi^2$  24.46,  $P < 0.05$ ).

Table III. Comparison of nuclear grading classification according to the Fuhrman and ISUP grading systems on the Netherlands Cohort Study on Diet and Cancer, 1986-2008.

Grading system Fuhrman, n	ISUP, n				Total, n
	1	2	3	4	
1	34	17	3	0	54
2	58	111	26	1	196
3	1	61	70	11	143
4	0	2	9	30	41
Total, n	93	191	108	42	434

ISUP, International Society of Urological Pathologists.

LVI was identified in 64 renal neoplasms (14.1%). Invasion in the renal vein or its segmental branches was classified as a pT3a tumor (Table I). LVI was seen more often in ISUP grade 3 tumors (27/64 cases, 42.2%), followed by ISUP grade 2 (19/64 cases, 29.7%) and ISUP grade 4 (13/64 cases, 20.3%). Notably, LVI was seen in 5 cases of ISUP grade 1 ccRCC.

*TNM staging according to the 8th edition.* A total of 435 RCC cases were restaged according to the 8th edition of the TNM version as shown in Table II as information on tumor size was only available for 435 cases. This restaging resulted in the assignment of pT1a in 94 cases (21.6%), pT1b in 115 cases (26.4%), pT2 in 4 cases (0.9%), pT2a in 50 cases (11.5%), pT2b in 25 cases (5.7%), pT3 in 1 case (0.2%), pT3a in 73 cases (16.8%), pT3b in 69 cases (15.9%) and pT4 in 4 cases (0.9%). Comparison of the 8th edition of the TNM staging with the 3rd edition of the TNM staging that was originally applied to the NLCS cases showed a restaging in 65.5% of the cases. Table IV presented the comparison of the 3rd and the 8th edition of the TNM classification of the NLCS cases. The restaging in the present study showed that more cases were categorized in a lower TNM stage compared to the original classification, as 60.2% of the cases were originally assigned as pT2.

## Discussion

In the present study, the aim was to review RCC cases from the large, prospective NLCS cohort according to the latest 2022 WHO classification and the latest updates of GUPS and ISUP on renal tumors, to evaluate the presence of newly recognized or emerging/provisional entities. Furthermore, an evaluation of whether recently accepted renal tumor subtypes can be identified in an existing cohort of patients with RCC was performed. Moreover, the present study also aimed to classify these cases according to the new ISUP grading, to assess TN, LVI and the presence of sarcomatoid differentiation and RD features, and to apply the latest TNM edition. None of the reviewed cases showed any of the newly described entities and all the cases showed the formerly well-recognized and most common RCC subtypes. The re-evaluation of the subtyping was completely in accordance with the previous diagnoses of these RCC cases.

Table IV. Comparison of the 3rd and 8th edition of the TNM classification on the Netherlands Cohort Study on Diet and Cancer, 1986-2008.

TNM edition TNM 3rd, n	TNM 8th, n									Total, n
	1a	1b	2	2a	2b	3	3a	3b	4	
1	22	0	0	0	0	0	0	0	0	22
1a	1	0	0	0	0	0	0	0	0	1
1b	1	1	0	0	1	0	0	0	0	3
2	70	114	4	50	24	0	0	0	0	262
3	0	0	0	0	0	1	0	0	0	1
3a	0	0	0	0	0	0	73	0	0	73
3b	0	0	0	0	0	0	0	69	0	69
4	0	0	0	0	0	0	0	0	4	4
Total, n	94	115	4	50	25	1	73	69	4	435

TNM, Tumor-Node-Metastasis.

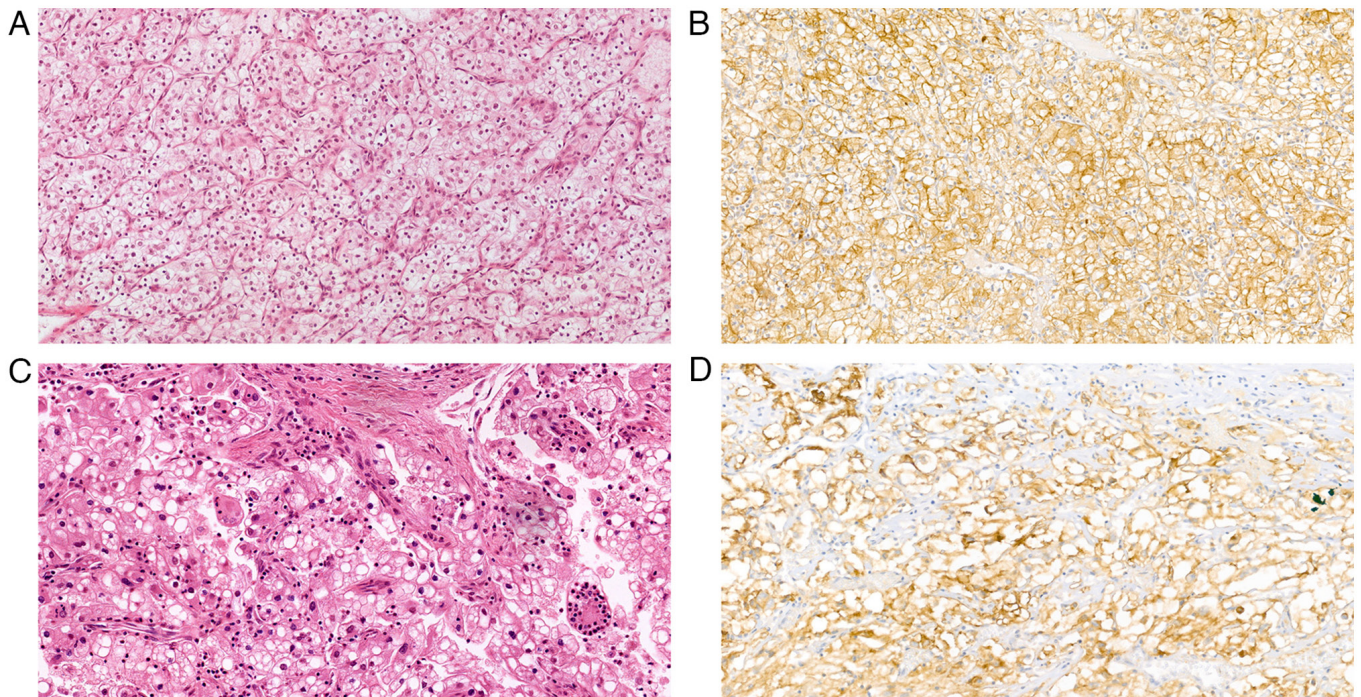


Figure 2. Histopathological images of representative cases of ccRCC. (A) A typical case of ccRCC with architectural features and clear cell morphology (H&E staining; magnification, x20). (B) IHC staining for CAIX showing a strong diffuse classical 'box-shape' staining pattern of ccRCC (magnification, x10). (C) A case of ccRCC with giant multinucleated cells (H&E staining; magnification, x20). (D) IHC staining with CAIX showing strong diffuse staining, confirming the diagnostics of ccRCC (magnification, x20). CAIX, carbonic anhydrase IX; ccRCC, clear cell renal cell carcinoma; H&E, hematoxylin and eosin; IHC, immunohistochemistry.

Comparison of the ISUP and Fuhrman gradings on the ccRCC and pRCC cases showed a different grading in 43.5% of the cases. Evaluation of the presence of sarcomatoid differentiation and RD features revealed their presence in the NLCS cases. Furthermore, assessment of the presence of adverse prognostic features showed that TN was also present in 33.5% of the cases and that it was present more often in pRCC cases (62.3%) compared with other subtypes. Hemorrhage and necrosis, however, are known to be related to the pRCC subtype but not to prognosis, and therefore are not used as

adverse prognostic indicators in pRCC. Furthermore, LVI was similarly identified in few cases and was mostly detected in tumors with ISUP grade 3. Comparison of the TNM 8th edition and the previously applied TNM 3rd edition revealed a restaging in the majority of cases. However, this difference, as well as the difference seen between the Fuhrman and the ISUP grading, were to be expected as in both situations different grading criteria were applied.

In the present study, none of the newly described or emerging entities were identified. This could be explained

by the fact that the NLCS cohort included patients with a mean age of 71.4 years and some of the newly described entities, such as the SDH-deficient RCC subtype, have been reported to be particularly seen in younger adults (12). Thus, Kwon *et al* (51) reported a reclassification of a proportion (13%) of adults with unclassified RCC in a patient cohort with a mean age at presentation of 58 years old. Clemmensen *et al* (52) reclassified a subset of early onset RCC in patients aged <46 years. Li *et al* (23) re-evaluated oncocytic renal tumors in patients aged  $\leq 35$  years. These findings suggested a low chance of finding a newly described entity in the research databases and diagnostic archives consisting of an elderly patient cohort.

However, in the present study there were 30 cases with a differential diagnosis between ccRCC and the translocation-related RCC (such as Xp11 translocation RCC), based on the morphological images. Therefore, an additional test was necessary to confirm the diagnoses of these cases. According to the literature (53) and the widely used WHO 2022 diagnostic criteria, IHC CAIX staining is a specific and sensitive marker of ccRCC, since ccRCC has a 'box-shape' staining pattern and translocation-related RCC has a negative staining result. All tested cases showed a strong membranous 'box-shaped' expression of CAIX. Therefore, CAIX was used in the present study to confirm the diagnosis of ccRCC. It can therefore be postulated that using a limited IHC panel can also be sufficient to confirm the diagnosis, especially when reviewing a large cohort database that is used for multiple research purposes and where limited tissue availability can be a limitation.

The differences in grading that were seen for the originally applied Fuhrman grading on the NLCS cases and the recently applied ISUP can be explained by the differences between these two grading systems. Despite the fact that Fuhrman grading was accepted worldwide and has been employed for many years, several studies have reported its pitfalls, including questionable prognostic value and suboptimal interobserver reproducibility (24,31,54). This is due to the fact that Fuhrman grading relies on the simultaneous assessment of nuclear size, nuclear shape and nucleolar prominence and there is no further direction on how this should be handled when these three parameters provide conflicting information (29). In contrast, the ISUP grading system relies only on the size of the nucleolus for grading tumors 1-3 and on the presence of giant cells or, the presence of sarcomatoid differentiation or RD features for assigning grade 4 (18,29). Previously, several studies compared Fuhrman grading with WHO/ISUP grading (55,56). In these studies, the WHO/ISUP grading was shown to provide superior prognostic information compared to Fuhrman grading (55,56). Therefore, the regrading of the kidney tumors in the research databases could be a reasonable procedure.

Additionally, reporting on adverse prognostic factors such as TN and LVI was also proposed in the ISUP consensus. TN has been reported to have prognostic significance for ccRCC and chRCC, independent of tumor stage and grade (50,57). However, pRCC tumors often contain areas of necrosis, the presence of which in this tumor type lacks the same significance (12). TN may also influence treatment efficacy as, for example, the response to VEGF/tyrosine kinase inhibitor-targeted therapy has been shown to be poor in patients with metastatic disease where there was  $\geq 10\%$  necrosis in

the primary ccRCC tumor (58). Therefore, assessment of the extent of tumor necrosis is recommended for reporting of kidney specimens by the International Collaboration on Cancer Reporting (59). LVI, either intratumoral, peritumoral or perirenal, has been reported to relate to metastasis rate and patient disease free survival, independent of tumor size, primary tumor category and grade (59). However, despite the fact that macroscopic tumor invasion into the renal and caval vein has been incorporated into the well-known American Joint Committee on Cancer and University of California, Los Angeles integrated staging system (UISS) (14), the predictive ability of LVI is debatable (40). This is due to the fact that certain studies have reported LVI as having been correlated with prognosis whereas others reported no association with prognosis (60-64).

The NLCS cases in the present study were originally evaluated using the TNM version that was applicable at the time of diagnosis, but all the cases were later converted to the 1987 3rd TNM version (65). However, there are significant differences between the 1987 TNM version and the currently used 8th edition, as the new TNM version has proven to be more concise and reproducible than all the previously published versions. The restaging performed in the present study showed that more cases were categorized to a lower TNM stage compared to the original classification. For example, 60.2% of cases were previously assigned pT2 while with restaging, only 11.6% of cases were assigned to pT2a and 5.8% to pT2b. Furthermore, a higher percentage in the pT1a and pT1b stages was seen, which were 21.6 and 26.4%, respectively, compared to the previously assigned staging (6% according to the TNM 3rd version). This could be explained by the major differences between the TNM classifications, namely the boundary values for assigning pT1a, pT1b, pT2a and pT2b. In the TNM 8th edition, T1a is assigned to tumors that are confined to the kidney and are <4 cm, and pT1b is assigned to tumors that are also confined to the kidney but are 4-7 cm. Furthermore, T2a is assigned to tumors that are limited to the kidney and are 7-10 cm and T2b is assigned to the tumors that are >10 cm but confined to the kidney; however, in the TNM 3rd edition, pT1 tumor was defined as <2 cm.

In the present study, despite the unique characteristics of the large population-based series with extensive clinical characteristics, there were certain limitations. Specifically, the age of the patients included in the analysis, including patients aged  $\geq 55$  years at baseline (46), hindered the possibility of reporting on some of the new entities that are mostly identified in younger patients. Another limitation was the lack of tumor size information for 5 cases, which impeded the conversion to the latest TNM version. This was hampered by the lack of access to the original clinical files and a reliance on the information obtained from the NCR and pathology reports. Furthermore, assessment was performed on the TN of representative digital slides and these slides were originally chosen by the pathologists as the ones being most representative of the tumor subtype and not necrosis. However, these scans should have been a reliable representation of tumor necrosis since a range of necrosis was observed in the cohort. If only viable tumor sections had been selected as representative slides, there would be fewer cases with tumor necrosis. Only one IHC marker, CAIX, was used to confirm the diagnosis of ccRCC in 30 cases, which was considered sufficient due to its specificity

and sensitivity (53). Furthermore, in large research cohorts, the application of extensive tests must be carefully considered when it comes to the use of tissues with limited availability and costs. Molecular testing was not performed on the revised slides as no recently described entities were identified based on the re-evaluation by two urogenital pathologists. Molecular studies are also mostly indicated when IHC is not conclusive and molecular studies are not routinely used.

In conclusion, to the best of our knowledge, the present study is the first to re-evaluate renal neoplasms from a large population-based prospective cohort that is extensively used for research purposes. The findings emphasize that the newly described entities are a minor component of the cases when analyzing a cohort of patients with a high average age. Moreover, the evaluation of additional prognostic factors in this existing cohort, such as ISUP, TNM 8th edition and rhabdoid/sarcomatoid features, allows for the updating of previously published prognostic models and comparison of these to other current prognostic models, such as the UISS and the Stage, Size, Grade and Necrosis system.

### Acknowledgements

Not applicable.

### Funding

This work was supported by the PPP Allowance made available by Health Holland, Top Sector Life Sciences and Health, to stimulate public-private partnerships [grant no. LSHM17059 (Prognosis Renal Cancer and Detection, PRECEDE)].

### Availability of data and materials

The datasets used and/or analyzed during the current are available from the corresponding author on reasonable request.

### Authors' contributions

SO, IVS, LJS and KMS were responsible for the conception and design of the study and the acquisition of data. SO, IVS, AM, LJS and KMS were responsible for the analysis and interpretation of data. SO, IVS, LJS and KMS were responsible for drafting the manuscript and revising it critically for important intellectual content. JAAVDP, JVDM, GR, EG, MVE and AZH were responsible for the acquisition, analysis and interpretation of data, and drafting and critically revising the manuscript. MMLLB and CAHVDK were responsible for the conception and design of the study, drafting the manuscript and revising it critically for important intellectual content. All authors read and approved the final version of the manuscript. SO, IVS, LJS and KMS confirm the authenticity of all the raw data.

### Ethics approval and consent to participate

This study was approved by the Medical Ethical Committee of the Maastricht University (Maastricht, The Netherlands; approval nos. MEC 00-086.2 and MEC 85-012-8).

### Patient consent for publication

Not applicable.

### Competing interests

The authors declare that they have no competing interests.

### References

1. John N, Eble GS, Jonathan I, Epstein Isabell A and Sesterhenn: World health organization classification of tumors: Pathology and genetics of tumors of the urinary system and male genital organs. IARC Press, Lyon, 2004.
2. Hsieh JJ, Purdue MP, Signoretti S, Swanton C, Albiges L, Schmidinger M, Heng DY, Larkin J and Ficarra V: Renal cell carcinoma. *Nat Rev Dis Primers* 3: 17009, 2017.
3. Cairns P: Renal cell carcinoma. *Cancer Biomark* 9: 461-473, 2010.
4. Inamura K: Renal cell tumors: Understanding their molecular pathological epidemiology and the 2016 WHO classification. *Int J Mol Sci* 18: 2195, 2017.
5. Nabi S, Kessler ER, Bernard B, Flaig TW and Lam ET: Renal cell carcinoma: A review of biology and pathophysiology. *F1000Res* 7: 307, 2018.
6. Lopez-Beltran A, Scarpelli M, Montironi R and Kirkali Z: 2004 WHO classification of the renal tumors of the adults. *Eur Urol* 49: 798-805, 2006.
7. Prasad SR, Humphrey PA, Catena JR, Narra VR, Srigley JR, Cortez AD, Dalrymple NC and Chintapalli KN: Common and uncommon histologic subtypes of renal cell carcinoma: Imaging spectrum with pathologic correlation. *Radiographics* 26: 1795-1810, 2006.
8. Yap NY, Rajandram R, Ng KL, Pailoor J, Fadzli A and Gobe GC: Genetic and chromosomal aberrations and their clinical significance in renal neoplasms. *Biomed Res Int* 2015: 476508, 2015.
9. Cancer Genome Atlas Research Network, Linehan WM, Spellman PT, Ricketts CJ, Creighton CJ, Fei SS, Davis C, Wheeler DA, Murray BA, Schmidt L, *et al*: Comprehensive molecular characterization of papillary renal-cell carcinoma. *N Engl J Med* 374: 135-145, 2016.
10. Rhoades Smith KE and Bilen MA: A review of papillary renal cell carcinoma and MET inhibitors. *Kidney Cancer* 3: 151-161, 2019.
11. Vera-Badillo FE, Conde E and Duran I: Chromophobe renal cell carcinoma: A review of an uncommon entity. *Int J Urol* 19: 894-900, 2012.
12. Warren AY and Harrison D: WHO/ISUP classification, grading and pathological staging of renal cell carcinoma: Standards and controversies. *World J Urol* 36: 1913-1926, 2018.
13. Frew IJ and Moch H: A clearer view of the molecular complexity of clear cell renal cell carcinoma. *Annu Rev Pathol* 10: 263-289, 2015.
14. Moch H, Cubilla AL, Humphrey PA, Reuter VE and Ulbright TM: The 2016 WHO classification of tumours of the urinary system and male genital organs-part A: Renal, penile, and testicular tumours. *Eur Urol* 70: 93-105, 2016.
15. WHO Classification of Tumours Editorial Board. Urinary and male genital tumours, WHO Classification of Tumours. 5th edition. Vol. 8. World Health Organization, 2022.
16. Delahunt B, Srigley JR, Montironi R and Egevad L: Advances in renal neoplasia: Recommendations from the 2012 international society of urological pathology consensus conference. *Urology* 83: 969-974, 2014.
17. Srigley JR, Delahunt B, Eble JN, Egevad L, Epstein JI, Grignon D, Hes O, Moch H, Montironi R, Tickoo SK, *et al*: The international society of urological pathology (ISUP) vancouver classification of renal neoplasia. *Am J Surg Pathol* 37: 1469-1489, 2013.
18. Moch H: The WHO/ISUP grading system for renal carcinoma. *Pathologie* 37: 355-360, 2016.
19. Trpkov K and Hes O: New and emerging renal entities: A perspective post-WHO 2016 classification. *Histopathology* 74: 31-59, 2019.
20. Delahunt B, Chevillat JC, Martignoni G, Humphrey PA, Magi-Galluzzi C, McKenney J, Egevad L, Algaba F, Moch H, Grignon DJ, *et al*: The international society of urological pathology (ISUP) grading system for renal cell carcinoma and other prognostic parameters. *Am J Surg Pathol* 37: 1490-1504, 2013.



21. Chen YB, Xu J, Skanderup AJ, Dong Y, Brannon AR, Wang L, Won HH, Wang PI, Nanjangud GJ, Jungbluth AA, *et al*: Molecular analysis of aggressive renal cell carcinoma with unclassified histology reveals distinct subsets. *Nat Commun* 7: 13131, 2016.
22. Trpkov K, Williamson SR, Gill AJ, Adeniran AJ, Agaimy A, Alaghebandan R, Amin MB, Argani P, Chen YB, Cheng L, *et al*: Novel, emerging and provisional renal entities: The genitourinary pathology society (GUPS) update on renal neoplasia. *Mod Pathol* 34: 1167-1184, 2021.
23. Li Y, Reuter VE, Matoso A, Netto GJ, Epstein JI and Argani P: Re-evaluation of 33 'unclassified' eosinophilic renal cell carcinomas in young patients. *Histopathology* 72: 588-600, 2018.
24. Eble JN and Delahunt B: Emerging entities in renal cell neoplasia: Thyroid-like follicular renal cell carcinoma and multifocal oncocytoma-like tumours associated with oncocytosis. *Pathology* 50: 24-36, 2018.
25. Williamson SR, Kum JB, Goheen MP, Cheng L, Grignon DJ and Idrees MT: Clear cell renal cell carcinoma with a syncytial-type multinucleated giant tumor cell component: Implications for differential diagnosis. *Hum Pathol* 45: 735-744, 2014.
26. Robila V, Kraft AO and Smith SC: New entities, new technologies, new findings: A review of the cytologic features of recently established subtypes of renal cell carcinoma. *Cancer Cytopathol* 127: 79-97, 2019.
27. Stratton KL, Alanee S, Glogowski EA, Schrader KA, Rau-Murthy R, Klein R, Russo P, Coleman J and Offit K: Outcome of genetic evaluation of patients with kidney cancer referred for suspected hereditary cancer syndromes. *Urol Oncol* 34: 238.e1-e7, 2016.
28. Yunker A, Holder L and Nething J: Newly described eosinophilic, solid and cystic renal cell carcinoma: A case report and review of the literature. *Arch Nephrol Urol* 3: 38-45, 2020.
29. Samaratunga H, Gianduzzo T and Delahunt B: The ISUP system of staging, grading and classification of renal cell neoplasia. *J Kidney Cancer VHL* 1: 26-39, 2014.
30. Fuhrman SA, Lasky LC and Limas C: Prognostic significance of morphologic parameters in renal cell carcinoma. *Am J Surg Pathol* 6: 655-663, 1982.
31. Delahunt B: Advances and controversies in grading and staging of renal cell carcinoma. *Mod Pathol* 22 (Suppl 2): S24-S36, 2009.
32. Delahunt B, Eble JN, Egevad L and Samaratunga H: Grading of renal cell carcinoma. *Histopathology* 74: 4-17, 2019.
33. Swami U, Nussenzveig RH, Haaland B and Agarwal N: Revisiting AJCC TNM staging for renal cell carcinoma: Quest for improvement. *Ann Transl Med* 7 (Suppl 1): S18, 2019.
34. Paner GP, Stadler WM, Hansel DE, Montironi R, Lin DW and Amin MB: Updates in the eighth edition of the tumor-node-metastasis staging classification for urologic cancers. *Eur Urol* 73: 560-569, 2018.
35. Amin MB, Greene FL, Edge SB, Compton CC, Gershenwald JE, Brookland RK, Meyer L, Gress DM, Byrd DR and Winchester DP: The eighth edition AJCC cancer staging manual: Continuing to build a bridge from a population-based to a more 'personalized' approach to cancer staging. *CA Cancer J Clin* 67: 93-99, 2017.
36. Qayyum T, McArdle P, Orange C, Seywright M, Horgan P, Oades G, Aitchison M and Edwards J: Reclassification of the Fuhrman grading system in renal cell carcinoma-does it make a difference? *Springerplus* 2: 378, 2013.
37. Khor LY, Dhakal HP, Jia X, Reynolds JP, McKenney JK, Rini BI, Magi-Galluzzi C and Przybycin CG: Tumor necrosis adds prognostically significant information to grade in clear cell renal cell carcinoma: A study of 842 consecutive cases from a single institution. *Am J Surg Pathol* 40: 1224-1231, 2016.
38. Avulova S, Chevillat JC, Lohse CM, Gupta S, Potretzke TA, Tsvivian M, Thompson RH, Boorjian SA, Leibovich BC and Potretzke AM: Grading chromophobe renal cell carcinoma: Evidence for a four-tiered classification incorporating coagulative tumor necrosis. *Eur Urol* 79: 225-231, 2021.
39. Zhang L, Zha Z, Qu W, Zhao H, Yuan J, Feng Y and Wu B: Tumor necrosis as a prognostic variable for the clinical outcome in patients with renal cell carcinoma: A systematic review and meta-analysis. *BMC Cancer* 18: 870, 2018.
40. Belsante M, Darwish O, Youssef R, Bagrodia A, Kapur P, Sagalowsky AI, Lotan Y and Margulis V: Lymphovascular invasion in clear cell renal cell carcinoma-association with disease-free and cancer-specific survival. *Urol Oncol* 32: 30.e23-e8, 2014.
41. Delahunt B, Srigley JR, Judge M, Amin M, Billis A, Camparo P, Fleming S, Griffiths D, Lopez-Beltran A, Martignoni G, *et al*: Dataset for the reporting of renal biopsy for tumour: Recommendations from the international collaboration on cancer reporting (ICCR). *J Clin Pathol* 72: 573-578, 2019.
42. Joosten SC, Odeh SNO, Koch A, Buekers N, Aarts MJB, Baldewijns MMLL, Van Neste L, van Kuijk S, Schouten LJ, van den Brandt PA, *et al*: Development of a prognostic risk model for clear cell renal cell carcinoma by systematic evaluation of DNA methylation markers. *Clin Epigenetics* 13: 103, 2021.
43. van Vloderop IJH, Joosten SC, De Meyer T, Smits KM, Van Neste L, Melotte V, Baldewijns MMLL, Schouten LJ, van den Brandt PA, Jeschke J, *et al*: A four-gene promoter methylation marker panel consisting of GREM1, NEURL, LAD1, and NEFH predicts survival of clear cell renal cell cancer patients. *Clin Cancer Res* 23: 2006-2018, 2017.
44. Deckers IA, van Engeland M, van den Brandt PA, Van Neste L, Soetekouw PM, Aarts MJ, Baldewijns MM, Keszei AP and Schouten LJ: Promoter CpG island methylation in ion transport mechanisms and associated dietary intakes jointly influence the risk of clear-cell renal cell cancer. *Int J Epidemiol* 46: 622-631, 2017.
45. van Houwelingen KP, van Dijk BA, Hulsbergen-van de Kaa CA, Schouten LJ, Gorissen HJ, Schalken JA, van den Brandt PA and Oosterwijk E: Prevalence of von Hippel-Lindau gene mutations in sporadic renal cell carcinoma: Results from The Netherlands cohort study. *BMC Cancer* 5: 57, 2005.
46. van den Brandt PA, Goldbohm RA, van 't Veer P, Volovics A, Hermus RJ and Sturmans F: A large-scale prospective cohort study on diet and cancer in The Netherlands. *J Clin Epidemiol* 43: 285-295, 1990.
47. Casparie M, Tiebosch AT, Burger G, Blauwgeers H, van de Pol A, van Krieken JH and Meijer GA: Pathology databanking and biobanking in The Netherlands, a central role for PALGA, the nationwide histopathology and cytopathology data network and archive. *Cell Oncol* 29: 19-24, 2007.
48. Klufah F, Mobaraki G, Hausen AZ and Samarska IV: Reactivation of BK polyomavirus in urine cytology is not associated with urothelial cell carcinoma. *Viruses* 12: 1412, 2020.
49. Katz MD, Serrano MF, Grubb RL III, Skolarus TA, Gao F, Humphrey PA and Kibel AS: Percent microscopic tumor necrosis and survival after curative surgery for renal cell carcinoma. *J Urol* 183: 909-914, 2010.
50. Foria V, Surendra T and Poller DN: Prognostic relevance of extensive necrosis in renal cell carcinoma. *J Clin Pathol* 58: 39-43, 2005.
51. Kwon R, Argani P, Epstein JI, Lombardo KA, Wang X, Pierorazio PM, Mehra R and Matoso A: Contemporary characterization and recategorization of adult unclassified renal cell carcinoma. *Am J Surg Pathol* 45: 450-462, 2021.
52. Clemmensen T, Matoso A, Graham T, Lai WS, Rais-Bahrami S and Gordetsky J: Pathologic and clinical characteristics of early onset renal cell carcinoma. *Hum Pathol* 74: 25-31, 2018.
53. Ross H, Martignoni G and Argani P: Renal cell carcinoma with clear cell and papillary features. *Arch Pathol Lab Med* 136: 391-399, 2012.
54. Sika-Paotonu D, Bethwaite PB, McCredie MR, William Jordan T and Delahunt B: Nucleolar grade but not Fuhrman grade is applicable to papillary renal cell carcinoma. *Am J Surg Pathol* 30: 1091-1096, 2006.
55. Rabjerg M, Gerke O, Engvad B and Marcussen N: Comparing World Health Organization/international society of urological pathology grading and Fuhrman grading with the prognostic value of nuclear area in patients with renal cell carcinoma. *Uro* 1: 2-13, 2021.
56. Xiao Q, Yi X, Guan X, Yin H, Wang C, Zhang L, Pang Y, Li M, Gong G, Chen D and Liu L: Validation of the World Health Organization/international society of urological pathology grading for Chinese patients with clear cell renal cell carcinoma. *Transl Androl Urol* 9: 2665-2674, 2020.
57. Shuch B, Bratslavsky G, Linehan WM and Srinivasan R: Sarcomatoid renal cell carcinoma: A comprehensive review of the biology and current treatment strategies. *Oncologist* 17: 46-54, 2012.
58. Park JY, Lee JL, Baek S, Eo SH, Go H, Ro JY and Cho YM: Sarcomatoid features, necrosis, and grade are prognostic factors in metastatic clear cell renal cell carcinoma with vascular endothelial growth factor-targeted therapy. *Hum Pathol* 45: 1437-1444, 2014.
59. Delahunt B, Srigley JR, Amin MB, Billis A, Camparo P, Evans AJ, Fleming S, Griffiths D, Lopez-Beltran A, Martignoni G, *et al*: Invasive carcinoma of renal tubular origin, histopathology reporting guide, 1st edition. International Collaboration on Cancer Reporting; Sydney, Australia, 2017.

60. Bengi  RG, Arribillaga LC, Epelde J, Orellana S, Montedoro A, Bengi  V, Cordero E and Guevara M: Evaluation of microvascular invasion as a prognostic factor in the progression of non-metastatic renal cancer. *Cent European J Urol* 71: 386-390, 2018.
61. Lang H, Lindner V, Letourneux H, Martin M, Saussine C and Jacqmin D: Prognostic value of microscopic venous invasion in renal cell carcinoma: Long-term follow-up. *Eur Urol* 46: 331-335, 2004.
62. Roos FC, Weirich J, Victor A, Els sser A, Brenner W, Biesterfeld S, Hampel C and Th roff JW: Impact of several histopathological prognosticators and local tumour extension on oncological outcome in pT3b/c NOM0 renal cell carcinoma. *BJU Int* 104: 461-469, 2009.
63. Sevin  M, Kirkali Z, Y r kođlu K, Mungan U and Sade M: Prognostic significance of microvascular invasion in localized renal cell carcinoma. *Eur Urol* 38: 728-733, 2000.
64. Van Poppel H, Vandendriessche H, Boel K, Mertens V, Goethuys H, Haustermans K, Van Damme B and Baert L: Microscopic vascular invasion is the most relevant prognosticator after radical nephrectomy for clinically nonmetastatic renal cell carcinoma. *J Urol* 158: 45-49, 1997.
65. Hermanek P, Scheibe O, Spiessl B and Wagner G: TNM classification of malignant tumors: The new 1987 edition. *Rontgenblatter* 40: 200, 1987 (In German).



This work is licensed under a Creative Commons Attribution-NonCommercial-NoDerivatives 4.0 International (CC BY-NC-ND 4.0) License.