

## Conflict of Interest

All authors have no financial disclosures to report.

## Data Availability Statement

The data that support the findings of this study are available from the corresponding author on reasonable request.

## References

1. Spillantini MG, Schmidt ML, Lee VMY, Trojanowski JQ, Jakes R, Goedert M.  $\alpha$ -Synuclein in Lewy bodies. *Nature* 1997;388(6645): 839–840. <https://doi.org/10.1038/42166>
2. Rockenstein E, Nuber S, Overk CR, et al. Accumulation of oligomer-prone  $\alpha$ -synuclein exacerbates synaptic and neuronal degeneration in vivo. *Brain* 2014;137(5):1496–1513. <https://doi.org/10.1093/brain/awu057>
3. Luk KC, Kehm V, Carroll J, et al. Pathological  $\alpha$ -synuclein transmission initiates Parkinson-like neurodegeneration in nontransgenic mice. *Science* 2012;338(6109):949–953. <https://doi.org/10.1126/science.1227157>
4. Shahnawaz M, Tokuda T, Waragai M, et al. Development of a biochemical diagnosis of Parkinson's disease by detection of  $\alpha$ -Synuclein misfolded aggregates in cerebrospinal fluid. *JAMA Neurol* 2017; 74(2):163–172. <https://doi.org/10.1001/jamaneurol.2016.4547>
5. Wang Z, Becker K, Donadio V, et al. Skin  $\alpha$ -Synuclein aggregation seeding activity as a novel biomarker for Parkinson's disease. *JAMA Neurol* Published online September 2020;78(1):30–40. <https://doi.org/10.1001/jamaneurol.2020.3311>
6. Manne S, Kondru N, Jin H, et al.  $\alpha$ -Synuclein real-time quaking-induced conversion in the submandibular glands of Parkinson's disease patients. *Mov Disord* 2020;35(2):268–278. <https://doi.org/10.1002/mds.27907>
7. Stefani A, Iranzo A, Holzkecht E, et al. Alpha-synuclein seeds in olfactory mucosa of patients with isolated REM sleep behaviour disorder. *Brain* 2021;144(4):1118–1126. <https://doi.org/10.1093/brain/awab005>
8. Vivacqua G, Latorre A, Suppa A, et al. Abnormal salivary total and oligomeric alpha-synuclein in parkinson's disease. *PLoS One* 2016; 11(3):e0151156. <https://doi.org/10.1371/journal.pone.0151156>
9. Vivacqua G, Suppa A, Mancinelli R, et al. Salivary alpha-synuclein in the diagnosis of Parkinson's disease and progressive Supranuclear palsy. *Parkinsonism Relat Disord* 2019;63:143–148. <https://doi.org/10.1016/j.parkreldis.2019.02.014>

## Supporting Data

Additional Supporting Information may be found in the online version of this article at the publisher's web-site.

## Both Heterozygous and Homozygous Loss-of-Function *JPH3* Variants Are Associated with a Paroxysmal Movement Disorder

Recently, a single patient with a homozygous truncating variant in *JPH3* and a neurodevelopmental disorder involving paroxysmal dystonia was described.<sup>1</sup> We report both a second individual with recessive disease and a family with a milder phenotype and autosomal dominant inheritance (Fig. 1A).

Patient one, now 15 years old, was born to first-cousin parents with no relevant family or perinatal history. Her mother was asymptomatic, but the medical history of her father was unavailable. Early infant milestones were normal, but she did not walk until 3 years old. At school, she was identified as having moderate intellectual disability and behavioral difficulties. From 6 months old, her mother noticed episodes of abnormal body stiffening. Over time, these evolved into two clear episode types. "Minor" episodes consisted of brief right or occasionally left hemidystonia, which occurred several times each week. "Major" episodes happened two or three times per month and lasted up to 30 minutes. After a similar onset, they progressed to involuntary flailing movements of all limbs, impaired responsiveness, dysarthria, aphasia, and drooling, sometimes associated with upward eye deviation. Although "major" episodes tended to be triggered by fatigue, there was no obvious trigger for "minor" episodes. A clinical diagnosis of alternating hemiplegia of childhood (AHC) was made. Neurological examination between episodes was unremarkable. There was no disease progression over time. There was no clinical response to levodopa, oxcarbazepine, flunarizine, trihexyphenidyl, topiramate, or gabapentin, although prolonged episodes could be terminated with buccal midazolam. Extensive investigation including brain magnetic resonance imaging, electroencephalogram (EEG) (with capture of a typical episode), and cerebrospinal fluid neurotransmitters was normal. Whole genome sequencing (WGS) identified a novel homozygous frameshift in *JPH3* (NM020655.3:c.1310delG; p.Arg437Leufs\*34). Parental DNA was not available for testing. The only other variant of interest was a homozygous *NDUFA5* variant (NM\_024120.5:c.524A>G; p.His175Arg), which was considered unlikely to be relevant because the phenotypic fit for mitochondrial complex I deficiency was poor and in silico tools predicted that it was probably benign.

Patient two, now 10 years old, experienced episodes of limb, facial, and orolingual dyskinesia at least weekly from the age of 6 months (Video S1). These usually started in the right upper limb before becoming generalized and lasted for several hours. No abnormal eye movements were evident during the episodes, and there was no obvious trigger. Between

© 2022 The Authors. *Movement Disorders* published by Wiley Periodicals LLC on behalf of International Parkinson and Movement Disorder Society.

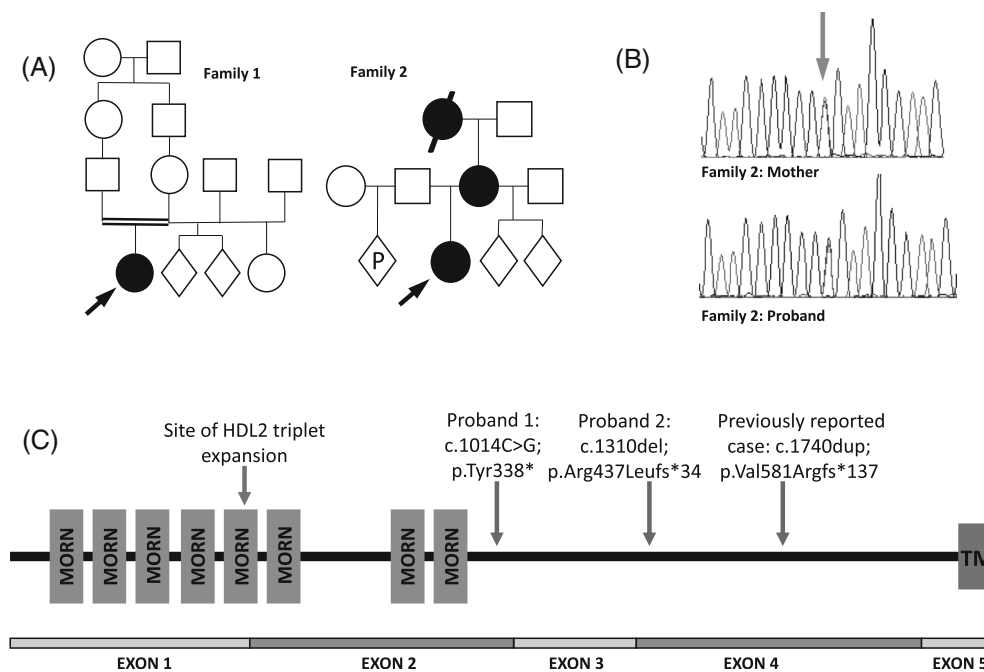
This is an open access article under the terms of the Creative Commons Attribution License, which permits use, distribution and reproduction in any medium, provided the original work is properly cited.

**Key Words:** alternating hemiplegia of childhood; dyskinesia; dystonia; *JPH3*; paroxysmal movement disorder

**\*Correspondence to:** Professor Manju Kurian, NIHR Research Professor and UCL Professor of Neurogenetics, Honorary Consultant Paediatric Neurologist, Zayed Centre for Research into Rare Disease in Children, UCL Great Ormond Street Institute of Child Health, 20 Guilford Street, WC1N 1DZ, London, UK; E-mail: manju.kurian@ucl.ac.uk

**Received:** 21 June 2022; **Revised:** 9 August 2022; **Accepted:** 29 August 2022

Published online 23 October 2022 in Wiley Online Library ([wileyonlinelibrary.com](http://wileyonlinelibrary.com)). DOI: 10.1002/mds.29250





**FIG. 1.** (A) Pedigrees for families 1 and 2. Circle: female; square: male; diamond: sex unknown; P: current pregnancy; black circle or square: affected individual; double horizontal line: consanguineous union. (B) Electrophoretogram of Sanger sequencing showing heterozygous variant present in patient 2 and her mother, indicated by blue arrow. (C) Schematic diagram of the *JPH3* gene. MORN, membrane occupation and recognition nexus repeat domain; TM, transmembrane domain. Site of previously published variants and variants reported here is indicated by arrows. [Color figure can be viewed at [wileyonlinelibrary.com](http://wileyonlinelibrary.com)]

episodes, very mild resting dyskinesia was evident in the upper limbs. She had moderate learning difficulties, but no behavioral issues. Again, extensive investigation was unremarkable, including EEG with capture of episodes. Several different medications—carbamazepine, valproate, topiramate, acetazolamide, and trihexyphenidyl—proved ineffective. Her maternal grandmother had experienced lifelong episodes of orofacial dyskinesia and limb posturing and had never learned to read. Her mother reported episodes of orofacial dystonia triggered by alcohol and had a slight resting tremor. She had completed compulsory education. The only relevant variant identified on WGS was a novel heterozygous nonsense variant in *JPH3* (NM020655.3:c.1014C>G; p. Tyr338\*) shared by mother and daughter: grandmaternal DNA was unavailable (Fig. 1B).

*JPH3* encodes junctophilin-3, a component of the junctional complex linking the plasma membrane with the endoplasmic reticulum in excitable cells.<sup>2</sup> Expression is highest in the brain. Pathological heterozygous triplet-repeat expansion variants (believed to cause toxic intracellular accumulation of abnormal protein)<sup>3,4</sup> occur in Huntington-like disease type 2, characterized by adult-onset chorea, dementia and atrophy of the cortex, and basal ganglia.<sup>5</sup> However, we believe that the disorder from either biallelic or heterozygous truncating variants is a distinct condition, mediated by loss of protein function rather than toxic accumulation, and so far, appears non-progressive in reported cases (Fig. 1C). The gene is predicted to be highly intolerant of loss-of-function,<sup>6</sup> and in mice, both haploinsufficiency and knockout of *JPH3* result in an abnormal motor phenotype.<sup>7</sup> Although the association of the variably penetrant, heterozygous phenotype will require

further confirmation in additional patients, *JPH3* variants should be considered in patients with undiagnosed complex paroxysmal movement disorders. ●

**Acknowledgments:** We are grateful to the patients and their families for their participation. Prof. Kurian's research group has benefited from grants from the National Institute for Health Research, Rosetrees Trust and the Sir Jules Thorne Trust.

Dora Steel, BMBCh,<sup>1,2</sup>  Aikaterini Vezyroglou, MD,<sup>1,2</sup> Katy Barwick, PhD,<sup>1</sup> Martin Smith, MBBS,<sup>3</sup> Julie Vogt, MD,<sup>4</sup> Frances M. Gibbon, MB, ChB,<sup>5</sup> J. Helen Cross, PhD,<sup>1,2</sup> and Manju A. Kurian, PhD<sup>1,2\*</sup> 

<sup>1</sup>Developmental Neurosciences, Zayed Centre for Research into Rare Disease in Children, UCL Great Ormond Street Institute of Child Health, London, United Kingdom, <sup>2</sup>Department of Neurology, Great Ormond Street Hospital, London, United Kingdom, <sup>3</sup>Department of Paediatric Neurology, Oxford University Hospitals NHS Foundation Trust, London, United Kingdom, <sup>4</sup>West Midlands Regional Genetics Service, Birmingham Women and Children's Hospital NHS Foundation Trust, Birmingham, United Kingdom, and <sup>5</sup>Noah's Ark Children's Hospital for Wales, Cardiff and Vale University Health Board, Cardiff, Wales, United Kingdom

## Funding Information

Professor Kurian's laboratory receives funding from the National Institute for Health Research and the Sir Jules Thorn Charitable Trust.

## Data Availability Statement

We are unable to make patients' full genomic data available under the terms of our ethical approval but are happy to share details of methods and laboratory or clinical results on request.

## References

1. Bourinaris T, Athanasiou A, Efthymiou S, Wiethoff S, Salpietro V, Houlden H. Allelic and phenotypic heterogeneity in Junctophilin-3 related neurodevelopmental and movement disorders. *Eur J Hum Genet* 2021;29(6):1027–1031.
2. Takeshima H, Komazaki S, Nishi M, Iino M, Kangawa K. Junctophilins: a novel family of junctional membrane complex proteins. *Mol Cell* 2000;6(1):11–22.
3. Wilburn B, Rudnicki DD, Zhao J, et al. An antisense CAG repeat transcript at JPH3 locus mediates expanded polyglutamine protein toxicity in Huntington's disease-like 2 mice. *Neuron* 2011;70(3):427–440.
4. Krench M, Cho RW, Littleton JT. A drosophila model of Huntington disease-like 2 exhibits nuclear toxicity and distinct pathogenic mechanisms from Huntington disease. *Hum Mol Genet* 2016;25(15):3164–3177.
5. Holmes SE, O'Hearn E, Rosenblatt A, et al. A repeat expansion in the gene encoding junctophilin-3 is associated with Huntington disease-like 2. *Nat Genet* 2001;29(4):377–378.
6. Karczewski KJ, Francioli LC, Tiao G, et al. The mutational constraint spectrum quantified from variation in 141,456 humans. *Nature* 2020; 581:434–443.
7. Seixas AI, Holmes SE, Takeshima H, et al. Loss of junctophilin-3 contributes to Huntington disease-like 2 pathogenesis. *Ann Neurol* 2012; 71(2):245–257.

## Supporting Data

Additional Supporting Information may be found in the online version of this article at the publisher's web-site.