

LESSON OF THE MONTH

Not all stoops are due to osteoporosis

Michael R Ehrenstein, Thomas Stoll, Jo C W Edwards

Case report

A 75 year old woman presented to her local hospital with diffuse low lumbar spine pain and a mild stoop. There was no radiation of pain to the lower limbs. A diagnosis of osteoporosis was made and the patient started to take etidronate (Didronel PMO™). At that time also, a plain lumbar spine radiograph was performed, but not bone densitometry. Three years later the patient presented to our unit with a six month history of an increasingly severe stoop involving the lumbar and thoracic spine despite continued use of etidronate. At the time of presentation, she was unable to rise from a 90 degree anterior inflexion of the spine and found it difficult to do any housework as her head was below the work surface (fig 1). However, the anterior curvature of the spine *disappeared completely* in the supine position. There was no relevant past medical or family history. The patient was a non-smoker. Apart from the abnormality of posture described above, the examination was normal—in particular, there was no significant weakness in the upper or lower limbs, and no other

evidence of neurological deficit. The patient gave no history of psychiatric disturbance, presenting as an intelligent woman with an entirely appropriate attitude towards her physical condition—an impression confirmed by the view of an attending daughter.

Full blood count, erythrocyte sedimentation rate, urea and electrolytes, liver function tests, thyroid function tests, calcium and phosphate, C reactive protein, creatine kinase, and serum protein electrophoresis were all normal. There were no vertebral compression fractures visible on radiograph. Bone mineral density of the lumbar spine demonstrated a bone mass approximately 80% of the age adjusted mean, but within two standard deviations of the mean for her age. Electromyography of the lumbar paraspinal and other muscles, including the quadriceps, showed little spontaneous insertion activity; the motor units were of low amplitude, short duration, and polyphasic. There were also a number of complex repetitive changes. The findings were thought to be consistent with a myopathy. A muscle biopsy of the left quadriceps demonstrated unusually severe type 2 fibre atrophy. There was no myocyte necrosis or inflammatory cell infiltrate. The findings were thought to be consistent with an atrophic myopathy. A magnetic resonance imaging (MRI) scan of the thoracolumbar spine showed diffuse atrophy of the paraspinal muscles and, in addition, heterogeneity of signal with areas consistent with increased water content (fig 2).

On the basis that the patient's myopathy might possibly have an inflammatory basis, she was given a therapeutic trial of 30 mg prednisolone for six weeks, without any clinical response. Etidronate was withdrawn. A lumbar support failed to help. A gutter frame with wheels proved of some help within the home, but the patient still has to climb the stairs to her flat on hands and knees.

Discussion

Dorsal kyphosis is a common presentation in the elderly and is usually attributed to osteoporosis. This patient presented with anterior curvature of the spine that disappeared in the supine position, thus distinguishing it from a kyphotic spine secondary to osteoporosis, which is fixed. The cause of this patient's stoop was attributed to a myopathy with consistent electromyographic (EMG) abnormalities, histological changes on muscle biopsy, and an MRI that showed abnormalities of the lumbar spine musculature. The differential diagnosis of




Figure 1 Photograph of the patient standing unsupported. The flexion of the spine disappeared when the patient adopted a supine position.

Bloomsbury
Rheumatology Unit,
Division of Medicine,
Arthur Stanley House,
London W1P 9PG,
United Kingdom
M R Ehrenstein
T Stoll
J C W Edwards

Correspondence to:
Dr Edwards.

Accepted for publication
13 September 1995

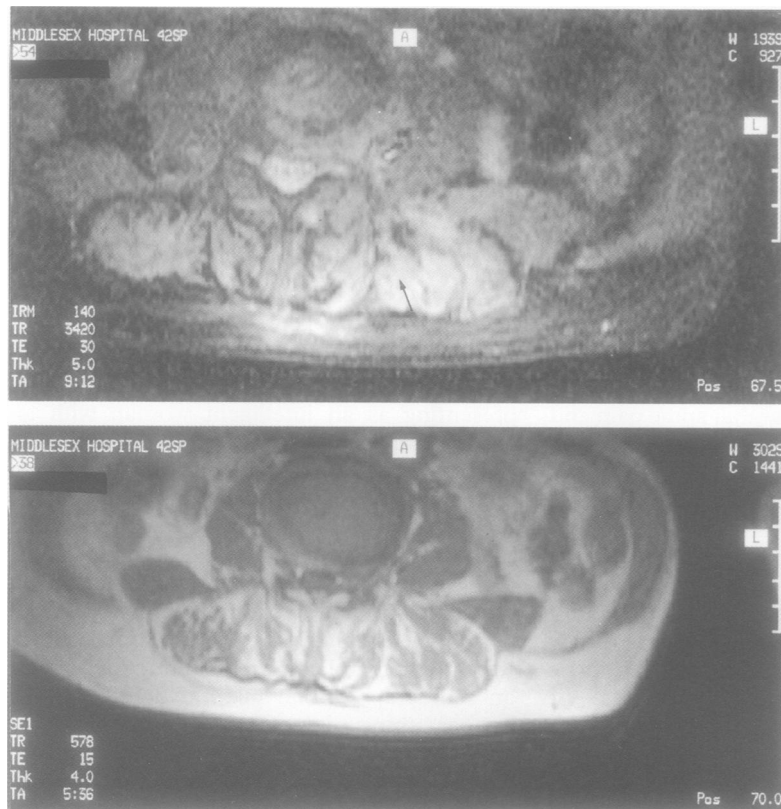


Figure 2 Magnetic resonance imaging scan of thoracolumbar spine showing (top) increase in water content (arrow) and (below) heterogeneity of the paraspinal muscles.

myopathy in the elderly is wide. Although the elderly may be beset by conditions that cause weakness and simulate myopathy, one report demonstrated that the accuracy of clinical diagnosis of myopathy approximates that in a younger population.¹ Osteoporosis of the lumbar spine can cause weakness as a result of disuse atrophy. However, though there was some reduction in bone density at the lumbar spine in our patient, the abnormalities on EMG were widespread and an abnormal muscle biopsy was obtained from the quadriceps muscle. It is unclear whether the etidronate given to the patient described here produced an increase in bone density. However, the weakness progressed throughout this period, implying a process independent of bone density. Moreover, the onset of stoop before institution of etidronate didronel argues against a drug induced problem. Heyburn *et al* found that there was no correlation between myopathy and osteoporosis in postmenopausal women.²

This presentation of a stoop that corrects on lying down was first described as a rare psychogenic disorder affecting military recruits.³ The syndrome, named camptocormia, was thought to be a hysterical conversion reaction with often a clear history of trauma and the existence of secondary gains. There was no consideration of the possibility that there might be an organic basis to camptocormia even as late as 1990.⁴ Since World War II very few cases have been described, but recently a different perspective has been applied to this condition. A number of articles in the French literature have documented a syndrome with the same clinical presentation affecting an

older age group but with definite, if non-specific, changes in the lumbar spine musculature on computed tomography and histology.⁵⁻⁷ These reports have conflicted in their interpretation of the histopathology. Poullin *et al* found that the histological findings were of low specificity and, instead of defining the condition as a myopathy, the authors felt that 'muscular insufficiency' may be a more useful term.⁵ Laroche *et al* concluded that the condition was similar to a primary myopathy with more rapid aging of the paravertebral muscles.⁶ The fact that our patient had abnormal histology present in the quadriceps muscle suggests that the condition may be more widespread in terms of the muscles affected than has been suggested. Electron-microscopy was not performed in our patient and an inclusion body myositis cannot be excluded. However, this does not appear to have been the basis of other reported cases.

It is possible that camptocormia of the elderly may reflect a late form of a muscular dystrophy similar to Bethlem's myopathy,⁸ particularly as a family history has been described by the French authors, though this was not present in our patient. The EMG pattern described here was of a myopathic nature; both Laroche's and Poullin's groups found a myopathic or a neuropathic pattern in an equal number of cases.

This is the first report of camptocormia in the elderly in the English literature. This may imply that the presentation is rare. However, camptocormia may be missed simply because stooped elderly patients are assumed to have osteoporosis. Although there is no specific treatment for camptocormia, a course of steroids has been reported to be effective by one group, who suggested that inflammation was a feature in some patients.⁷ Whether there was an organic explanation to the camptocormia seen in war time is not known, but the fact that there was a family history in more than 50% of cases in one report⁹ may indicate a connection between these two apparently different disorders bearing the same name. Rheumatological texts that mention this condition only include it as a psychiatric condition.¹⁰ We feel that, at least in the elderly, there should be recognition that camptocormia may have an underlying organic pathology.

The lesson

- Not all stoops presenting in the elderly are secondary to osteoporosis.
- If a diffuse kyphosis disappears in the supine position, a diagnosis of camptocormia should be considered.

- 1 Lacomis D, Chad D A, Smith T W. Myopathy in the elderly: evaluation of the histopathologic spectrum and the accuracy of clinical diagnosis. *Neurology* 1993; 43: 825-8.
- 2 Heyburn P J, Peacock M, Casson I F, Crilly R G, Taylor G A. Vitamin D metabolites in post-menopausal women and their relationship to the myopathic electromyogram. *Eur J Clin Invest* 1983; 13: 41-4.
- 3 Souques A. Reformes, incapacities, gratifications dans la camptocormie. *Rev Neurol* 1916; 23: 757.
- 4 Perez-Sales P. Camptocormia. *Br J Psychol* 1990; 157: 765-7.

- 5 Poullin P, Daumen-Legre V, Serratrice G. La camptocormie du sujet âgé: myopathie ou dystonie musculaire? *Rev Rhum* 1993; **60**: 159-61.
- 6 Laroche M, Delise M B, Mazieres B, et al. Myopathie tardive localisée aux muscles spinaux: une cause de cyphose lombaire acquise de l'adulte. *Rev Rhum Mal Osteoartic* 1981; **58**: 829-38.
- 7 Bethlem J, Van-Wyngaarden W. Benign myopathy with autosomal dominant inheritance. *Bram* 1976; **99**: 91-100.
- 8 Hilliquin P, Menkes C J, Laoussadi S, Job-Desandre C, Serratrice G. Camptocormie du suget âgé. Une nouvelle entité par atteinte des muscles paravertebraux? *Rev Rhum Mal Osteoartic* 1992; **59**: 169-75.
- 9 Sandler S A. Camptocormia or the functional bent back. *Psychosom Med* 1947; **7**: 197-204.
- 10 Levine D B. The painful back. In: McCarty D J, ed. *Arthritis and related conditions*. Philadelphia: Lea & Febiger, 1989; 1044-79.