

RHEUMATIC POLYTENDOVAGINITIS

BY

IRVING L. SPERLING

Newark, New Jersey

Inflammatory changes in the tendon sheaths are recognized as a common accompaniment of many rheumatic diseases (Sperling, 1949). In rheumatoid arthritis this is a part of the general rheumatic involvement. Baumgartner (1946) pointed out that the rheumatic picture may present itself primarily with tendon sheath involvement. This picture is apparently rare, with few reports in the literature. For that reason the following case history is given in detail.

Case History

The patient, a 45-year-old white, married man, was first seen on Nov. 12, 1948, with a fifteen-year history of progressive development of nodulations over the finger joints, thickening of the palms, and generalized joint pain. The history revealed nothing important, and there had been no gonorrhoea. He had been a heavy drinker for many years, but had stopped five years previously. He was a mechanical engineer, but had recently, up to the time of his hospitalization, worked as a house painter.

Fifteen years previously he noted a swelling over the dorsum of the proximal interphalangeal joints of the right index finger. This gradually became nodular and was associated with a mildly painful swollen joint. He gradually developed swellings over the proximal interphalangeal joints of many fingers of both hands, chiefly on the dorsum but also anteriorly (Fig. 1, p. 45). During this period he described "bumps" which came and went over the dorsum of the extensor surface of the forearm at the elbow. Five years before he was seen, thickening of the palms had begun, with gradual extension into the fingers on the medial side of the palm (Fig. 2, p. 45). Recently he had developed a nodular swelling over the right infra-patellar area.

During this period there were periodical regressions and recurrence of these infiltrations and swellings for variable periods, with eventual increased extension. He also had generalized aches and pains in the shoulders, knees, wrists and feet. These were not associated with swelling, redness, or increased joint temperatures. The pains were dull, worse in the morning or after excessive activity. Movement of the joints caused only slight increase in the pain. Periodically there were pains and swelling of the elbows with some restricted motion. A year and a half before he was seen, following a bout of biliary obstruction with jaundice, a cholecystectomy was performed. The jaundice remained for almost a month, and during this period he had complete relief from joint pains and stiffness with marked recession of the finger nodules. Several months later the swellings and symptoms recurred. Before hospitalization, following heavy physical effort, he developed severe pains in the shoulders, ankles, and knees.

Examination.—The patient was a well-developed white male, rather distressed and apprehensive. There was a small non-tender nodule over the sixth cervical spine. The shoulders were slightly painful on movement. There was tenderness above and below

the elbows with some limitation of movement, but no swelling or raised temperature. A small nodule freely movable under the skin was noted over the dorsum of the left elbow. The palms of both hands were wet and cold. There was dense infiltration of both palmar spaces over the medial half of the palm with extension to the bases of both little fingers. The overlying skin was partially free and dense. There were no contractures, and movement was unimpaired.

There were non-tender, firm nodulations varying from 0.5 to 4 cm. over the proximal interphalangeal joints of most fingers, anteriorly and posteriorly, as well as over the distal interphalangeal joint of the left middle finger. Similar nodulations were felt over the anterior surface of the proximal phalanges of both hands. These nodulations were not attached to the skin but appeared to be attached to the structures over the joint. They moved readily, and there was no limitation of joint movement. One similar nodule was felt over the right infra-patellar surface. The other joints were normal. The blood pressure was 130.80 mm. Hg. The heart and lungs were normal. The patient was afebrile.

Laboratory Findings.—Urine analysis was normal. The sedimentation rate was 5 mm. in one hour (Westergren); Urea nitrogen was 10 mg. per 100 ml.; uric acid 4 mg.; cholesterol 200 mg.; serum proteins 7.5 g., with albumin 4.9 and globulin 2.6; blood sugar 100 mg. per 100 ml. The Wassermann reaction was negative, cephalin-cholesterol flocculation one plus in twenty-four hours; basal metabolic rate —6. The white blood count was 9,700 with a normal differential count; haemoglobin was 97 per cent. with 4,900,000 red blood cells. The electrocardiogram was normal.

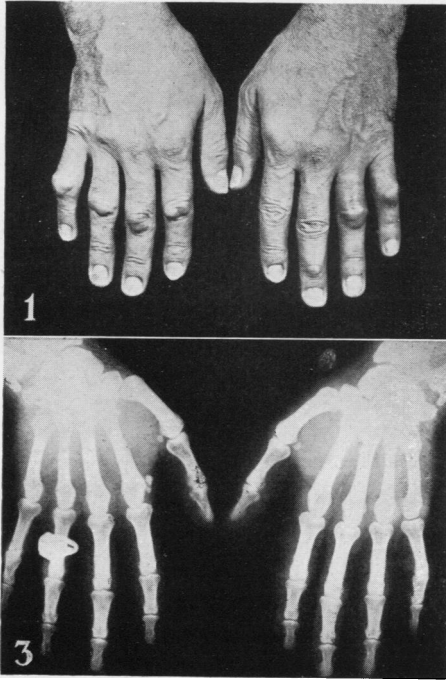
Radiographs.—The chest, skull, and elbows were normal. There was roughening of the greater tuberosity of the right humerus. In the area of the left sub-acromial bursa and under the outer left clavicle there were calcified densities approximately 1.5 cm. wide.

Both hands revealed normal joint spaces. Soft tissue nodulations were noted about the involved joints (Fig. 3, opposite). There were some osteo-arthritic changes about the terminal interphalangeal joints.

The knee joints were not narrowed. There was calcification of the right tibial plateau, and the lateral femoral margins with a spur on the left side.

Course.—During hospitalization he had marked relief of symptoms under a regime of rest in bed, sedation, and physiotherapy. A biopsy of the nodule of the left ring finger over the dorsum of the proximal interphalangeal joint was performed. At operation the nodule appeared as a firm, grey structure which was not attached to skin, but was adherent to the underlying tendon over the joint. It cut with some difficulty. The pathological report was of tendonous tissue showing increased interstitial collagenous material. There was some increased vascularity and a few foci of "round-cell" aggregates containing some cells with vesicular nuclei and pale abundant cytoplasm.

Following discharge on Nov. 22, 1948, the patient was placed on a basic regime of salicylates, physiotherapy, sedation, and, because of symptoms suggesting the climacteric, testosterone propionate, 25 mg. intramuscularly twice weekly and 20 mg. orally daily. This was continued for a period of six weeks, and with this regime there was almost complete disappearance of all symptoms, including increased movement of the elbows. The nodule over the left elbow disappeared completely. During this period there was marked recession, but no complete disappearance of the nodulations over the fingers. On Jan. 18, 1949, following a psychic upset, he had recurrence of pains in all his joints and the size of the nodulations of the fingers increased. He also developed a new nodulation over the dorsum of the terminal interphalangeal joint of the left thumb, and nodules over the dorsum of the right elbow and the left infra-patellar area. His condition continued thus for several weeks. He refused to allow biopsy of the gastrocnemius muscle and the subcutaneous nodule.



FIGS 1 and 3.

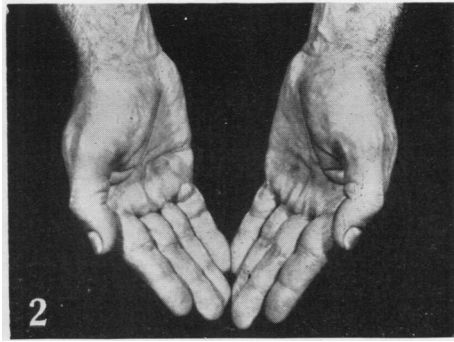


FIG. 2.

Discussion

This case is one of nodular polytendovaginitis probably due to a "rheumatic state", most likely related to rheumatoid arthritis. The subcutaneous nodules, and the disappearance of symptoms during a bout of jaundice, serve further to classify the condition as rheumatoid arthritis.

Tendon-sheath involvement is a well-known finding in rheumatoid arthritis. This varies from simple serous tendovaginitis to chronic isolated or multiple nodular tendonitis. However, involvement of tendon sheaths alone without chronic joint disturbances is rare and serves further to confuse the various clinical pictures of rheumatoid arthritis (Bywaters, 1949); it is a manifestation of the systemic nature of this type of arthritis, with tendonitis assuming dominance.

As far as could be determined there was no intra-articular involvement in this case. There were no signs of synovial swelling, tenderness, or thickening. The nodulations appeared unrelated to any synovial structures, and were primarily related to the tendon tissues. Radiographs failed to reveal any evidence of joint or synovial reaction. Biopsies of joints were not undertaken, and due to the absence of clinical signs of synovial distention, aspiration of synovial fluid was not considered. Furthermore, during the course of the illness there were no complaints of redness or swelling of the involved joints.

Baumgartner (1946) recently reported two cases of "polytendonitis rheumatica". One case was associated with subcutaneous nodules and carditis. The other case was that of a chronic polyarthritis with early tendon-sheath involvement which later gave way to joint manifestations. Biopsy in the first case showed chronic tendovaginitis. Baumgartner stressed the point that tendonitis may assume dominance in the rheumatic syndrome, and he reviewed the literature on this subject, stressing the rarity of this clinical entity.

Roseno (1925) reported two cases of rheumatic tendovaginitis characterized by multiple tendonitis of a serous nature. He claimed a cure by the use of salicylates. Other case reports describe the onset of tendovaginitis, later replaced by arthritis, as an early phase of Still's disease or chronic polyarthritis.

In this author's opinion all these case reports represent various clinical stages of rheumatoid arthritis. This may vary from a pure tendon-sheath involvement, as in the case reported here, through all transitional forms to polyarthritis. Naturally the two may occur together, as evidenced by the occurrence of tendonitis, both acute and chronic, in the course of rheumatoid arthritis with multiple joint involvement. Nodular tendonitis may run a variable course, from an acute stage to a chronic proliferative phase, characterized by exacerbations and remissions as in the case reported here. It is possible that the cases reported by Roseno are an acute phase with a pathological picture of a serous inflammation. The nodular phase is a late proliferative stage with a pathological picture of a chronic tendovaginitis.

Pathologically this condition is related to that seen in rheumatoid arthritis with the basic involvement in tendon tissue instead of the synovia. In rheumatoid arthritis the basic pathology in the synovial membrane reveals hypertrophy of the endothelial lining and stroma, increased vascularity, follicle-like collections of round cells, and pannus formation. Here there are many of the same basic pathological alterations, with follicle-like collections of lymph-cells, mild inflammatory reaction, and increased interstitial collagenous material. However, the changes are definitely in tendon tissue and lack the other characteristics of synovial reaction.

The differential diagnosis of this condition should not be difficult in most cases. Inflammatory lesions of the tendons, such as tuberculosis, lues, and gonorrhoea, offer definite clinical pictures and courses. De Quervain's tendonitis and other traumatic conditions are usually single lesions and offer little difficulty. Tumours, especially xanthoma, may sometimes cause confusion, but the general picture and biopsies will distinguish them. The knuckle pads originally described by Garrod in 1893 and more recently by Parkes-Weber (1938), Jonsson (1949), and others may be the most difficult condition to differentiate. Knuckle pads are uncommon, occurring in the same locations over the extensor surfaces of the proximal interphalangeal joint, but omitting the thumb. They develop slowly and are symptomatic due to mechanical effects only. They frequently have a hyperkeratotic surface and move freely over the joint, but are attached to the overlying skin. The condition is also associated with Dupuytren's contracture. Histologically, they are like true fibroma. It can be seen from this description that differentiation may be almost impossible except by histological examination and by the clinical course.

In the case here reported it is felt that many features serve to substantiate the diagnosis of nodular tendonitis. The histological picture of tendonitis; the recurring subcutaneous nodules; involvement of the thumb, the distal interphalangeal joints, and the anterior surface of the fingers; attachment to joints and freedom of attachment to skin; and remissions with jaundice and therapy; these are some of the features which place this case in the rheumatic group.

Even more important than differential diagnosis is understanding of the

pathogenesis of the condition. This must be considered in the diagnosis of rheumatoid arthritis as one of the clinical manifestations of the systemic nature of the condition, with tendon-sheath involvement assuming dominance. Furthermore it must be remembered that at any point in the chronicity of the condition joint involvement may appear and may assume dominance.

Summary

A case of rheumatic polytendovaginitis is reported and the rarity of the condition is stressed. Its relationship to rheumatoid arthritis is shown; it is thought to be one phase of the systemic disease, with tendon-sheath involvement assuming dominance. Differential diagnosis is discussed, particularly with reference to knuckle pads, which very closely resemble the appearance of the fingers in this condition.

REFERENCES

- Baumgartner, W. (1946). *Schweiz. med. Wschr.*, **76**, 809.
 Bywaters, E. G. L. (1949). *Annals of the Rheumatic Diseases*, **8**, 1.
 Jonsson, E. (1949). *Ibid.*, **8**, 72.
 Kahimeter, G. (1933). *Lancet*, **1**, 1338.
 Parkes-Weber, F. (1938). *Brit. J. Derm. Syph.*, **50**, 26.
 Roseno, A. (1925). *Klin. Wschr.*, **4**, 646.
 Sperling, I. L. (1949). *J. med. Soc. N.J.*, **46**, 430.

Poly-teno-synovite Rhumatismale

RÉSUMÉ

On relate un cas de poly-téno-synovite et on souligne la rareté de cette affection. On montre son rapport avec l'arthrite rhumatismale; on croit qu'il s'agit d'une phase de la maladie générale où l'atteinte de la gaine tendineuse prend la place prépondérante.

On discute le diagnostic différentiel, particulièrement en ce qui concerne les bourrelets articulaires qui donnent aux doigts l'apparence rhumatismale.

Politenosinovitis Reumática

RESUMEN

Se relata un caso de politenosinovitis y se subraya lo raro de esta condición. Se muestra su relación con la artritis reumatoide; se piensa que se trata de una fase de la enfermedad general en que el envolvimiento de la vaina tendinosa ocupa el lugar preponderante.

Se discute el diagnóstico diferencial, particularmente en lo que se refiere a los nudillos entumecidos que dan a los dedos la apariencia reumatoide.