

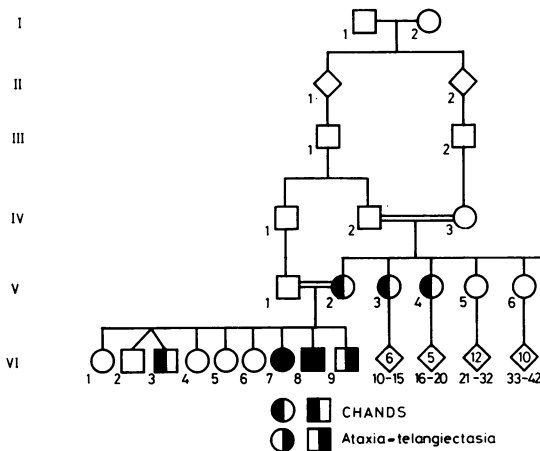Fig. Pedigree of consanguineous family in which 2 traits, CHANDS and ataxia-telangiectasia, are segregating.

Given the more complete pedigree data, it is our belief that this trait is actually an autosomal recessive trait showing quasi-dominant inheritance in this family because of the multiple consanguinity. We have no means of verifying this hypothesis directly because of the extreme rarity of the gene. As far as we are aware, there are no other reported families with this constellation of defects. However, using a means of estimation in which the relative likelihoods of autosomal dominant versus recessive inheritance are weighed, it is discovered that autosomal recessive inheritance is by far the more likely. If we let P_1 equal the probability that IV.2 and IV.3 are both carriers of the gene, given that the gene is an autosomal recessive, and P_2 equal the probability that IV.2 or IV.3 carry the gene, given that the gene is an autosomal dominant, then segregation analysis yields the ratio $162(P_1):P_2$ with the odds being dependent on P_1 and P_2 (Table). If we assume that the ratio of P_1 to P_2 does not differ too drastically from 1:1, then the evidence is greatly in favour of P_1 , and consequently of the gene being an autosomal recessive.

Although a number of other possibilities exist for the occurrence of this rare trait in this family, for

example, polygenic inheritance, greatly reduced penetrance accounting for non-expression in VI.10-20 because of the presence of a modifier gene (which had to be present in IV.2 or IV.3, absent in V.3, 4, and 7, and present again in VI.10-20), and environmental factors, we feel, at least intuitively, that autosomal recessive inheritance is the most likely explanation for the genetics of this rare condition.

HELGA V. TORIELLO, JANICE A. LINDSTROM,
DONALD F. WATERMAN, AND FRED A. BAUGHMAN
Department of Human Development, Michigan State University, Michigan; and El Cajon, California, USA

Reference

Baughman, F. A. (1971). CHANDS: the curly hair-ankyloblepharon-nail dysplasia syndrome. *Birth Defects: Original Article Series*, 7(8), 100-102. The National Foundation—March of Dimes, New York.

Requests for reprints to Dr Helga V. Toriello, Department of Human Development, B-240 Life Sciences, Michigan State University, East Lansing, Michigan 48824, USA.

Table Conditional probabilities of gene

Condition	Conditional probabilities if gene is	
	Autosomal recessive	Autosomal dominant
IV.2 and IV.3 have 4 affected children V.1 is a carrier of the CHANDS gene	$(3/4)^4 (1/4)^4$ $(1/2)^2$	$(1/2)^8$ Not applicable
V.1 and V.2 have 3 affected children and 6 normal children	$(1/2)^9$	$(1/2)^9$
V.3 has 5 normal children	1	$(1/2)^5$
V.4 has 6 normal children	1	$(1/2)^6$
Total conditional probability	$3^4 (1/2)^{27}$	$(1/2)^{28}$

Trisomy 16q arising from a maternal 15p;16q translocation

SUMMARY Trisomy 16q is reported in a malformed infant who died at 12 days of age. The karyotype was 46,XX,der(15)t(15;16)(p11;q11)mat. A balanced translocation was found in the mother. The consequences of various types of aneuploidy of chromosome 16 are discussed.

Complete monosomy and trisomy of chromosome 16 have not been found in the liveborn. Mosaic monosomy 16 has been described in sibs with the Prune Belly syndrome (Harley *et al.*, 1972), though this association is probably fortuitous. In abortion surveys, trisomy 16 is ranked second in frequency to X monosomy as a major cytogenetic abnormality, representing more than a third of all trisomic abortuses (Creasy *et al.*, 1976).

Partial aneuploidy, though rare, has been found in malformed, living, newborn infants, usually associated with unbalanced segregation of a parental translocation. Partial 16q trisomies were described by Eriksson *et al.* (1971), Schmickel *et al.* (1975), and Yunis *et al.* (1977), and partial monosomy 16q by Fryns *et al.* (1977).

We present a case of 16q trisomy in an infant born to a mother carrying a balanced 15p;16q translocation.

Case report

The proband was referred for cytogenetic investigation at the age of 2 days because of developmental abnormalities, 'leprechaun-like facies', cyanosis, abnormal limb flexion, and failure to thrive. The baby was born to Greek Cypriot parents after a pregnancy marked only by falling oestriol levels and the detection of an abnormal head shape by ultrasonography. Birthweight was 1.6 kg and length was 43.5 cm. The mother was 31 and the father 24 years of age.

On examination, the proband was small and emaciated with a small, elongated head (circumference 29 cm, length 10.1 cm, breadth 7.7 cm). She had a narrow face, a very low hair line, downward slanting palpebral fissures, large abnormal ears, prominent beak-like nose, long philtrum, downturned mouth, micro- and retrognathia, and a large scalp lesion on the right temple (Fig. 1). The skin was wrinkled with decreased subcutaneous fat, the limbs were abnormally flexed, and the hands showed a transverse palmar crease on the right and clinodactyly of both 5th digits. There was anterior displacement of the anus which shared a common introitus with the vagina. The baby died after 12 days and necropsy examination revealed an atrial septal defect, pericarditis, transverse linear separation of the occipital bone, inhalation of vomitus, and a primary infarct of the base of the left lung. Histology showed liver congestion with biliary thrombi, fibrosis, and vacuolated cells, patchy haemorrhages in the renal cortex and medulla, atelectasia and many macrophages in lung tissue, and right ventricular myocarditis with thickening of the peri- and endocardium and some vacuolation of myocardial cells.

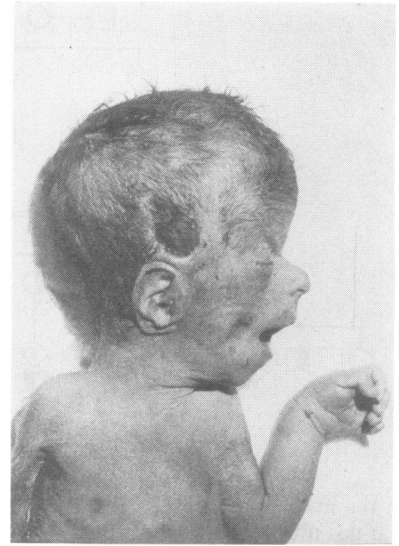

Fig. 1 Face of proband, aged 12 days. Photograph taken post mortem.

No details of a previous pregnancy, resulting in a malformed stillborn infant, were available. A third pregnancy, 18 months after the birth of the proband, was monitored by ultrasonography. At 17 weeks the fetus was found to be small and at 18 weeks an amniocentesis failed. Intrauterine death was noted and the pregnancy was terminated at 20 weeks. The products of conception showed an early stage of mummification and were unsuitable for culture.

CYTOGENETIC STUDIES

Lymphocyte cultures were set up from the proband and both parents. A fascia/muscle biopsy for fibroblast culture, taken post mortem, failed to grow. G-banded preparations revealed a partial trisomy for the long arm of a chromosome 16. One chromosome 15 showed extra material translocated onto the short arm; this proved to represent the greater part of the long arm of a chromosome 16 (Fig. 2). The karyotype was: 46,XX,der(15) (16qter→16q11::15p11→15qter)mat. The mother had a balanced 15;16 translocation: 46,XX,t(15;16) (p11;q11). The father's chromosomes were normal.

Discussion

Balanced 15p;16q translocations were implicated in the present case and two of those published (Schmickel *et al.*, 1975; Yunis *et al.*, 1977). A paternal 16;18 translocation was described in a third report, in which there was the possibility of a small 18q

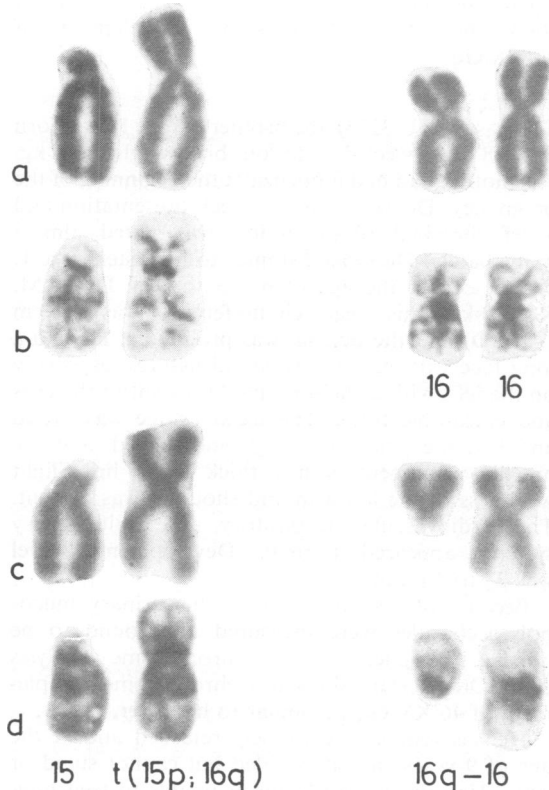


Fig. 2 Partial karyotypes of the proband (a, b, unbalanced translocation 15p;16q with trisomy 16q) and her mother (c, d, balanced translocation). Standard staining, a and c. Trypsin G-banding b and d.

deletion additional to the 16q trisomy (Eriksson *et al.*, 1971). In these cases the extra material comprised most of the 16 long arm, whereas only the distal half of the arm was missing in the one example of partial monosomy (Fryns *et al.*, 1977).

With so few data available, it is premature to attempt to define the phenotype of a 16q trisomy syndrome. Though the present and the three reported cases are very similar, the monosomic infant had many features in common with them. The most notable similarities in the present and published trisomic cases were: developmental retardation, failure to thrive, decreased subcutaneous fat; abnormal facies with downward slanting palpebral fissures, abnormal nose and ears, long philtrum, micro- and/or retrognathia; flexion abnormalities of hand and limbs, and heart defects. The monosomic case showed most of these malformations but with greater severity, while points of difference were

absence of a long philtrum and upward slanting palpebral fissures. Additional features were malrotation of the gut (also shown by Schmickel's case), marked hypertelorism, rockerbottom feet, and talipes. Anterior displacement of the anus and hirsutism were noted only in our patient and the monosomic infant. When allowance is made for the relatively greater severity of the effects of chromosomal loss than those of chromosomal excess, the phenotypes in some monosomies and trisomies of the same chromosomal segments, and even in aneuploidies of different segments, show similarities that are as remarkable as the differences.

Complete trisomy is the most common abnormality of chromosome 16. A recognisable pregnancy may occur, but the fetus is severely disorganised and is rejected by 16 to 18 weeks. This may be because of triplication of the short arm, if the case of Hamerton (1971) is representative. Loss of the short arm and proximal part of the long arm have not been described and probably cause very early rejection of the conceptus. Loss of the distal segment or trisomy of the whole of the long arm produces variable developmental abnormalities, but live birth is possible.

The authors wish to acknowledge the help of Dr Max Friedman who referred the case.

M. A. C. RIDLER AND J. A. MCKEOWN
The Kennedy-Galton Centre, Harperbury
Hospital, Radlett, Hertfordshire

References

- Creasy, M. R., Crolla, J. A., and Alberman, E. D. (1976). A cytogenetic study of human spontaneous abortions using banding techniques. *Human Genetics*, **31**, 177-196.
- Eriksson, B., Fraccaro, M., Hulten, M., Lindsten, J., Thoren, C., and Tiepolo, L. (1971). Two familial translocations, B/18 and 16/18, ascertained through unbalanced forms. *Annales de Génétique*, **14**, 281-290.
- Fryns, J. P., Melchior, S., Jacken, J., and van den Berghe, H. (1977). Partial monosomy of the long arm of chromosome 16 in a malformed newborn: karyotype 46,XX,del(16)(q21). *Human Genetics*, **38**, 343-346.
- Hamerton, J. L. (1971). *Human Cytogenetics*, Vol. 2, pp. 292-293. Academic Press, New York.
- Harley, L. M., Chen, Y., and Rattner, W. H. (1972). Prune belly syndrome. *Journal of Urology*, **108**, 174-176.
- Schmickel, R., Poznanski, A., and Himebaugh, J. (1975). 16q trisomy in a family with a balanced 15/16 translocation. *Birth Defects: Original Article Series*, **11**, No. 5, 229-236. The National Foundation—March of Dimes, New York.
- Yunis, E., González, J. T., and Torres de Cabalero, O. M. (1977). Partial trisomy 16q-. *Human Genetics*, **38**, 347-350.

Requests for reprints to Dr M. A. C. Ridler, Kennedy-Galton Centre for Clinical Genetics, Harperbury Hospital, Harper Lane, Shenley, Radlett, Herts. WD7 9HQ.

Note added in proof

Since submission of this paper, Roberts and Duckett (1978) have reported a live born female infant with trisomy 16p. They also reviewed published reports. Their report modifies the opinion given in the last paragraph of this paper in which it is proposed that triplication of the short arm of chromosome 16 may be incompatible with live birth and may be responsible for fetal loss in full trisomy 16.

Reference

Roberts, S. H., and Duckett, D. P., (1978). Trisomy 16p in a liveborn infant and a review of partial and full trisomy 16. *Journal of Medical Genetics*, 15, 375-381.

Two children with partial trisomy for 7p

SUMMARY A second family in which a balanced translocation between 7p and 22q is segregating is described. The clinical features of 2 children with a resulting partial trisomy for 7p are described and compared with the previously described case.

The report by Larson *et al.* (1977) of a family in which a 7p;22q translocation was segregating prompts us to report a similar family with 2 further children with the unbalanced karyotype and partial 7p trisomy.

Case reports**CASE 1**

This case (PRU 3373) was a baby girl born in 1966 after a normal pregnancy of 40 weeks' gestation, birthweight 2.30 kg. She was hypotonic with a weak cry and multiple anomalies were noted at birth: the skull was elongated with a widely separated metopic suture; she had microphthalmos, the eyes having a mongoloid slant; ears were low set and there was micrognathia; a systolic murmur was present. There were a number of skeletal abnormalities which included arachnodactyly, flexion deformity of the wrists, talipes calcaneo-valgus, and widely separated 1st and 2nd toes. A single palmar crease was present unilaterally. She failed to thrive and died aged 8 weeks.

At necropsy, in addition to the features noted above, she had hydrocephalus and microgyria, a hypertrophic left ventricle with persistent ductus arteriosus, and some aortic stenosis proximal to the ductus. Both kidneys were small with cysts.

Chromosome analysis in 1966 using Orcein stain showed a chromosome complement of 46,XX,Gq+.

CASE 2

This case (PRU 3373), the brother of case 1, was born in 1968 at 38 weeks' gestation, birthweight 3.94 kg. His mother had had influenza at the beginning of the pregnancy. Delivery was in breech presentation and a left brachial plexus lesion was noted almost immediately. He looked similar to his sister, case 1. When seen at the age of 6 months (by Dr S. M. Kohlinsky), his head circumference was 44 cm (+1 SD) and the occiput was prominent. He had a long face with narrow palpebral fissures, especially on the left, with a slight mongoloid slant to the eyes and epicanthic folds. The nasal bridge was broad and flat, the palate was high and arched, and the maxilla prominent with a thick lower lip. Slight weakness of the left arm and shoulder was present. The cardiovascular, respiratory, and genitourinary systems appeared normal. Developmental level was 2½ to 3 months.

Because of his coarse facies, his urinary mucopolysaccharides were measured and found to be normal. Peripheral blood chromosome analysis using Orcein stain showed a chromosome complement of 46,XY,Gq+, similar to his sister, case 1.

He has remained extremely retarded and at the age of 9 years can sit unaided but cannot stand or walk. He says no words and is unable to feed himself. He has had one fit, but is not currently on medication.

Family studies

The mother (born in 1936) has rheumatoid arthritis, the father (born in 1926) is healthy and they are not blood relations. The mother had 2 miscarriages, one at 14 and the other at 16 weeks' gestation, but 2 healthy sons were born in 1970 and in 1973. In 1966, peripheral blood chromosome analysis using Orcein stain showed the father to have a chromosome complement of 46,XY,Gq+ and in 1970 one of the healthy sons was found to have this karyotype also. The father was an only child and no further family studies have been attempted.

It seemed most likely that a balanced translocation was involved, but it was impossible to distinguish the karyotypes of the phenotypically normal family members from those of the abnormal before the development of banding techniques. Early attempts at banding in 1973 were unsatisfactory and for this reason the family decided against prenatal chromosome analysis during the final pregnancy. Chromosome analysis after birth showed the infant to have a normal male chromosome complement 46,XY.