

- Hook, E. B., and Yunis, J. J. (1965). Congenital asymmetry associated with trisomy 18 mosaicism. *American Journal of Diseases of Children*, **110**, 551-555.
- Lewandowski, R. C., Jr., and Yunis, J. J. (1975). New chromosomal syndromes. *American Journal of Diseases of Children*, **129**, 515-529.
- Moorhead, P. S., Nowell, P. C., Mellman, W. J., Battips, D. M., and Hungerford, D. A. (1960). Chromosome preparations of leukocytes cultured from human peripheral blood. *Experimental Cell Research*, **20**, 613-616.
- Purvis-Smith, S., Wertelecki, W., and Sergovich, F. (1976). Trisomy 22 mosaicism and body asymmetry. In *Abstracts of the 5th International Congress of Human Genetics, Mexico, DF, 10-15 October 1976*, p. 148. Excerpta Medica, Amsterdam.
- Robinson, A. E., Parry, W. H., and Blizzard, E. B. (1971). Mosaic trisomy 18. A case reported with some unusual radiologic features. *Radiology*, **100**, 379-380.
- Seabright, M. (1971). A rapid banding technique for human chromosomes. *Lancet*, **2**, 971-972.

Requests for reprints to Dr Moshe Frydman, Department of Pediatrics, Hasharon Hospital, Petah-Tiqva, Israel.

The Prader-Willi syndrome with a 15/3 translocation

SUMMARY A *de novo* translocation of 15q to 3p with complete monosomy of 15p and partial monosomy of 15q was detected by trypsin banding on peripheral lymphocytes of a 5-year-old boy with Prader-Willi syndrome (severe mental retardation, dyslalia, cryptorchidism, and muscular hypotonia). The pathogenic role of chromosome 15 abnormalities in the aetiology of this syndrome is discussed.

About 10% of patients with Prader-Willi syndrome show cytogenetically detectable abnormalities of a D chromosome, usually the translocation of one of the D chromosomes to another chromosome. Hawley and Smithies (1976) suggest that it is chromosome 15 which is involved in the pathogenesis of this syndrome.

Using the trypsin banding method (Burkholder and Comings, 1972), we have detected a *de novo* unbalanced translocation of the distal part of the long arms of chromosome 15 to the short arms of chromosome 3 in a patient with Prader-Willi syndrome.

Case report

The boy was the first child of healthy young parents; his birthweight was 2750 g, length 50 cm. Psycho-

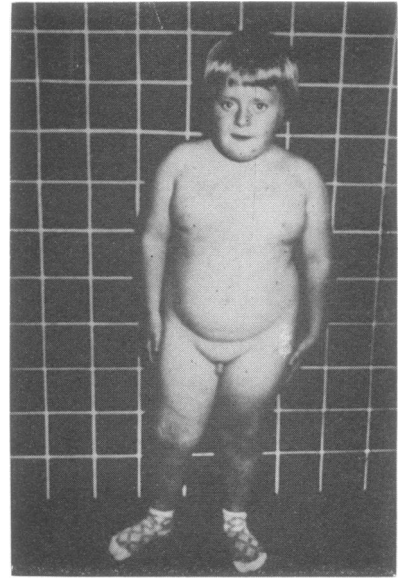


Fig. 1 The patient showing obesity, muscular hypotonia, genua valga, and hypogonadism.

motor retardation was obvious from the first months of his life. He started to walk at the age of 20 months and to speak at 3 years. Now, at 5 years old, his mental ability corresponds to debilitas gravis. Other clinical symptoms are obesity (+4.5 sigma), muscular hypotonia, genua valga, cryptorchidism, and dyslalia (Fig. 1).

His parents and younger brother are healthy with a normal karyotype.

CYTOGENETIC STUDIES

There was complete monosomy of the short arms and partial monosomy of the long arms of chromosome 15, and probably also monosomy of a small part of the short arms of chromosome 3 (Fig. 2).

The karyotype was 45,XY,-3,-15,+t(3;15)(p25;q15) or 45,XY,-3,-15,+t(3;15)(3qter→3p25::15q15→15qter).

Discussion

The unbalanced chromosomal translocation described is quite rare; we have failed to find a similarly abnormal karyotype in published reports. The clinical signs of our patient support the hypothesis of Hawley and Smithies (1976) about the role of the short arms of chromosome 15 in the Prader-Willi syndrome. Some of the other karyotypes of reported patients are also in agreement with this hypothesis

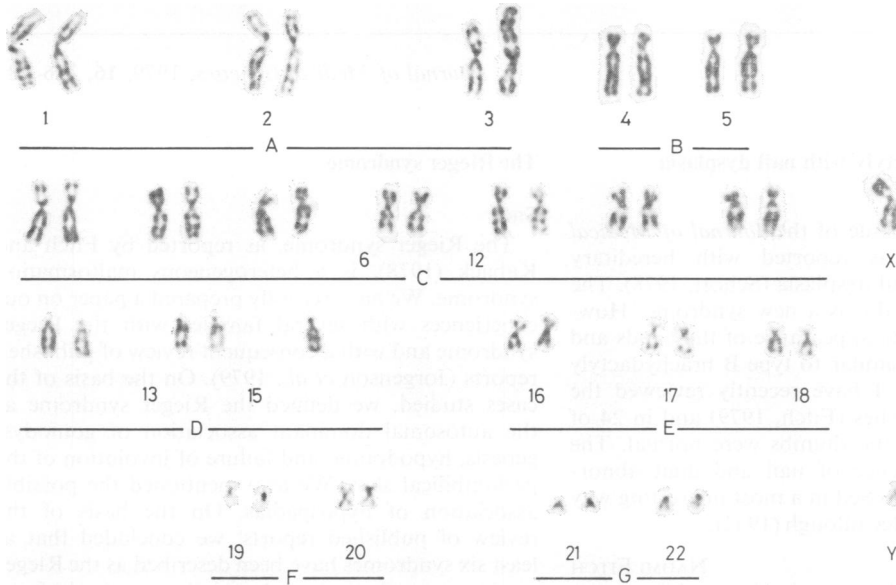


Fig. 2 Karyotype of the patient with a 15/3 translocation.

(Buhler *et al.*, 1963; Schneider and Zellweger, 1968; Sylvester *et al.*, 1971). Nevertheless, more data are necessary for a final conclusion.

MARIA KUČEROVÁ, MARTA STRAKOVÁ, AND
ZDENKA POLÍVKOVÁ
Pediatric Department of the Postgraduate
Medical Institute, Thomayer's Hospital,
Prague, Czechoslovakia

References

- Buhler, E. H., Rossier, R., Bodis, I., Vulliet, V., Buhler, U.K., and Stalder, G. (1963). Chromosomal translocation in a mentally deficient child with cryptorchidism. *Acta Paediatrica Scandinavica*, **52**, 177-182.
- Burkholder, G. D., and Comings, D. E. (1972). Do the Giemsa-banding patterns of chromosomes change during

embryonic development? *Experimental Cell Research*, **75**, 268-271.

Hawkley, C. J., and Smithies, A. (1976). The Prader-Willi syndrome with a 15/15 translocation. Case report and review of the literature. *Journal of Medical Genetics*, **13**, 152-157.

Schneider, H. J., and Zellweger, H. (1968). Forme fruste of the Prader-Willi syndrome (HHHO) and balanced D/E translocation. *Helvetica Paediatrica Acta*, **2**, 128-136.

Sylvester, P. E., Richards, B. W., Rundle, A. T., and Steward, A. (1971). Pathological observation in a male patient with D-ring chromosome. *Journal of Mental Deficiency Research*, **15**, 207-223.

Requests for reprints to Dr M. Kučerová, Pediatric Department of the Postgraduate Medical Institute, Thomayer's Hospital, Budějovická 800, Prague 4, Czechoslovakia.