

Trisomy 13 and extended survival

SUMMARY A 9-year-old boy with classical clinical features of trisomy 13 (Patau's syndrome), with confirmation on chromosome analysis of blood and skin, is reported in view of his relative longevity.

Survival of patients with trisomy 13 (Patau's syndrome) is rare beyond the age of 12 months. Taylor (1968) gave a mean survival time of 89.2 days based on 74 cases. Magenis *et al.* (1968) reviewed 178 primary trisomic cases derived from various sources and found that 86% had died in their first year. Isolated cases of survival beyond 5 years have been reported (Smith, 1964, 1976; Magenis *et al.*, 1968; Mankinen and Sears, 1976; Hodes *et al.*, 1978), but apparently none has been able to exclude the possibility of mosaicism in more than one tissue.

We wish to report a case of a boy, now 9 years old, with confirmed primary trisomy 13 in both blood and skin tissues.

Case report

This boy was the second child of unrelated parents, both of whom were 33 years old when he was born. The father was an insulin-dependent diabetic and the mother was entirely healthy. The child was born on 26 July 1969, weighing 3.35 kg, and had a number of congenital defects. The major defect was exomphalos and this was repaired soon after birth. At this time he was recorded as having a curious facial appearance with low set ears, flat nose, and bilateral microphthalmia and colobomata. There were no abnormalities of the lip or palate. There were bilateral simian creases and the fingers were clenched with overriding thumbs. Polydactyly was noted. His genitalia were ambiguous with a small phallus and no testes could be felt. A cardiac murmur was heard and attributed to a ventricular septal defect. An intravenous pyelogram showed absence of the right kidney.

The child was followed up in outpatients and is now 9 years old. He is small (12.5 kg) and microcephalic, with an occipitofrontal circumference of 47 cm (Fig. 1). He has severe mental and physical retardation. Though he has head control, he cannot sit

unsupported. When lying on the floor he moves by rolling. He can hold a rattle, but makes no attempt to reach for one. His hearing appears normal and he obviously enjoys noises. There is a right microphthalmos with cataract and bilateral colobomata. He has a fish-like mouth. The fingers are long and tapering with hyperconvex narrow finger nails. His extra digits have been removed. There are bilateral simian creases and overriding 3rd toes (Fig. 2). The heart murmur is now consistent with an atrial septal defect. He has a micro penis, but both testes are now palpable in the scrotum.

CLINICAL INVESTIGATIONS

Full blood count revealed a haemoglobin of 6.7 g/dl because of dietary deficiency of iron and folate. Haemoglobin was of the adult type. Some neutrophils showed an increased number of nuclear appendages. The platelet count was normal. X-ray of his abdomen showed generalised gut distension, interposition of the colon between the liver and the right diaphragm, and dysplastic hips. The electrocardiogram was consistent with an atrial septal defect of the secundum type.

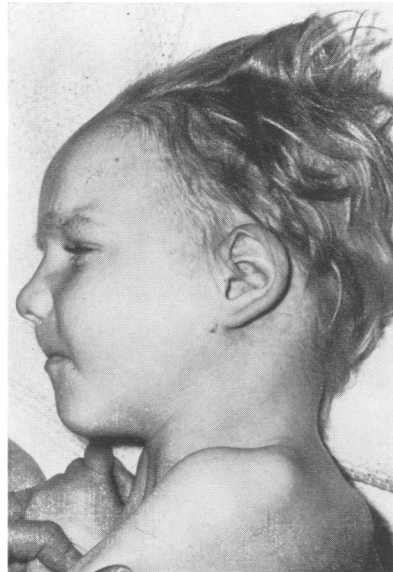

Fig. 1 Side view of patient's head at 8.5 years of age.

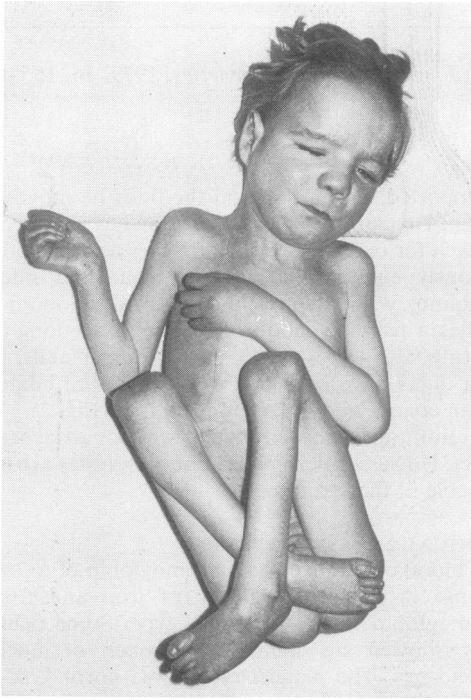


Fig. 2 Full view of patient at 8.5 years of age.

CYTOGENETIC STUDIES

Peripheral blood from the child was investigated first in 1969, when he was 6 days old. Chromosome analysis at that time revealed a majority of cells with a count of $2n = 47, XY+D$. Three cells contained 46 chromosomes, but all included an extra D chromosome and showed random other losses. One cell had 48 chromosomes containing, in addition to the 7 Ds, an extra G-like chromosome. Neither the cells containing $2n = 46$ nor 48 were considered significant and a diagnosis of trisomy D was made.

No further attempt was made to ascertain which D chromosome was involved until 1977 when, following the unusual length of survival, blood and skin specimens were taken for reinvestigation. From the blood specimen, 70 mitoses were counted to bring the total from this and the original specimen to more than 100 cells. All contained 7 D chromosomes (Table). Analysis after trypsin banding (Seabright, 1971) in the second specimen confirmed trisomy 13 (Fig. 3) and the one cell with 46 chromosomes had a number 20 missing.

Table Chromosome counts

Tissue	Date	45	46	47	48	Total counted
Blood	1.8.69	—	3	30	1	34
Blood	26.8.77	—	1	69	—	70
Skin	26.8.77	1	4	55	—	60

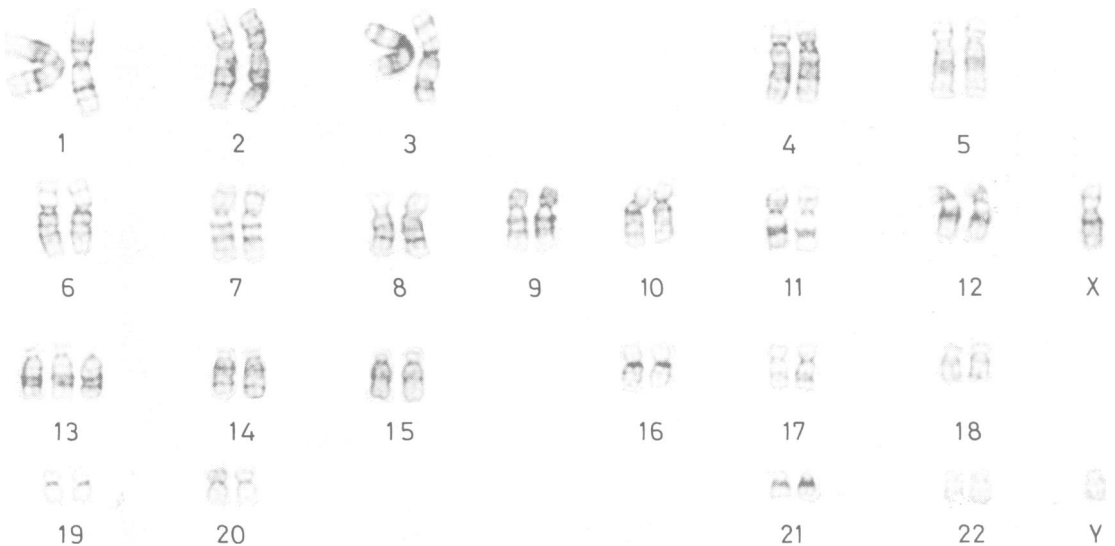

Fig. 3 Karyotype showing $2n = 47, XY+13$ from a blood culture cell. The chromosomes were trypsin banded and stained in Leishman.

From the skin culture, 60 cells were counted. Only 4 cells contained 46 chromosomes, one 45, and the remainder 47. Confirmation of trisomy 13 was again obtained after trypsin banding, but the 4 cells with 46 chromosomes were banded unsatisfactorily for complete analysis. Of these, 2 contained 7 D chromosomes and 2 only 6.

Discussion

Trisomy 13 has been well recognised since the first modern description by Patau *et al.* (1960). This boy shows many of the clinical features of the syndrome and several are associated with a poor prognosis.

In the review by Magenis *et al.* (1968), it was noted that those with chromosomal mosaicism, or with a Robertsonian translocation, tended to survive longer than those with primary trisomy. However, Hodes *et al.* (1978) did not find any difference in survival rates between their cases of translocation and primary trisomics. Among the cases in published reports with survival beyond 5 years, Smith (1964, 1976) mentioned a child of 5 years and an adult of 33 years, but did not give any indication of the cytogenetic findings. Magenis *et al.* (1968) reported a girl aged 10 with trisomy D, but gave no details of cytogenetic studies. Mankinen and Sears (1976) and Hodes *et al.* (1978) each reported a girl aged 5.25 years and 5.5 years, respectively, with evidence of trisomy 13. Only blood specimens were investigated, but no mosaicism was detected.

Two types of tissue, blood and skin, have been studied in our patient. The results from both confirm trisomy 13 and provide strong evidence for excluding mosaicism. In the total of 164 cells counted, only 8 contained a complement of 46 chromosomes, and 6 of these were found to include 7 D chromosomes. Hence, it is most probable that these 8 cells represent those originally with $2n = 47, XY+D$, but with subsequent random chromosome loss. Our patient is unusual, therefore, in surviving as long as he has, since he is now 9 years of age. There may be several factors to account for this. It has been stated that surgery should not be considered in early infancy in children with Patau's syndrome (Smith, 1976) and doubtless this accounts for some of the mortality in the neonatal period and shortly thereafter. The child reported here had his omphalocele repaired surgically soon after birth. His other anomalies are not directly life threatening. Furthermore, the devoted care and attention he receives from his parents are contributing considerably to his relative longevity.

We thank Mrs G. A. Holmes and Mrs M. C. Winn for technical assistance.

JENNIFER M. COWEN, S. WALKER, AND
F. HARRIS

*Department of Child Health,
Alder Hey Children's Hospital,
Liverpool; and the
Cytogenetics Unit,
University of Liverpool, Liverpool*

References

- Hodes, M. E., Cole, J., Palmer, C. G., and Reed, T. (1978). Clinical experience with trisomies 18 and 13. *Journal of Medical Genetics*, **15**, 48-60.
- Magenis, R. E., Hecht, F., and Milham, S., Jr. (1968). Trisomy 13 (D) syndrome: studies on parental age, sex ratio and survival. *Journal of Pediatrics*, **73**, 222-228.
- Mankinen, C. B., and Sears, J. W. (1976). Trisomy 13 in a female of over 5 years of age. *Journal of Medical Genetics*, **13**, 157-161.
- Patau, K., Smith, D. W., Therman, E., Inhorn, S. L., and Wagner, H. P. (1960). Multiple congenital anomaly caused by an extra chromosome. *Lancet*, **1**, 790-793.
- Seabright, M. (1971). A rapid banding technique for human chromosomes. *Lancet*, **2**, 971-972.
- Smith, D. W. (1964). Autosomal abnormalities. *American Journal of Obstetrics and Gynecology*, **90**, 1055-1077.
- Smith, D. W. (1976). *Recognisable Patterns of Human Malformations. Genetic, Embryologic, and Clinical Aspects*, 2nd ed., pp. 14-17. Saunders, Philadelphia.
- Taylor, A. I. (1968). Autosomal trisomy syndromes: a detailed study of 27 cases of Edwards' syndrome and 27 cases of Patau's syndrome. *Journal of Medical Genetics*, **5**, 227-252.

Requests for reprints to Dr S. Walker, Cytogenetics Unit, School of Medicine, University of Liverpool, P.O. Box 147, Liverpool L69 3BX.

Anencephaly with diaphragmatic hernia in sibs

SUMMARY Two sibs who both had anencephaly and diaphragmatic hernia are reported. The type of diaphragmatic defect seen in anencephaly may differ from the defect seen in other babies. It is important to perform a necropsy in anencephaly.

This paper reports 2 sibs who had anencephaly and a diaphragmatic hernia.

Case report

The mother was 21 and the father 25 at the birth of their first child. Both were healthy, and there was no family history of malformations and no consanguinity.