

The 45XO/46XY Mosaic Intersex Syndrome

W. P. U. JACKSON, MARGARET HOFFMAN, and HAWA MAKDA

From the Endocrine Research Group of the Council for Scientific and Industrial Research, the Department of Medicine, University of Cape Town, and Groote Schuur Hospital, Cape, South Africa

A new clinical intersexual syndrome is becoming apparent as an increasing number of subjects are being described who have the chromosome mosaicism designated as XO/XY. These patients are most frequently phenotypic females with an enlarged clitoris and internally a testis and contralateral 'streak gonad', but there are several variations on this general theme.

We here describe two examples of the XO/XY syndrome and briefly review other reported cases (Table I). Our own patients, one a phenotypic female and the other a 'fertile' phenotypic male, show certain unusual features and a clear connexion with Turner's syndrome.

Case Reports

Case A.I. (No. 14 in Table 1) (Fig. 1). A coloured female was seen by us at the age of 16 because of clitoral enlargement (which had first been noted in infancy), primary amenorrhoea, shortness of stature, and mental retardation. Little family history was available, but her twin brother and younger sister are reported to be quite normal. Her height was 55.5 in. (140 cm.) with lower segment 27 in (68 cm.) and span 56 in. (142 cm.). There was no webbing of the neck; the hair-line was normal. A pigmented naevus was present on the face. The chest was shield-like; there was cubitus valgus; there were no short metacarpals. Pubic hair was scanty and there was no axillary hair. Breasts were completely undeveloped. On examination of the external genitalia the clitoris was noted to be 4 cm. long with a urethral opening just anterior to the vagina. The vagina was 4 cm. long and no cervix was felt.

Bone-age was 13 years. There was no evidence of osteoporosis.

Radiological examination of the abdomen and intravenous pyelogram showed kidney shadows and function to be normal. 17-ketosteroids 9.4 mg./24 hours (Appleby, Gibson, Norymberski, and Stubbs, 1955), 17-OH-corticosteroids, 14.4 mg./24 hours (Bloomberg, Alldis, Jankelowitz, and Wolmer, 1955) urinary gonadotropins (FSH), 96 mouse uterine units in 24 hours (normal adult

female 6-48 (Bloomberg *et al.*, 1955)). Colour vision was normal (Ishihara charts).

Laparotomy revealed a rudimentary uterus, 3 cm. × 1 cm. From the angles of the uterus ran rudimentary tubes 5 cm. long. The fimbriated end of the left tube was seen, while the right was suspended from the posterior layer of the broad ligament (a vas deferens). On the left there was a thin ridge of whitish tissue, 3 cm. long, in the primitive ovarian position. On the right side was a gonad, 1 cm. × 0.5 cm., resembling testicular tissue. Kidneys were normal. The uterus, tubes, and all gonadal tissue were removed.

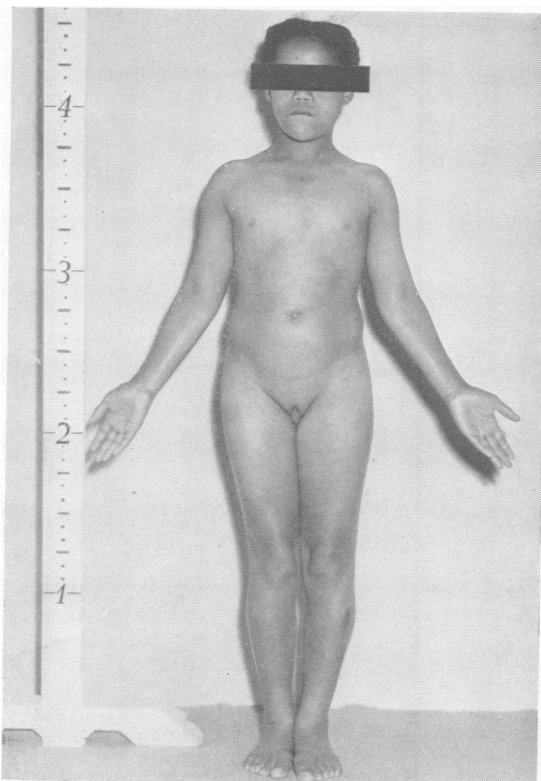


FIG. 1. A.I. (Case 14 in Table I). Note feminine build, short stature, enlarged clitoris.

TABLE I
DETAILS OF CASES OF XO/XY MOSAIC

Case No.	Author	Year	Age (yr.)	Stature	Turner's Syndrome Anomalies	External Sex Features	Internal Sex Apparatus	Gonadal Histology	Chromosomes
1	Blank, Bishop, and Caley	1960	55	Short	Low IQ, short neck, broad chest	(1) XO/XY No breasts, large clitoris, narrow hips	Female Phenotype Small uterus, left 'ovary', right no gonad	Not done	41XO/58XY
2	Hirschhorn, Decker and Cooper	1960	3 mth.	—	—	Large phallus	Uterus, tubes, and 2 gonads	Right ovotestis, tubular structures and ovarian follicles	12XO/8XY (bone-marrow)
3	Jacobs, Harnaden, Buckton, Court Brown, King, McBride, MacGregor, and Maclean	1961	26	Short	—	'Undeveloped genitalia'	Bilateral 'streak gonads'	Ovarian stroma only	15XO/82XY (blood)
4	Jacobs <i>et al.</i>	1961	30	4 ft. 10 in. (147 cm.)	—	'Undeveloped genitalia'	Bilateral 'streak gonads'	Connective tissue and theca-like cells	140XO/86XY (blood)
5	Judge, Thompson, Wilson, and Thompson	1962	26	5 ft. 8 in. (173 cm.)	Low IQ	No breasts	Small uterus, two 'ovaries'	Right—stroma only, left not examined	27XO only skin 35XO/38XY (blood)
6	Miller	1962	—	—	'Variant of Turner's syndrome'	Large clitoris	Vagina, uterus, tubes	One gonad absent, other clump of Leydig cells only	XO/XY
7	Willemse, Van Brink, and Los	1962	22	4 ft. 9 in. (145 cm.)	—	Small breasts, 'boyish build', large clitoris	Uterus, tubes, and two 'testes'	Tubules and Leydig cells in both	52XO/48XY (blood)
8	Turner, Greenblatt, and Dominguez	1963	14	Short	Cubitus valgus, webbed neck, low hair-line	No breasts, hairy, low voice, enlarged clitoris	Infantile uterus, tubes, one gonad, and streak	Testis and rudimentary streak	10XO/27XY (blood)
9	Turner <i>et al.</i>	1963	13	Short	Low hair-line	Acne, no breasts, low voice	Uterus, tubes, one gonad, and streak	Right testis with tubules and Sertoli cells, left—rudimentary streak	11XO/48XY (blood)
10	Meliman, Klevit, Yakovac, Moorhead, and Saksela	1963	9	Short	—	Large clitoris, urogenital sinus	Normal female	Right—degenerate tubules, left—semimittreous tubules	Left skin XO only, right skin XO/XY, left gonad XO only, right gonad XO/XY, uterus XO only, testis XO (blood)
11	Greenblatt, Dominguez, Maresh, and Greenblatt <i>et al.</i>	1964	4½	—	'Turner-like'	Large clitoris	Right testis, left—streak	Right—immature testis, left—dysgenetic gonad	20XO/63XY
12	Greenblatt <i>et al.</i>	1964	14	—	—	Large clitoris, no secondary sex characters	Uterus, bilateral tubes, left testicle, right streak	Right—connective tissue, left—tubules, Leydig cells	Not given
13	Sohval	1964	4 mth.	—	—	Large phallus, labio-scrotal fusion, descended gonad on right	Uterus, vagina, left tube	Right—descended testis immature, left—rudimentary streak	Not given
14	Present case (A.I.)		16	Short	Shield-like chest, cubitus valgus, low IQ, pigmented naevi	No breasts, scanty sex hair, large clitoris	Rudimentary uterus tubes, right testis, left streak	Right—tubules with Sertoli cells, no spermatogenesis; Leydig cells, left—stromal tissue only	26XO/3XY (blood) 26XO/2XY (skin)

15	De La Chapelle and Hortling	1962	42	5 ft. 3 in. (160 cm.)	—	(2) XO/XY Male Phenotype Breasts ±, hypoplasia, single gonad in scrotum Blind scrotum, hypoplasia; no gonads felt Single small gonad in scrotum	— Rudimentary uterus, tubes; two gonads	Left testis, tubules and Leydig cells, no spermatogenesis Right and left testis with tubules and spermatogonia 24XO/XY (blood) 45XO/5XY (blood) 7XO/16XY (skin) 22XO/15XY (blood)
16	Ferrier, Gartler, Waxman, and Shepard	1962	11	4 ft. 2 in. (127 cm.)	—	—	—	Left testis tubules and Leydig cells Right testis with spermatogenesis 5XO/13XY (blood) 10XO/16 XY (skin)
17	Ferrier, Ferrier, Klein, and Fernex	1963	35	5 ft. 9 in. (175 cm.)	—	Single small gonad in scrotum	—	Left testis tubules and Leydig cells Right testis with spermatogenesis
18	Present case (A.M.)	—	25	4 ft. 8 in. (142 cm.)	Pigmented naevi, blue sclera, short metacarpal	Hypospadic penis, Rt. gonad in scrotum, male hairiness	Rudimentary uterus, right vas deferens, left tube and streak	Right testis with spermatogenesis
19	Age and Phenotype Miller	1962	Female	—	—	(3)XO/XY With 'True hermaphrodite'	Tumour Vagina, uterus, and tubes, left gonad missing	Right—testicular tissue, ovarian stroma, and undifferentiated seminoma Right—ovarian tissue; left—ectopic malignant seminoma Right—invasive neoplastic tissue; left—fibrous streak
20	Lewis, Mitchell, and Foss	1963	45 Male	—	—	Hypospadias, small vaginal orifice (married)	Uterus rudimentary, right fallopian tube	Right—testicular tissue, ovarian stroma, and undifferentiated seminoma Right—ovarian tissue; left—ectopic malignant seminoma Right—invasive neoplastic tissue; left—fibrous streak
21	Sohval	1964	22 Female eunuchoid	—	—	Hypoplastic genitalia, large clitoris, small breasts	Uterus and cervix	Right—testicular tissue, ovarian stroma, and undifferentiated seminoma Right—ovarian tissue; left—ectopic malignant seminoma Right—invasive neoplastic tissue; left—fibrous streak
22	Conen <i>et al.</i>	1961	13 Female	4 ft. 10 in. (147 cm.)	—	(4) Closely Related Cases (<i>not</i>) No breasts, large clitoris, deep voice	XO/XY Small vagina, uterus, and tubes	Right—ovarian stroma, left—testis and epididymis Right—tubules and Leydig cells; left—fibrous tissue
23	Schuster and Motulsky	1962	18 Female	—	—	No breasts, shaves, labioscrotal fusion, large phallus	Uterus, fallopian tube, vas deferens both sides, streak and gonad	Right—ovarian stroma, left—testis and epididymis Right—tubules and Leydig cells; left—fibrous tissue
24	Miles <i>et al.</i>	1962	1 Male	—	—	Phallus 1.5 cm., large labia, no gonads felt	Normal uterus and tubes	Both gonads infantile, seminiferous tubules and rete testis Right—connective tissue, left—rudimentary testis Testis on one side, streak on other Right—immature testis, left—agenesis
25	Bloise <i>et al.</i>	1960	18 Male	Short	Low hair-line and ears	Hypospadias, bifid scrotum, small penis 'Ambiguous' sex	Uterus, vagina, and tubes	36XO/8XXY (small X), no drumsticks 47 chromosomes 13XO (bone-marrow)
26	Ferguson-Smith and Johnston	1960	Male	—	—	'Ambiguous' sex	Uterus and tubes	XO (blood)
27	Bottura and Ferrari	1962	9 Female	—	—	Large phallus, small vagina	Rudimentary uterus and tubes	XO (bone-marrow)
28	Atkins and Engel	1962	22 Female	Short	—	Extra-abdominal 'testis' in left labial fold, no breasts, large clitoris	Small uterus, vagina, and tubes	XO (skin and blood)

Dashes indicate that information is not recorded.

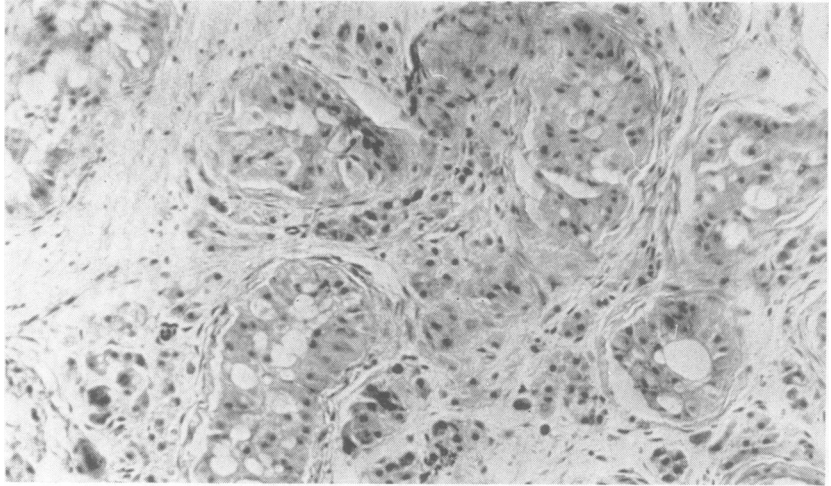


FIG. 2. A.I. Testicular tissue showing tubular structures lined by Sertoli cells. Leydig cells numerous, no spermatogenesis.

Histology. The right gonad showed numerous tubular structures lined by Sertoli cells (Fig. 2). There was no evidence of spermatogenesis. Leydig cells were numerous and mature looking, and no ovarian tissue was demonstrated. The streak of tissue removed on the left side consisted of dense stromal tissue which might have been ovarian. There were scattered groups of cells in relation to nerve cells and blood vessels which resembled Leydig cells.

Cytogenetic Investigations. Skin (nuclei of stratum germinativum (Harnden, 1960)): chromatin negative; buccal smear (Ross, 1960): chromatin negative; polymorphonuclear leucocytes (Davidson and Smith, 1954): no drumsticks seen in 500 cells. Leucocyte culture was after the method of Moorhead, Nowell, Mellman, Battips, and Hungerford (1960) (Table II).

TABLE II
CHROMOSOME ANALYSES IN CASE A.I.*

Tissue	No. of Chromosomes			
	43	44	45	46
Lymphocytes of blood:				
1st culture	13	—	23	
2nd culture	2	—	26	3
Skin	1	3 (variable)	26	3

*The XO and XY mitotic lymphocyte nuclei were exactly similar to those of A.M. (Fig. 6 and 7) and are not separately depicted. The '43 chromosome' nuclei are also not shown here but photographs are available on request.

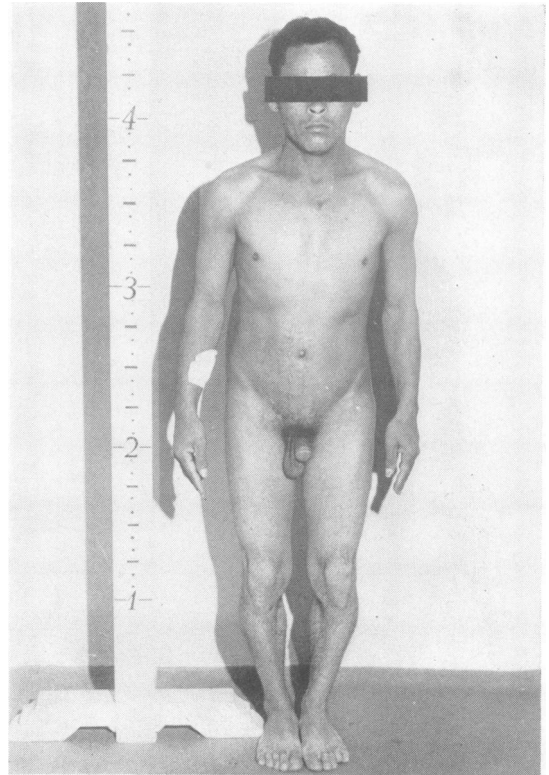


FIG. 3. A.M. (Case 18 in Table I). Note masculine build, short stature, single descended gonad.

All cells with 45 chromosomes had only 15 in the X-6-12 group (i.e. presumptive XO pattern), and 5 of the 6 cells with 46 chromosomes contained a Y chromosome.

Management. After discussion and explanation, clitorrectomy was performed and the patient was started on oestrogen therapy.

Case A.M. (No. 18 in Table I) (Fig. 3). A coloured male aged 25 years was admitted to hospital with an 'acute abdomen', for which no cause was found.

The patient had a masculine build with short stature, height being 56 in. (142 cm.) lower segment 28 in (71 cm.), and span 55.5 in. (140 cm.). Hair distribution was male with temporal recession. He shaved frequently. He had numerous pigmented naevi, and his sclerae were deep blue. The fourth metacarpal of the left hand and the left foot were very short.

Examination of the external genitalia revealed a moderate-sized hypospadiac penis. A rugose scrotum was present with a testis on the right side which was clinically normal. Skeletal radiographs showed a gynae-coid pelvis. There was no evidence of osteoporosis. All epiphyses were fused.

Radiographs of the abdomen and intravenous pyelogram revealed kidney shape and function to be normal.

17-ketosteroids, 15.7 mg./24 hours; 17-OH-corticosteroids, 21.2 mg./24 hours; and urinary FSH, 48 mouse units/24 hours.

Laparotomy revealed a rudimentary uterus joining a

vagina which ended in a blind pouch. From the left cornu of the uterus a tube was seen leading to a white ridge of tissue resembling the streak of 'ovarian agenesis' (Fig. 4).

A vas deferens was seen on the right leading to the uterus. The vas was divided, and uterus, tube, and streak gonad were removed and biopsy taken from the right descended testes.

Histology. The right descended gonad showed features of normal testicular tissue with minimal spermatogenesis (Fig. 5). Histology of the streak gonad is unfortunately not available. Substance aspirated from the uterus was found to contain spermatozoa.

Cytogenetic studies. (Fig. 6 and 7, and Table III.) Buccal smear, chromatin negative; blood leucocytes, no drumsticks present.

TABLE III
CHROMOSOME ANALYSIS IN CASE A.M.

Tissue	No. of Chromosomes	
	45	46
Blood	5	13
Skin	10	16

Other tissues were cultured but the cultures became infected. The cells with 45 chromosomes had only 15 in the X-6-12 group and no Y, while those with 46 chromosomes contained a Y.

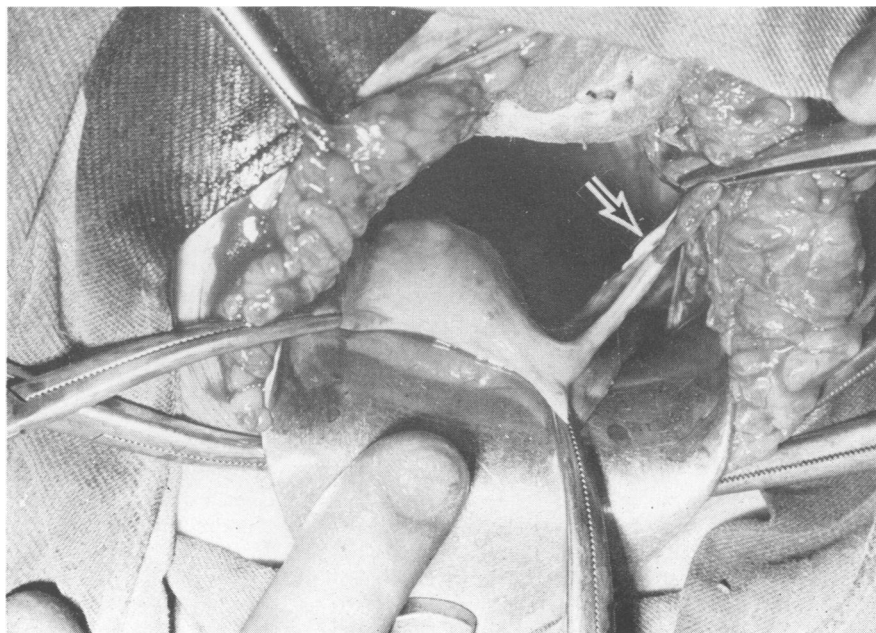


FIG. 4. A.M. Laparotomy showing uterus, left tube, and streak gonad (arrow).

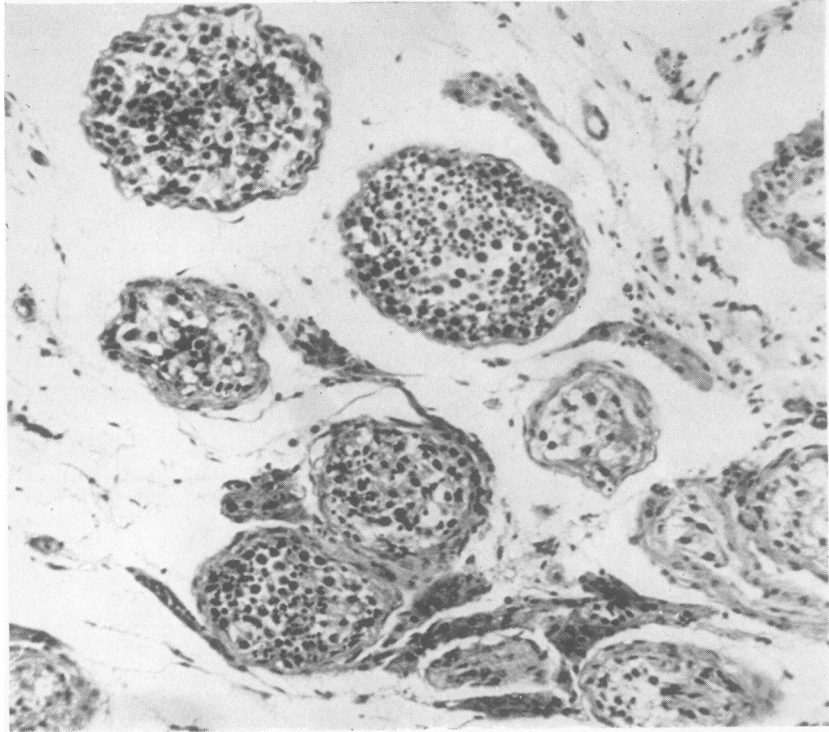


FIG. 5. A.M. Testicular tissue from biopsy specimen of descended gonad, showing scanty spermatogenesis. ($\times 100$.)

Comment

The findings of so many nuclei with only 43 chromosomes on the first blood culture in Case A.I. is not easily explained. In all instances three small chromosomes were missing, presumably the Y chromosome and two from pairs 19 and 20. The relative constancy of the abnormality and lack of any cells with 44 chromosomes suggest that the '43 cells' were not simply an artefact of the culture, though it is simplest to assume that this was the case.

If the XO/XY ratios are true reflections of the *in vivo* situation, then in these two cases there might well be a connexion between the proportion of cells with a Y chromosome and the degree of masculinity.

The degree of development of the single testis in the second case is remarkable; as far as we know this is the only example of a fully-descended sperm-producing testis yet found in this syndrome. The finding of spermatozoa in the patient's uterus is also unusual.

It is noteworthy that both patients showed certain features characteristic of Turner's syndrome apart

from the single 'streak gonad', in that both were short in stature and both had typical minor developmental anomalies.

A summary of the cases that we have found reported in recent literature is presented in Table I.

Discussion

Clinical Features. The clinical features of XO/XY chromosomal mosaics vary widely. The majority appear female, with vagina and uterus and without descended gonads. All of these show some degree of virilization, an enlarged clitoris being the most frequent indication. At puberty primary amenorrhoea is the rule, and breasts remain undeveloped. Sometimes the voice deepens and hair of male distribution appears. Many remain short in stature and some show other features suggestive of Turner's syndrome such as webbed neck, low hair-line, and cubitus valgus. Our own girl (No. 14) is short with cubitus valgus and shield-like chest, and the initial diagnosis was 'gonadal dysgenesis with large clitoris'. Eunuchoid proportions can also occur.

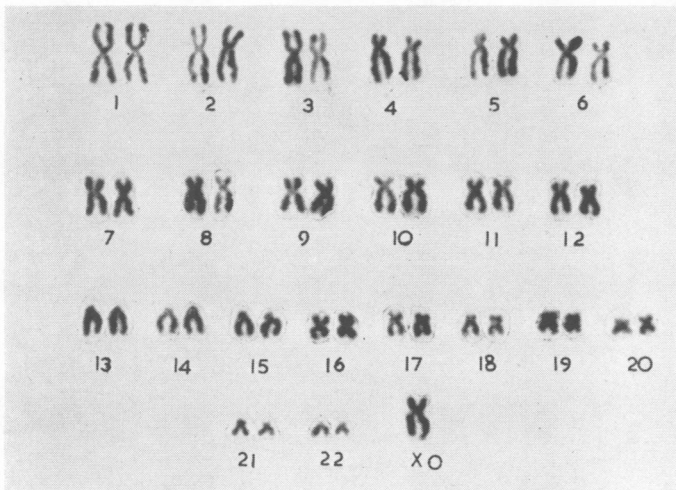
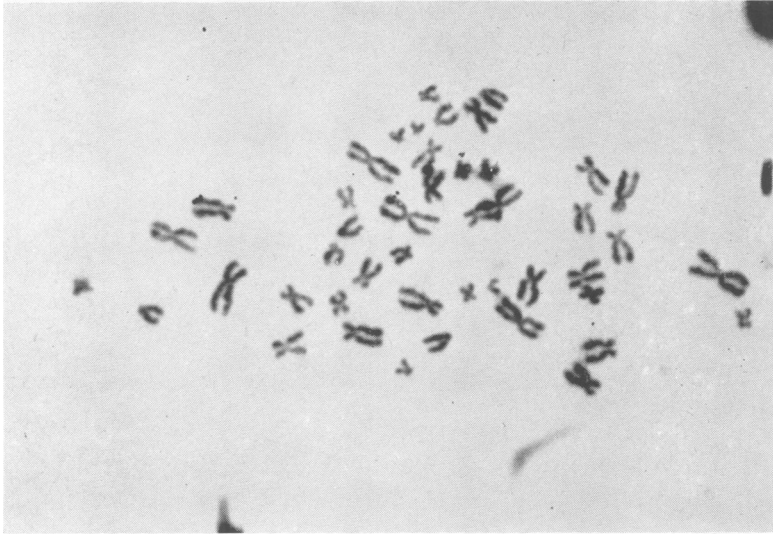


FIG. 6. Mitotic lymphocyte and karyotype of A.M., showing XO chromosome complement from blood culture.

The four subjects with male phenotype are masculine in body build (though may be short in stature), hairy, possess fair-sized phalluses, and three of them have one gonad in evidence in fused labio-scrotal folds. (One of the female-phenotype group also had a descended gonad—No. 13.) Our own patient (No. 18) possessed short metacarpal bones, many black moles, and deep blue sclerae, features that many be found in Turner's syndrome (Hoffenberg and Jackson, 1957).

Gonadal Features. The most characteristic gonadal pattern seems to be an immature testis on one side with Leydig cells and tubules but no spermatogenesis, and a fibrous streak on the other, which contains ovarian-type stroma and occasionally other primitive elements resembling rete testis or theca cells. Most of the gonads are in the primitive site, but some that contain tubular structures have descended into labioscrotal folds. More complete development has occasionally been

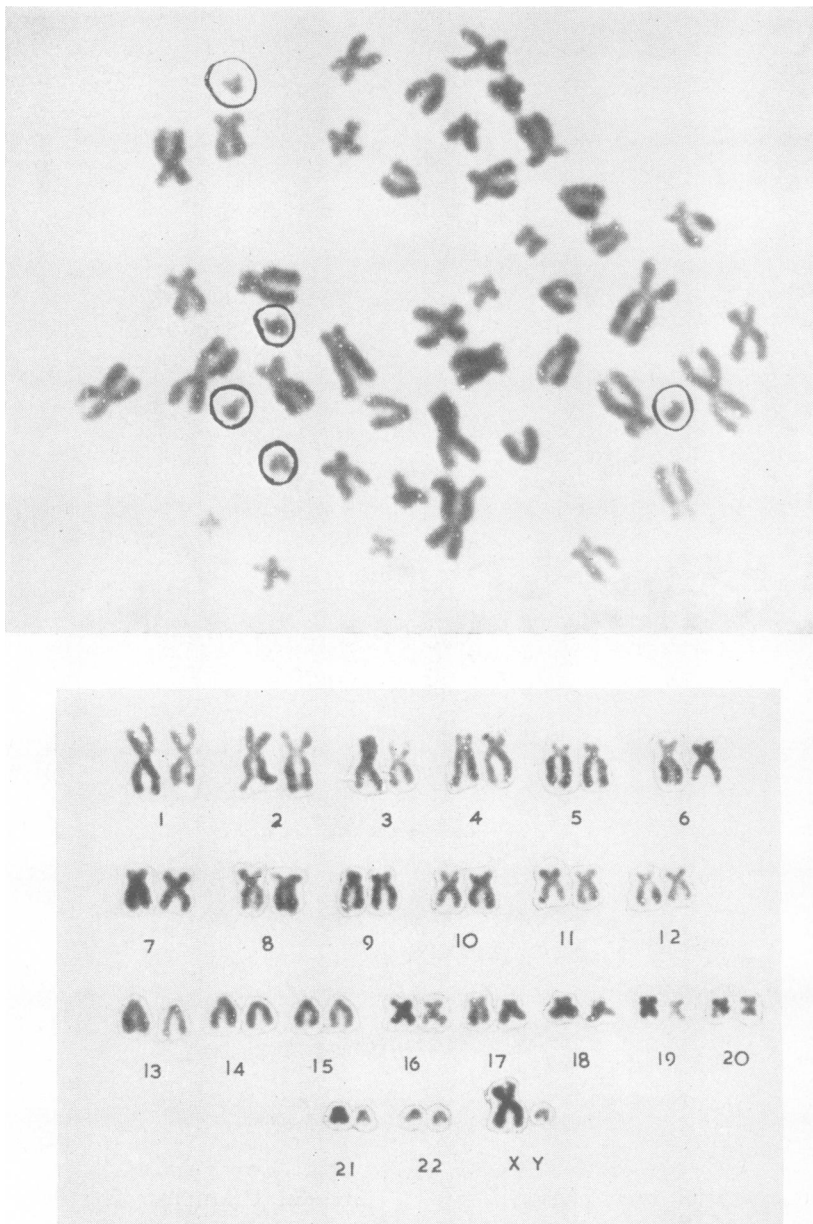


FIG. 7. Mitotic lymphocyte and karyotype of A.M., showing XY chromosome complement from blood culture. The five small acrocentric chromosomes, Y-21-22, are ringed.

seen in either direction however, with ovarian follicles on the one hand (No. 2 in Table I), and complete spermatogenesis, as in our case (No. 18), on the other. Further variants include: (1) one

ovotestis (No. 2), making this subject by definition a *true hermaphrodite*; (2) two cases (No. 3 and 4) with bilateral undifferentiated streak gonads, by definition '*gonadal dysgenesis*'; (3) three cases

(No. 7, 10, 16) with testicular tubular structures on both sides, by definition 'male (pseudo) hermaphrodite'; (4) in other cases only a single gonad could be found; (5) finally, there are three cases in which malignant neoplastic tissue was found in one gonad. As discussed by Sohval (1964) the exact origin of the neoplastic cells was difficult to determine.

Chromosomal Features. All patients are chromatin-negative and one or more of their tissues show 45XO/46XY mosaicism on culture. It may be presumed that the testicular structures are determined by the presence of the Y chromosome and that the degree of intrauterine masculinization follows from the degree of development of the foetal testis. Later pubertal virilization must depend upon the function of adult-type Leydig cells. Only in our own case, A.M., is complete spermatogenesis also present. Published data do not support the suggestion that the frequency of XY cells in cultures of the tissues sampled parallels the degrees of maleness in individual cases.

In Table I, seven cases are summarized, which appear closely related to the above-described syndrome, but do not possess precisely the XO/XY chromosomal pattern on culture (Conen, Bailey, Allemang, Thompson, and Ezrin, 1961; Schuster and Motulsky, 1962; Miles, Luzzatti, Storey, and Peterson, 1962; Bloise, de Assis, Bottura, and Ferrari, 1960; Ferguson-Smith and Johnston, 1960; Bottura and Ferrari, 1962; Atkins and Engel, 1962). In one 'typical' case (No. 22) the Y chromosome is ultra-small; in one there is triple mosaicism (XX/XO/XY) with chromatin bodies in some cells; in a third case there is a small 'X' in addition in the XY cells, and also bilateral testes. Four others are not apparent mosaics, being reported as 'XO' only. Nevertheless, in the three in which laparotomy was performed testicular tissue was found on one side. If it be accepted that the Y chromosome is necessary for the gonad to differentiate into a testis then it would seem a fair presumption that some XY cells are actually present but are either more difficult to grow in culture (as in our first case A.I.) or exist only in tissues that have not been cultivated.

Jost's theory (1953) that the foetal testis produces a male evocator substance which inhibits female genital duct differentiation and enhances male genital development is generally accepted. In subjects in whom the Y chromosome is not uniformly present the virilizing substance may not be sufficient in amount or activity completely to inhibit female Müllerian duct development and to provoke full male development. The proportion, distribution, or activity of the Y chromosome may

vary considerably, thus producing a very diverse group of sexual anomalies.

Relation to Turner's Syndrome (gonadal dysgenesis with female body form). The shortness of stature, combined with primary amenorrhoea and other evidence of lack of sexual development, together with minor congenital anomalies similar to those found in Turner's syndrome are striking. In most cases a 'streak' gonad on one side also resembles the gonads of XO Turner's syndrome. The explanation of the relation between shortness plus anomalies and XO gonadal dysgenesis is not clear, but plainly these same skeletal features are closely connected to the XO/XY constitution as well as to pure XO.

Summary

Two further cases of the XO/XY chromosome mosaic intersex syndrome are described, one with female phenotype, the other with male. The second patient was producing spermatozoa in his single descended testis.

Salient features of other cases in the literature are summarized, showing the wide diversity of manifestations of this syndrome. The frequency of shortness of stature and minor congenital anomalies indicates a close connexion with XO gonadal dysgenesis (Turner's syndrome). Some masculinization, however, always occurs, unlike ordinary XO gonadal dysgenesis, and presumably the variable activity of the Y chromosome accounts for the variable degree of male development.

We wish to thank Dr. R. Hoffenberg, who referred the patient A.M. to us, and Dr. P. Jacobs for their advice. Dr. C. Knott-Craig, Dr. S. Kaye, Dr. W. M. Roberts, and Dr. H. de Groot have been involved on the surgical side. We are indebted to Dr. L. B. Khan for the histological reports, and to Mr. B. Todt for the photographs. Dr. M. J. W. Faed of the Western General Infirmary, Glasgow, kindly provided the reports of skin cultures.

The costs of this work were defrayed in part by grants from The Wellcome Trust and by the South African Council for Scientific and Industrial Research to the Endocrine Research Group, of the University of Cape Town.

REFERENCES

- Appleby, J. I., Gibson, G., Norymberski, J. K., and Stubbs, R. D. (1955). The determination of 17-hydroxycorticosteroids. *Biochem. J.*, **60**, 453.
- Atkins, L., and Engel, E. (1962). Absence of the Y chromosome (XO sex-chromosome constitution) in a human intersex with an extra-abdominal testis. *Lancet*, **2**, 20.
- Blank, C. E., Bishop, A., and Caley, J. P. (1960). Example of XY/XO mosaicism. *ibid.*, **2**, 1450.
- Bloise, W., de Assis, L. M., Bottura, C., and Ferrari, I. (1960). Gonadal dysgenesis (Turner's syndrome) with male phenotype and XO chromosomal constitution. *ibid.*, **2**, 1059.

- Bloomberg, B. M., Alldis, D., Jankelowitz, R., and Wolmer, I. (1955). The diagnostic value of urinary gonadotropic hormone ('FSH') assays. *S. Afr. med. J.*, **29**, 225.
- Bottura, C., and Ferrari, I. (1962). Male pseudohermaphroditism with XO chromosomal constitution on bone-marrow cells. *Brit. med. J.*, **2**, 1100.
- Conen, P. E., Bailey, J. D., Allemang, W. H., Thompson, D. W., and Ezrin, C. (1961). A probable partial deletion of the Y chromosome in an intersex patient. *Lancet*, **2**, 294.
- Davidson, W. M., and Smith, D. R. (1954). A morphological sex difference in the polymorphonuclear neutrophil leucocytes. *Brit. med. J.*, **2**, 6.
- De la Chapelle, A., and Hortling, H. (1962). XY/XO mosaicism. *Lancet*, **2**, 783.
- Ferguson-Smith, M. A., and Johnston, A. W. (1960). Chromosome abnormalities in certain diseases of man. *Ann. intern. Med.*, **53**, 359.
- Ferrier, P., Ferrier, S., Klein, D., and Fernex, C. (1963). XY/XO mosaicism. *Lancet*, **1**, 54.
- , Gartner, S. M., Waxman, S. H., and Shepard, T. H., II (1962). Abnormal sexual development associated with sex chromosome mosaicism. Report of three cases. *Pediatrics*, **29**, 703.
- Greenblatt, R. B., Dominguez, H., Mashesh, V. B., and Demos, R. (1964). Gonadal dysgenesis intersex with XO/XY mosaicism. *J. Amer. med. Ass.*, **188**, 221.
- Harnden, D. G. (1960). A human skin culture technique used for cytological examinations. *Brit. J. exp. Path.*, **41**, 31.
- Hirschhorn, K., Decker, W. H., and Cooper, H. L. (1960). Human intersex with chromosome mosaicism of type XY/XO. *New Engl. J. Med.*, **263**, 1044.
- Hoffenberg, R., and Jackson, W. P. U. (1957). Gonadal dysgenesis: modern concepts. *Brit. med. J.*, **2**, 1457.
- Jacobs, P. A., Harnden, D. G., Buckton, K. E., Court Brown, W. M., King, M. J., McBride, J. A., MacGregor, T. N., and Maclean, N. (1961). Cytogenetic studies in urinary amenorrhoea. *Lancet*, **1**, 1183.
- Jost, A. (1953). Problems of fetal endocrinology: The gonadal and hypophyseal hormones. *Recent Progr. Hormone Res.*, **8**, 379.
- Judge, D. L. C., Thompson, J. S., Wilson, D. R., and Thompson, M. W. (1962). XY/XO mosaicism. *Lancet*, **2**, 407.
- Lewis, F. J. W., Mitchell, J. P., and Foss, G. L. (1963). XY/XO mosaicism. *ibid.*, **1**, 221.
- Mellman, W. J., Klevit, H. D., Yakovac, W. C., Moorhead, P. S., and Saksela, E. (1963). XO/XY chromosome mosaicism. *J. clin. Endocr.*, **23**, 1090.
- Miller, O. J. (1962). Sex determination: the sex chromosomes and the sex chromatin pattern. *Fertil. and Steril.*, **13**, 93.
- Miles, C. P., Luzzatti, L., Storey, S. D., and Peterson, C. D. (1962). A male pseudohermaphrodite with a probable XO/XxY mosaicism. *Lancet*, **2**, 455.
- Moorhead P. S., Nowell, P. C., Mellman, W. J., Battips, D. M., and Hungerford, D. A. (1960). Chromosome preparations of leukocytes cultured from human peripheral blood. *Exp. Cell Res.*, **20**, 613.
- Ross, A. (1960). The demonstration of sex chromatin in buccal smears. *J. med. Lab. Technol.*, **17**, 178.
- Schuster, J., and Motulsky, A. G. (1962). Exceptional sex-chromatin pattern in male pseudohermaphroditism with XX/XY/XO mosaicism. *Lancet*, **1**, 1074.
- Sohval, A. R. (1964). Hermaphroditism with 'atypical' or 'mixed' gonadal dysgenesis. Relationship to gonadal neoplasm. *Amer. J. Med.*, **36**, 281.
- Turner, H. H., Greenblatt, R. B., and Dominguez, H. (1963). Syndrome of gonadal dysgenesis and abdominal testis with an XO/XY chromosome mosaicism. *J. clin. Endocr.*, **23**, 709.
- Willemse, C. H., Van Brink, J. M., and Los, P. L. (1962). XY/XO mosaicism. *Lancet*, **1**, 488.

Addendum

Since this manuscript was written, among other cases of the XO/XY syndrome that have been published is one of a patient resembling the picture of a 'male Turner's syndrome' (Ross, Holland, Kiser, and Douglas, 1965). This 16-year-old boy was short in stature, had cubitus valgus, a short metacarpal and metatarsal, and a descended gonad. Biopsy disclosed an absence of spermatogenesis, however.

REFERENCE

- Ross, G. T., Holland, J. M., Kiser, W. S., and Douglas, G. W. (1965). XO/XY chromosomal mosaicism and extragenital stigmata of Turner's syndrome in a phenotypic male. *J. clin. Endocr.*, **25**, 141.