

with subsequent loss or absorption of one twin, remains a possibility. A comparison of the chromosome G-bands of the proposita and her mother was not informative in attempts to elucidate the mechanism involved by cytogenetic means.

A further possible explanation of chimaerism in haemopoietic tissue alone may be a fusion of the primitive circulations of two yolk sacs, since the yolk sac is one of the earliest sites of haemopoiesis (D. I. Rushton, personal communication).

We are indebted to many of our colleagues for expert advice; some are mentioned above. We also gratefully acknowledge the valuable help and advice of Pauline Mackintosh, Professor J. H. Edwards, Professor D. G. Harnden, Drs R. R. Race and Ruth Sanger, Dr A. H. Cameron, Dr I. D. O. Frew, and Dr J. Insley.

DIANA A. BATTEY, G. W. G. BIRD,
A. McDERMOTT, C. W. MORTIMER, O. M.
MUTCHINICK, and JUNE WINGHAM

*Regional Blood Transfusion Service, Birmingham,
the Good Hope General Hospital,
Sutton Coldfield,
and the Department of Human Genetics,
University of Birmingham*

REFERENCES

- Bird, G. W. G. (1951). Specific agglutinating activity for human red blood corpuscles in extracts of *Dolichos biflorus*. *Current Science*, **20**, 298-299.
- Booth, P. B., Plaut, G., James, J. D., Ikin, E. W., Moores, P., Sanger, R., and Race, R. R. (1957). Blood chimerism in a pair of twins. *British Medical Journal*, **1**, 1456-1458.
- Brendemoen, O. J. (1952). Some factors influencing Rh immunization during pregnancy. *Acta Pathologica et Microbiologica Scandinavica*, **31**, 579-583.
- Crookston, M. C., Tilley, C. A., and Crookston, J. H. (1970). Human blood chimaera with seeming breakdown of immune tolerance. *Lancet*, **2**, 1110-1112.
- Dunsford, I., Bowley, C. C., Hutchison, A. M., Thompson, J. S., Sanger, R., and Race, R. R. (1953). A human blood-group chimaera. *British Medical Journal*, **2**, 81.
- Ford, C. E. (1969). Mosaics and chimaeras. *British Medical Bulletin*, **25**, 104-109.
- Gartler, S. M., Waxman, S. H., and Giblett, E. R. (1962). An XX/XY human hermaphrodite resulting from double fertilization. *Proceedings of the National Academy of Sciences*, **48**, 332-335.
- Giblett, E. R. (1969). *Genetic Markers in Human Blood*. Blackwell Scientific, Oxford.
- Kaeser, A. and Nennstiel, H. J. (1971). Chimärismus vom Typ O/B in zwei neuentdeckten Fällen mit Differenz der Lewis-Gruppen und der Antigenstärken von H und P₁. *Blut*, **22**, 229-236.
- Race, R. R. and Sanger, R. (1968). *Blood Groups in Man*. Blackwell Scientific, Oxford.
- Race, R. R. and Sanger, R. (1972). Blood group mosaics. *Haematologia*, **6**, 63-71.
- Rosenfield, R. E., Haber, G. V., Kissmeyer-Nielsen, F., Jack, J. A., Sanger, R., and Race, R. R. (1960). Ge, a very common red cell antigen. *British Journal of Haematology*, **6**, 344-349.
- Uchida, I. A., Wang, H. C., and Ray, M. (1964). Dizygotic twins with XX/XY chimerism. *Nature*, **204**, 191.

Inherited partial duplication of chromosome No. 15*

Summary. A boy with unusual facial appearance and mental retardation was found to have duplication for the distal half of the long arm of chromosome No. 15 and possibly deficiency for the distal end of the long arm of No. 21. The chromosome abnormality was inherited from his mother, who had a translocation involving chromosomes Nos. 15 and 21. Giemsa-banding localized the break point in chromosome No. 15 just distal to the intense band at the midportion of the long arm. The break point in chromosome No. 21 appeared to be at the distal end of the long arm. The difficulty encountered in cytogenetic analysis of the propositus with conventional staining, the importance of chromosome analysis of the parents, and the application of differential staining techniques are also presented.

There are five reported cases in which partial trisomy of chromosome No. 15 has been diagnosed (Magenis *et al*, 1972; Parker and Alfi, 1972; Bucher *et al*, 1973; Crandall, Muller, and Bass, 1973). Using differential staining techniques, these authors interpreted the extra G-like chromosome as a partially deleted chromosome No. 15 and, therefore, the patient was trisomic for the proximal portion of chromosome No. 15.

This present case is a child with confirmed partial duplication of the distal half of the long arm of chromosome No. 15 and probable deficiency for the distal end of the long arm of chromosome No. 21. This duplication-deficiency abnormality is the result of an unbalanced segregation product inherited from his mother, who is a balanced translocation carrier.

Case history

This 2980 g male infant was born at term to a 30-year-old gravida V, para II, ab II, Spanish-American woman. The mother took 120 mg of Armour Thyroid tablet^(R) (animal thyroid extract) daily for hypothyroidism since the age of 18. During the fourth month of this pregnancy she had painless vaginal bleeding.

Received 19 November 1973.

* This study was supported in part by Grant No. 286 from Maternal and Child Health Service, United States Public Health Service.

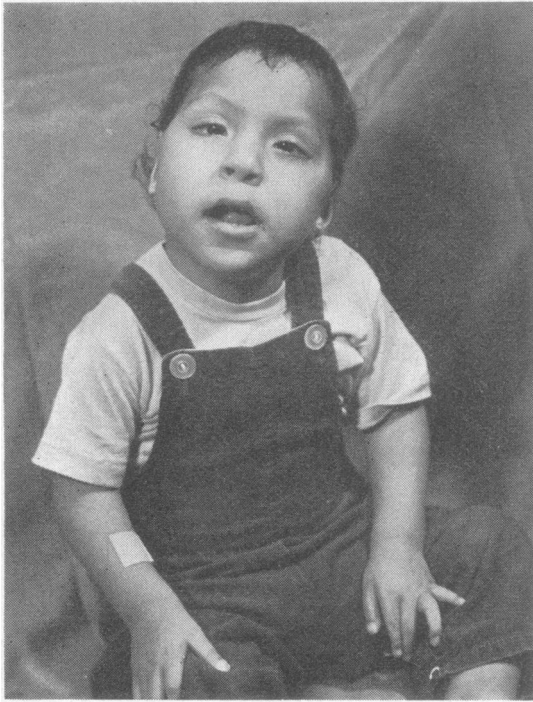

FIG. 1. Propositus. Note asymmetric face and antimongoloid palpebral fissures.




FIG. 2. Propositus. Note low set ear and micrognathia.

At birth the infant was apnoeic and required resuscitation. He was noted to have microcephaly with prominent occiput, asymmetric face, antimongoloid palpebral fissures, low set ears with poorly formed helices, micrognathia, long tapering fingers, and narrow feet with a deep crease between the first and second toes bilaterally. He remained in the nursery for two months because of respiratory distress.

He was subsequently hospitalized several times for respiratory difficulty which was thought to be secondary to oesophageal dysfunction and poor handling of secretions. Laryngoscopy did not reveal any specific lesion. Cardiac catheterization at the age of 8 months was normal. Sweat chloride was 36 mEq/l on two occasions (normal). Serum and urine amino-acid levels were normal and no reducing sugar was found in the urine.

At age 10 months he had a grand mal seizure with fever. The electroencephalogram was grossly abnormal and showed frequent seizure activity in the left central-temporal region. He was treated with phenobarbital and was seizure-free until 3 years of age when he developed petit mal. Zarontin^(R) (ethosuximide) was added to his medications. Examination at this time showed central cataracts, esotropia and moderate hearing loss. At age 2 years 8 months his development was less than one year of age. At age 3 years 6 months he still does not walk or talk.

Cytogenetic studies

The child's initial chromosome analysis, prepared at another laboratory with conventional staining, was interpreted as 46,XY normal male karyotype. Two years later the child was re-evaluated because of the moderate developmental retardation and unusual facial appearance (Figs. 1 and 2). This time chromosome analyses were obtained from the parents. The karyotype of the father was 46,XY while that of the mother showed 46,XX,Dq-,Gq+ (Fig. 3). Chromosome analyses (blood and skin) from the propositus demonstrated 46,XY,Gq+ (Fig. 3). The marker Gq+ was an atypical acrocentric, longer than a G-group chromosome but shorter than a D-group chromosome. This chromosome had been miskaryotyped in the previous study as a long Y chromosome. The error was readily apparent when the father's Y chromosome was shown to be the size of a G-group chromosome.

Giemsa-banding demonstrated that the mother had a translocation between the long arms of Nos. 15 and 21 (Fig. 4). The break point in the long arm of No. 15 was just distal to the heavily stained band at the midportion while the break in the long arm of No. 21 was apparently near the distal end. The larger atypical acrocentric had the centromere of No. 21 while the smaller, which was the size of a G group chromosome, had the centromere of No. 15. The Giemsa-banding pattern of the karyotype from

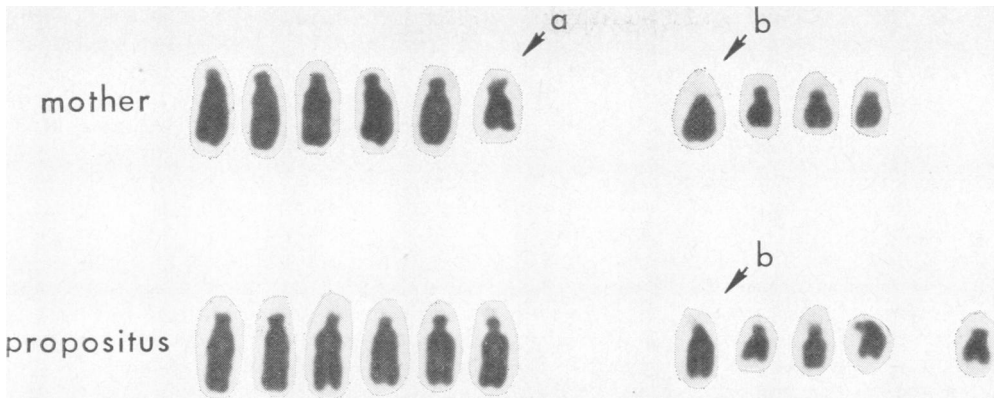

FIG. 3. Partial karyotypes of D- and G-group chromosomes from the mother and the propositus using conventional staining. Arrow a indicates a Dq- chromosome while arrow b indicates Gq+ chromosome. In the propositus the Gq+ chromosome was initially mis-karyotyped as a long Y chromosome.

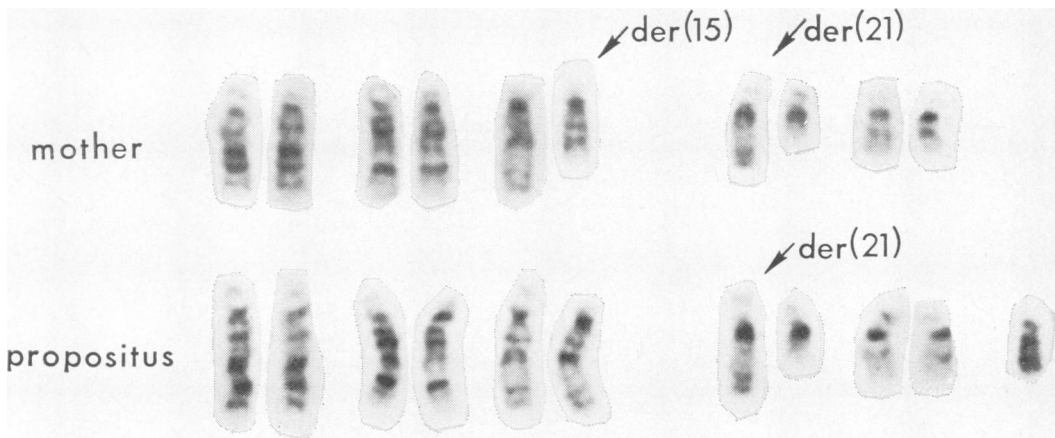


FIG. 4. Partial karyotypes using trypsin-Giemsa banding from the mother and the propositus. The arrows indicate the abnormal chromosomes derived from the translocation between chromosomes Nos. 15 and 21.

the propositus showed 46,XY,21q+ (Fig. 4). This karyotype was interpreted as an unbalanced translocation. The distal half of the long arm of No. 15, which was clearly translocated to the long arm of No. 21, was present in duplication, and a portion of the long arm of chromosome No. 21 was presumably deleted. According to current nomenclature recommended by the Paris Conference (1971), the mother's karyotype was 46,XX,t(15;21)(q22;q22), while that of the propositus was 46,XX,-21,der(21),t(15;21)(q22;q22)mat.

Family studies

Chromosome analyses were obtained from the two normal sibs, two maternal uncles, two maternal

aunts, the maternal grandmother, and two maternal great aunts who were sisters of the deceased maternal grandfather. All showed normal karyotypes. A paternal first cousin was reported to have mental retardation and cerebral palsy not associated with congenital anomalies. He was not available for study.

Dermatoglyphic studies

Dermatoglyphs were obtained from the propositus and his parents. The mother had a slightly increased ridge count (total count 164), while the father's dermatoglyphs were unremarkable. The propositus had a low digital ridge count (total count 47), an increase in digital arches, mildly elevated

axial triradii (33.6% on right and 28% on left), and tibial loops in the hallucal area. These patterns are often seen in trisomy D (Penrose, 1966).

Discussion

Presumptive partial trisomy of chromosome No. 15 has been described by several authors (Magenis *et al.*, 1972; Parker and Alfi, 1972; Bucher *et al.*, 1973; Crandall *et al.*, 1973). In each case the karyotype showed 47 chromosomes with an extra G-like chromosome which was interpreted by quinacrine fluorescence or Giemsa banding as a derivative of chromosome No. 15. The trisomic portions appeared to be the short arm and proximal portion of the long arm of chromosome No. 15. All the patients described had moderate to severe mental retardation and some had strabismus, antimongoloid slants, epicanthi and seizure disorder. The authors felt that none of these features was specific enough to clinically identify individuals with this chromosome disorder.

In contrast to the above cases, our patient appears to have duplication of the distal half of the long arm of chromosome No. 15. He has mental retardation (DQ less than 40), strabismus, central cataracts, and seizures. In addition he has microcephaly, asymmetric face with antimongoloid slants, low set ears, micrognathia, long tapering fingers, abnormal dermatoglyphs, and moderate hearing loss. Since a different portion of chromosome No. 15 is duplicated in our patient, a different phenotype may be expected. Moderate mental retardation is the most consistent finding in these patients. The unusual physical features in our patient may be due to the duplication of the distal half of the long arm of chromosome No. 15, the deletion of a small distal segment of the long arm of chromosome No. 21, or the combination of duplication-deficiency disorder.

The karyotype of the proband was initially misdiagnosed as normal. The error was due to the mistaken identification of the Y as a G chromosome and the derivative chromosome as a 'long Y'. Subsequently, the abnormality was discovered through cytogenetic analyses of the parents and defined with the use of more specific differential staining techniques.

It is of interest to note that the partial duplication in our patient occurred as an unbalanced product from his balanced carrier mother. Chromosome No. 15 has rarely been implicated in familial aneuploidy or structural rearrangement. There are two reports of pericentric inversion presumably involving chromosome No. 15 (Cohen, Capraro, and Takagi, 1966/1967; Crandall and Sparkes, 1970), but no

individual was identified as an unbalanced product of the inversion. In another family with a translocation involving chromosomes Nos. 1 and 15, two individuals with gross mental and physical disability had unbalanced products (Prescott, 1973). The cytogenetic abnormality involved in this family, however, was a partial deletion of chromosome No. 15 rather than a duplication.

The translocation of the distal portion of chromosome No. 15 to No. 21 found in the present case can result from reciprocal translocation or insertion. If a reciprocal translocation, the proband has a duplication-deficiency syndrome involving chromosomes Nos. 15 and 21, while in a case of direct insertion between No. 15 and No. 21, the patient represents only a duplication for the distal half of the long arm of chromosome No. 15. Although it is not possible to distinguish reciprocal translocation from direct insertion by the available cytogenetic data, the presence of an apparently intact distal half of chromosome No. 15 in the derivative chromosome from No. 21 suggests that reciprocal translocation is more likely.

From a balanced reciprocal translocation-heterozygote, six gametes are the possible segregation products, if we assume no crossovers between the centromeres and the points of interchange. The abnormality observed in this patient is a result of adjacent-1 disjunction. The other gamete resulting from adjacent-1 disjunction would likewise be unbalanced, representing a partial duplication of No. 21, and a deficiency of No. 15. Segregation products from adjacent-2 disjunction would likewise be unbalanced and perhaps non-viable because of the large segment of either No. 15 or 21 (with respective centromere) which would be missing.

Should this couple decide to have amniocentesis in future pregnancies, it will be important to use differential staining, because the zygotes resulting from maternal non-disjunction at adjacent-1 and -2 may not be morphologically diagnosable.

The authors wish to thank Mr Paul Brager, Mrs Talma Dawson, Mrs Fay Kaplan, and Mr Paul Nazarian for technical assistance.

ATSUKO FUJIMOTO, JOSEPH W. TOWNER,
ALLAN J. EBBIN, EMILY J. KAHLSTROM, and
MIRIAM G. WILSON

*Genetics Division, Department of Pediatrics,
University of Southern California School of
Medicine and Los Angeles County-University of
Southern California Medical Center, Los Angeles,
California 90033, USA*

REFERENCES

- Bucher, W., Parker, C. E., Crandall, B., and Alfi, O. S. (1973). Partial trisomy of chromosome 15. *Lancet*, **1**, 1250.
- Cohen, M. M., Capraro, V. J., and Takagi, N. (1966/1967). Pericentric inversion in a group D chromosome (13-15) associated with amenorrhoea and gonadal dysgenesis. *Annals of Human Genetics*, **30**, 313-323.
- Crandall, B. F., Muller, H. M., and Bass, H. N. (1973). Partial trisomy of chromosome number 15 identified by trypsin-Giemsa banding. *American Journal of Mental Deficiency*, **77**, 571-578.
- Crandall, B. F. and Sparkes, R. S. (1970). Pericentric inversion of a number 15 chromosome in nine members of one family. *Cytogenetics*, **9**, 307-316.
- Magenis, R. E., Overton, K. M., Reiss, J. A., Macfarlane, J. P., and Hecht, F. (1972). Partial trisomy 15. *Lancet*, **2**, 1365-1366.
- Paris Conference (1971). Standardization in human cytogenetics. *Birth Defects: Original Article Series*, **8**, No. 7, 1972. National Foundation-March of Dimes, New York.
- Parker, C. E. and Alfi, O. S. (1972). Partial trisomy of chromosome 15. *Lancet*, **1**, 1073.
- Penrose, L. S. (1966). Dermatoglyphic patterns in large acrocentric trisomy. *Journal of Mental Deficiency Research*, **10**, 1-17.
- Prescott, G. H., McCaw, B., and Hecht, F. (1972). A hereditary A/D translocation. In *Program and Abstracts, American Society of Human Genetics*, page 63a.

Multiple congenital defects associated with trisomy for the short arm of chromosome 4

Summary. The clinical and cytogenetic findings of a female infant with multiple congenital anomalies and trisomy for the short arm of chromosome 4 (46,XX,21p+) are described. The abnormal chromosome was inherited from the father who had a balanced translocation between the short arm of chromosome 4 and the short arm of chromosome 21. Clinical features are compared with those of one definite and one probable previously described case of trisomy for the short arm of chromosome 4. It is suggested that a clinical syndrome associated with +4p eventually may be identified.

Cases of trisomy for the short arm of a B-group chromosome have been described previously. In

several instances the chromosome involved was identified as a No. 5 by Lejeune *et al* (1965), Laurent and Robert (1966), de Capoa *et al* (1967), and Noel, Quack, and Thiriet (1968). These patients had no severe physical abnormalities, but they were all mentally retarded. Schinzel and Schmid (1972) described a patient who was trisomic for the short arm of No. 4, and Gustavson *et al* (1964) described a patient with trisomy for the short arm of an unidentified B-group chromosome; both cases had severe physical anomalies. We present a further case of trisomy for the short arm of chromosome 4.

Case report

The proposita, a female, was born to a 24-year-old woman and her 27-year-old husband. The mother's only previous pregnancy, three years before, was complicated by hypertension and had terminated in the birth of a stillborn male (1600 g); no necropsy was performed.

Following a threatened abortion at the end of the first trimester, the pregnancy was uneventful and terminated spontaneously at 39 weeks in the birth of a female infant (1700 g). The 1 minute Apgar score was 5 and rose to 9 after 10 minutes. Routine examination revealed 'unusual' facies, respiratory distress, and an imperforate anus. On transfer to the Sheffield Children's Hospital the infant was found to be cyanosed and hypothermic (35° C).

The abnormal facies (Fig. 1a) were characterized by narrow palpebral fissures, bilateral microphthalmia, and a bulbous nose with a depressed root. The palpebral fissures had a slight antimongoloid slant and microphthalmia was more severe on the right. The philtrum was long and the upper lip protruded. The neck was short and the hair line low. The ears were moderately low set but, apart from a small nodule below the antitragus on the left, appeared to be of normal morphology. Mild micrognathia was present; the buccal cavity was small with a short thick tongue and there was an intact, high arched palate. Neither microcephaly nor hypertelorism were observed but measurements relevant to these features were not recorded.

The fingers were held tightly flexed but could be extended. At rest the index finger usually overlapped the thumb while the third and the fifth digits often overlapped the ring finger. Both hips were in marked flexion and adduction and could neither be extended nor abducted. There was bilateral postural valgus deformity of the feet but they were not rockerbottomed.

Normal female genitalia were found but no anus was seen. Meconium appeared through a pin hole orifice in the midline of the perineum between the vaginal introitus and the normal anal position.

Apart from a soft ejection systolic murmur at the left sternal edge, the further systemic examination was unremarkable.

Radiology of the chest revealed cardiomegaly and oligæmic lung fields. Films of the hip joints and pelvis