

## REFERENCES

- Baccichetti, C. and Tenconi, R. (1973). A new case of trisomy for the short arm of No. 9 chromosome. *Journal of Medical Genetics*, **10**, 296-299.
- Cantu, J. M., Buentello, L., and Armendares, S. (1971). Trisomie Cp: un nouveau syndrome. *Annales de Génétique*, **14**, 177-186.
- Hoehn, H., Engel, W., and Reinwein, H. (1971). Presumed trisomy for the short arm of chromosome No. 9 not due to inherited translocation. *Humangenetik*, **12**, 175-181.
- Rethoré, M. O., Hoehn, H., Rott, H. D., Couturier, J., Dutrillaux, B., and Lejeune, J. (1973). Analyse de la trisomie 9p par dénaturation ménagée. A propos d'un nouveau cas. *Humangenetik*, **18**, 129-138.
- Rethoré, M. O., Larget-Piet, L., Abonyi, D., Boeswillwald, M., Berger, R., Carpentier, S., Cruveiller, J., Dutrillaux, B., Lafourcade, J., Penneau, M., and Lejeune, J. (1971). Sur quatre cas de trisomie pour le bras court du chromosome 9. Individualisation d'une nouvelle entité morbide. *Annales de Génétique*, **13**, 217-232.
- Rott, H. D., Schwanzitz, G., and Grosse, K. P. (1971). Partielle Trisomie Cq bei balancierter B4/C9-Translokation bei der Mutter. *Zeitschrift für Kinderheilkunde*, **109**, 293-299.

## Case report

This was the first child of young parents, the mother being 26 years and the father 29 years. The mother had not had any previous miscarriages. The only drug taken during pregnancy was ferrous sulphate and she had not had any irradiation. Polyhydramnios was not recorded during the pregnancy. Oestriol levels were monitored from the 29th week of gestation because of small fetal size for period of gestation. The levels were below normal until the 34th week when the level was just within the normal range. Spontaneous premature labour occurred at 35½ weeks. Delivery was uneventful and the baby's Apgar was 4 at 1 min and 8 at 4 min. Birth weight was 1700 g. The umbilical cord had one artery and one vein. The placenta weighed 370 g. and was described as 'healthy'.

The baby had many of the characteristic features of trisomy 18 syndrome. The facial features were typical, including a prominent nose, depressed nasal bridge, and small palpebral fissures. There were no other ocular abnormalities. The mouth was small, the hard palate narrow and high-arched, and the soft palate cleft. The mandible was small and receding, and the auricles low-set and malformed. The occiput was prominent and hair sparse. Other abnormalities included hypertonicity with limited hip abduction, little subcutaneous tissue and loose folds of skin. The sternum was short and the nipples hypoplastic. The hands were clenched with the index overlying the third finger and the fifth finger overlying the fourth. The distal creases on the fifth fingers were absent; simian creases were not present. The feet showed the typical 'rockerbottom' deformity. Both the finger and toe nails were hypoplastic; the big toe short and dorsiflexed. The heart sounds were normal and there were no murmurs. Liver, spleen, and kidneys were not palpable abdominally. There were very large bilateral inguinal herniae which, when reduced, allowed palpation of a gonad in each hernial sac. The external genitalia appeared to be those of a female with clitoral hypertrophy, and only one orifice in the vestibule. No uterus could be palpated on rectal examination.

Under anaesthesia a more detailed examination of the genitalia was carried out. The perineal orifice was located between two poorly formed labia minora and behind a hypertrophied clitoris (Fig. 1a). A probe was inserted in the orifice and two tubular structures were entered close to the opening. Urethroscopy showed the anterior structure to be a normal calibre urethra with no verumontanum. The posterior tubular structure, thought to represent a vagina, ended blindly, no cervix being visible. Contrast medium injected into the perineal orifice delineated the urethra and bladder, and demonstrated bilateral ureteric reflux; the ureters being moderately dilated. There was simultaneous filling of a blind cavity extending parallel and posterior to the urethra, to the base of the bladder (Fig. 1b). Bilateral inguinal herniorrhaphy and removal of the gonads was performed. A small midline abdominal incision was performed to examine the pelvic structures. Palpation failed to reveal uterus or ovaries. Histological examina-

## Pseudohermaphroditism with clinical features of trisomy 18 in an infant trisomic for parts of chromosomes 16 and 18: 47,XY,der(18),t(16;18)(p12;q11)mat

**Summary.** The case is presented of an infant who was diagnosed clinically as trisomy 18 with pseudohermaphroditism. Cytogenetic studies revealed an extra chromosome which represented a translocation chromosome derived from a balanced, reciprocal translocation between chromosomes 16 and 18: [der(18),t(16;18)(p12;q11)mat]. The infant's mother and a number of her relatives were found to be translocation carriers: [46,XX,t(16;18)(p12;q11)].

The trisomy 18 syndrome has a number of typical clinical features. Many organs are affected with a varying degree of frequency; the abnormalities have however been fairly constant in large series of cases (Warkany *et al*, 1966). A number of genital abnormalities have been described, but to our knowledge no case of pseudohermaphroditism has been previously described, nor can we find any previous reports of the trisomic chromosome being a translocation chromosome involving chromosomes 16 and 18.

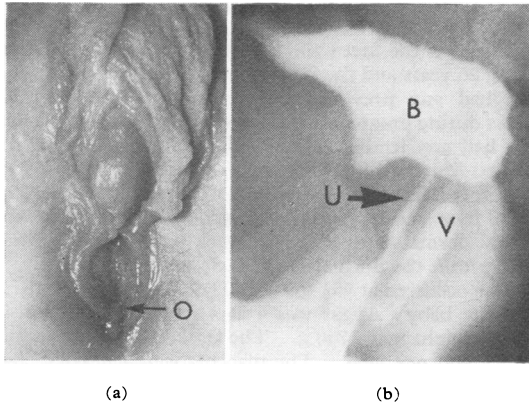


FIG. 1. (a) Detail of the infant's external genitalia, showing the hypertrophied clitoris and single perineal orifice (O). (b) Contrast injection demonstrating the urethra (U), bladder (B), and 'vagina' (V).

tion of the gonads showed normal prepubertal testes. The child is now 3 years old, microcephalic, spastic, and grossly retarded.

**Investigations**

Complete blood count, microurine, urinary 17-ketosteroids, 17-hydroxycorticoids, 11-oxygenation index, and ECG were all normal. Dermatoglyphics showed five loops, three whorls, and two arches. EEG showed a moderate degree of non-specific cerebral dysrhythmia of a non-focal type. Radiological examination showed hypoplasia of the bodies of the third, fourth, and fifth cervical vertebrae with mild kyphosis. Both first ribs were short. Rhesus genotypes of the baby, its parents and maternal grandfather are shown in the Table.

**Cytogenetic studies**

Buccal smears, stained with cresyl violet acetate,

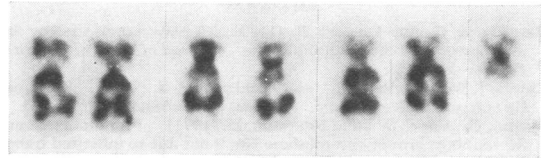


FIG. 2. Giemsa-banding of the E-group chromosomes and the extra small metacentric chromosome of the proband.

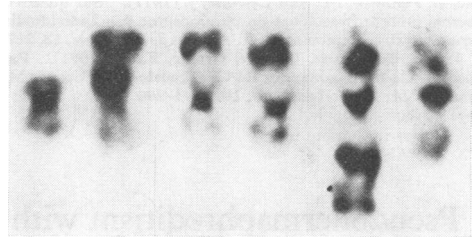


FIG. 3. Giemsa-banding of the E-group chromosomes of the mother showing the balanced reciprocal translocation.

were sex chromatin negative. Karyotypes were performed on the infant, the parents and the available maternal relatives. Blood cultures were performed on peripheral leucocytes using a modification of the method of Moorhead *et al* (1960). G-bands were produced using a trypsin technique modified from Seabright (1971). The father's karyotype was normal. All the infant's cells examined revealed a male karyotype with 47 chromosomes, the extra chromosome being a metacentric, smaller than a G-group chromosome. G-banding showed the metacentric chromosome to have a dark staining centromere with symmetrically light staining arms (Fig. 2). The mother's karyotype showed an

TABLE  
RHESUS GENOTYPES

Subject	ABO	MNs	P <sub>1</sub>	Rhesus		Lewis
II.5	O	MNSs	P <sub>1</sub> +	cCDee	C <sup>w</sup> -	Le(a-b+)
III.8	O	MNss	P <sub>1</sub> -	ccDee	C <sup>w</sup> -	Le(a+b+)
III.7	O	MNss	P <sub>1</sub> +	ccDee	C <sup>w</sup> -	Le(a-b-)
IV.4	O	MNss	P <sub>1</sub> -	ccDee	C <sup>w</sup> -	Le(a+b-)

Kell	Lutheran	Duffy	Kidd	Wright	HLA
K-,Kp(a-b+)	Lu(a-b+)	Fy(a+b+)	Jk(a-b+)	Wr <sup>a</sup> -	A2, A12, 4A/A2, (W15), 4b
K-,Kp(a-b+)	Lu(a-b+)	Fy(a+b+)	Jk(a+b+)	Wr <sup>a</sup> -	A9, A7, 4b/A2, (W15), 4b
K+,Kp(a-b+)	Lu(a-b+)	Fy(a-b+)	Jk(a+b+)	Wr <sup>a</sup> -	A2, (A12), 4A/A10, A17, 4A
K-,Kp(a-b+)	Lu(a-b+)	Fy(a-b+)	Jk(a+b+)	Wr <sup>a</sup> -	A2, (A12), 4A/A2, (W15), 4b

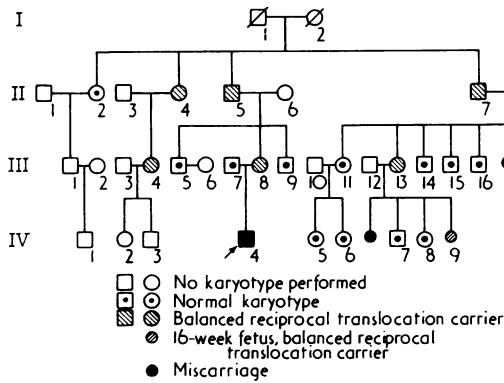


FIG. 4. Pedigree.

identical metacentric chromosome replacing one of the number 18 chromosomes. One of the number 16 chromosomes was replaced by a chromosome resembling a C-group chromosome (Fig. 3). Centromere banding was performed on the mother to further delineate the break points of the translocation chromosomes. This showed the break points to be above the centromere of chromosome 16 and below the centromere of chromosome 18. The maternal relatives who had a similar karyotype are shown in the pedigree (Fig. 4). Amniocentesis was carried out on IV.9, at 16 weeks' gestation; culture of the amniotic cells showed the fetus to be a female with the same karyotype as her mother.

### Discussion

The clinical abnormalities in this infant are those usually found in trisomy 18 syndrome (Warkany *et al*, 1966) except for the fact that the dermatoglyphics are not the classical low arch dermal ridge pattern on six or more fingers as described by Uchida *et al* (1961).

Genital abnormalities in trisomy 18 are much less common than other system anomalies. Warkany *et al* (1966) in a review of 84 necropsies found a total of 18 genital abnormalities, compared with 58 reported urological abnormalities and an even higher

number of cardiac malformations. Smith (1969) lists the genital abnormalities in trisomy 18, and describes most of them as only occasional features of the syndrome. Neither author mentions pseudohermaphroditism in his review.

The cytogenetic studies in this case show that the infant's mother and some of her relatives have a balanced reciprocal translocation involving chromosomes 16 and 18. C- and G-banding shows the probable break points to be at 16p12 and 18q11 (Fig. 3) making her karyotype: 46,XX,t(16;18)(p12;q11). The small extra metacentric chromosome in the proband would then be: der(18), t(16;18)(p12;q11)mat.

It is interesting to speculate that the pseudohermaphroditism in our case could have been caused by an associated incomplete testicular feminizing syndrome which it closely resembles. In a review of hormonal and clinical aspects of hermaphroditism and the testicular feminizing syndrome, Polani (1970) attributes the cause to target-organ resistance with inability of the target organs to convert testosterone to dihydrotestosterone during fetal development. It does seem more likely however that the chromosomal anomaly in this case caused pseudohermaphroditism; this appears to be unique.

L. M. STERN and A. R. MURCH

Adelaide Children's Hospital, Adelaide, South Australia

### REFERENCES

- Moorhead, P. S., Nowell, P. C., Mellman, W. J., Battips, D. M., and Hungerford, D. A. (1960). Chromosome preparations of leucocytes cultured from human peripheral blood. *Experimental Cell Research*, **20**, 613-616.
- Polani, P. E. (1970). Hormonal and clinical aspects of hermaphroditism and the testicular feminizing syndrome in man. *Philosophical Transactions of the Royal Society of London. Series B*, **259**, 187-204.
- Seabright, M. (1971). A rapid banding technique for human chromosomes. *Lancet*, **2**, 971-972.
- Smith, D. W. (1969). In *Endocrine and Genetic Diseases of Childhood*, ed. by L. I. Gardner, pp. 638-645. W. B. Saunders: Philadelphia.
- Uchida, I. A., Patau, K., and Smith, D. W. (1961). The dermal patterns of the new autosomal trisomy syndromes. *American Journal of Diseases of Children*, **102**, 588.
- Warkany, J., Passarge, E., and Smith, L. B. (1966). Congenital malformations in autosomal trisomy syndromes. *American Journal of Diseases of Children*, **112**, 502-517.