

- Penchazadeh, V. and Teasdale, R. D. (1971). Oculopharyngeal muscular dystrophy. *Birth Defects, Original Article Series*, Vol. 7, pt. 2, p. 118. National Foundation—March of Dimes, New York.
- Schotland, D. L. and Rowland, L. P. (1964). Muscular dystrophy, features of ocular myopathy, distal myopathy and myotonic dystrophy. *Archives of Neurology*, 10, 433–445.
- Szobor, A. (1973). Data on the oculopharyngeal syndrome, a clinicopathological study. *European Neurology*, 9, 242–259.
- Teasdale, R. D., Schuster, M. M., and Walsh, F. B. (1964). Sphincter involvement in ocular myopathy. *Archives of Neurology*, 10, 446–448.
- Victor, M., Hayes, R., and Adams, R. D. (1962). Oculopharyngeal muscular dystrophy, a familial disease of late life characterized by dysphagia and progressive ptosis of the eyelids. *New England Journal of Medicine*, 267, 1267–1272.

Partial trisomy for the long arms of chromosome No. 5 due to insertion and further 'aneusomie de recombinaison'

Summary. Five members of a family with a balanced insertion (1;5)(q32;q11q22) are presented. The daughter of one of them shows multiple malformations and a partial trisomy for the long arms of chromosome No. 5 (5q11 to 5q22 segment) resulting from a 'aneusomie de recombinaison' in her mother. The propositus' karyotype is 46,XX,rec(1;5)ins(1;5)(q32;q11q22). This case is the first reported example of an insertion between two chromosomes followed by 'aneusomie de recombinaison'. It also is the first reported case of trisomy involving the long arms of chromosome No. 5.

Exchanges of genetic material between two chromosomes may be due to reciprocal translocations or to insertions. Most of them are of the first type and many studies using the more accurate fluorescence or denaturation techniques have been reported. Such disorders may cause trisomy or partial monosomy in the offspring of the balanced individuals by an incorrect disjunction of the involved chromosomes at meiosis. Insertions seem rarer still and, as they lead to the formation of a loop during meiosis, a crossing-over in this loop may result in a genetic imbalance, the so-called 'aneusomie de recombinaison' (Lejeune and Berger, 1965).

Very few cases of 'aneusomie de recombinaison' have been published. Some of them have not been

investigated by the banding techniques. They are likely to be found, however, where identical chromosome structural anomalies occur in two individuals of the same family, but only one shows clinical symptoms, or where new types of aberration occur in the offspring, apparently due to a balanced rearrangement (insertion or pericentric inversion) in one of the parents, and where such chromosomes are unexplained by the usual mechanisms of chromosome disjunction (Grouchy and Gabilan, 1965; Lejeune and Berger, 1965; Grouchy *et al*, 1966; Hoehn *et al*, 1971; Cantu, 1972; Neu and Gardner, 1972). Other cases have been ascertained positively by analysis of the banding patterns (Caspersson *et al*, 1971; Boué and Boué, 1973; Dutrillaux *et al*, 1973; Taysi *et al*, 1973; Therkelsen *et al*, 1973).

Published cases of insertions are also scarce in the literature. As in the case of 'aneusomie de recombinaison' some of them may be inferred (Grouchy and Gabilan, 1965; Lejeune and Berger, 1965; Grouchy *et al*, 1966; Hoehn *et al*, 1971; Cantu, 1972; Neu and Gardner, 1972) while others are definitely ascertained by analysis of banding patterns (Grace *et al*, 1972; Gray *et al*, 1972; Rethoré *et al*, 1972; Taillemite *et al*, 1973; Therkelsen *et al*, 1973).

Among these insertions, only the case reported by Therkelsen *et al* (1973) proved to be an 'aneusomie de recombinaison'—namely, an intrachromosomal insertion involving a chromosome No. 2.

In the paper we report the first case of insertion between two chromosomes followed by 'aneusomie de recombinaison'.

Case report

The pedigree of the family is shown in Fig. 1. The index case is a girl whose birthweight was 2880 g, and who was born at term after an uneventful pregnancy. The parents are not consanguineous. They are in good health and young; the mother is 24 years old and the father 23 years old. The propositus was examined for the first time at the age of 3 years 7 months. The parents reported slow development of motor functions. The child was not able to sit until 18 months and could not stand until 2 years. Feeding has always been a problem and vomiting is frequent.

Clinical examination (Fig. 2) shows general hypotrophy (11 300 g) but a normal height (95 cm). Spontaneous activity is scarce and there is an overall muscular hypotrophy associated with severe muscular asthenia; the child is unable to sit when in a lying position and she must be aided to maintain a standing position. Walking is difficult and climbing stairs impossible.

She smiles and seems affectionate but does not talk.

IQ is 64. Osteotendinous reflexes are normal as is the EEG. The cranial circumference is slightly diminished (48 cm).

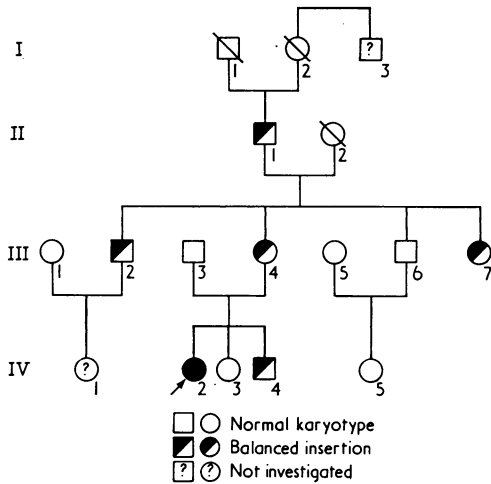


FIG. 1. Pedigree of the family.

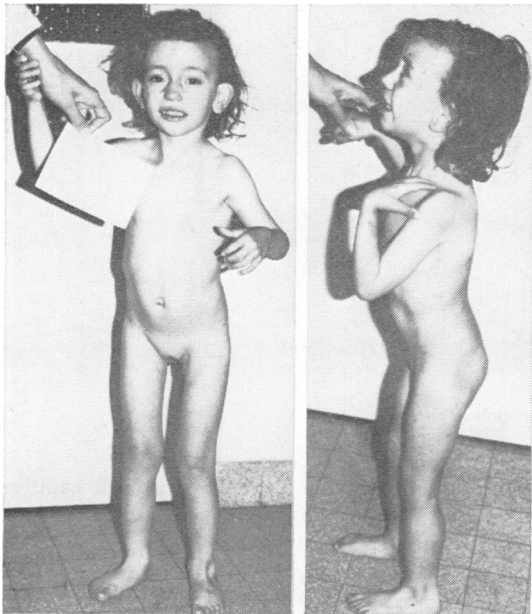


FIG. 2. The propositus.

Bone age is normal but there are several skeletal anomalies including spina bifida occulta located on the first sacral vertebra, dorsal and lumbar lordosis, right sided concavity scoliosis, protruding sternum lacking a xyphoid appendage, bilateral cubitus valgus and genu valgum, arched legs with inner concavity, valgus flat feet. The first toes are enlarged and on each side of the ankle there is an abnormal depression between the flexor tendons of the foot and the lateral malleolus.

A high grade systolic murmur (3/6) is apparently due to a ventricular septal defect. The face is severely dysmorphic, being unexpressive and looks like that of an elderly person. The forehead bulges and the nose is short and pointed with a large and protruding bridge. The eyes are globulous and the eye sight normal. There is no hypertelorism but on each side a slight epicanthus. The upper lip is thick and the teeth abnormally set and decayed. The ears are low set and protruding, their folds are normal as is also the hearing. The hands are thin with tapering fingers. Dermatoglyphic studies (Table) show axial triradii in the *t'* position.

Cytogenetic data

Sixty-one metaphases from venous blood have been examined. Ten of these were studied following R-banding (Dutrillaux *et al*, 1973) and 16 after G-banding (Seabright, 1972).

Conventional staining methods show an homogeneous 46,XX,(1q+;Bq-) type of anomaly. Banding methods show that the B-group chromosome involved is a No. 5 (Fig. 3). Measurement of 15 cells showed the ratio of the 1q+ chromosome to chromosome No. 1 to be 1.40 and the 5q- to normal No. 5 to be 0.78.

The karyotype of the mother of the propositus (III.4) studied by the same methods also discloses an homogeneous 1q+,5q- anomaly (41 cells examined). However, the length ratios are different (1q+/1 = 1.28; 5q-/5 = 0.56).

Observations using R- or G-banding techniques (Fig. 4) confirm the presence of a difference not only of length but also of banding pattern in the chromosomes of the mother and her daughter.

III.2, III.7, II.1, and IV.4 (the maternal uncle, aunt, grandfather, and brother) of the propositus are carriers of the same aberration as III.4 (see Fig. 1).

TABLE
DERMATOGLYPHIES OF THE PROPOSITUS

	Digit					Main lines	Axial triradius	Cresces
	1	2	3	4	5			
Right hand	W	R	U	A	W	A5 B6 C9 D11	<i>t'</i> 13	Normal
Left hand	U	R	A	U	U	A4 B6 C6 D11	<i>t'</i> 13	Normal

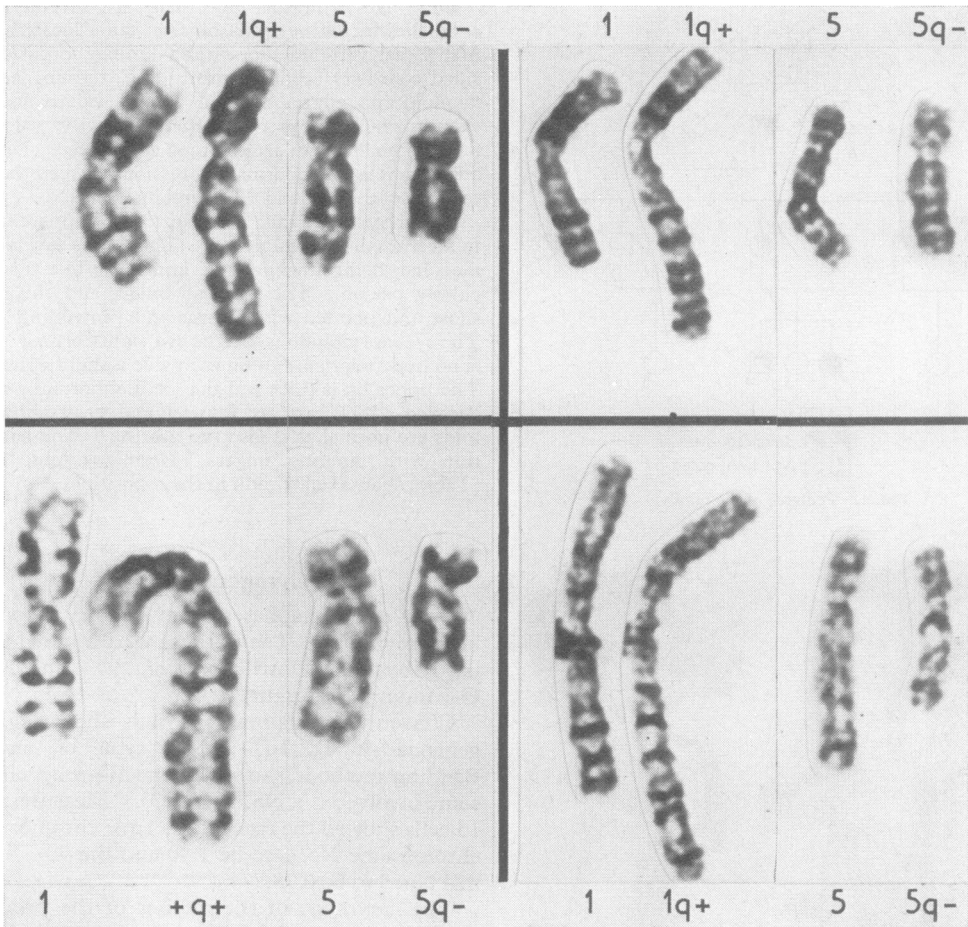


FIG. 3. Karyotype of the propositus in G-banding.

Discussion

Six members of this family show a lengthening of the long arms of a chromosome No. 1 and a shortening of the long arms of a chromosome No. 5. Five of them are normal on clinical examination (II.1, III.2, III.4, III.7, and IV.4). Their chromosomal anomaly, identical in each of them, is obviously balanced.

The propositus, on the contrary, not only presents with various malformations but is found to have a new type of chromosome aberration—namely, lengthening of the two chromosomes (No. 1 and No. 5) involved in the rearrangement found in the other family members. The increase in length of chromosome No. 1 is not obvious but shows clearly on measurement. Moreover the best specimens show

an extra band on the long arms (a dark band as revealed by G-banding) when compared with No. 1 chromosome of her mother.

Lengthening of the No. 5 chromosome, on the other hand, is quite obvious. Though shorter than in a normal No. 5 chromosome, it is definitely longer than in the 5q- chromosome of the mother. It seems as if it has regained the 5q12, 5q14, and 5q21 bands missing in the maternal No. 5 chromosome.

The possibility of a reciprocal translocation between chromosomes No. 1 and 5 was first considered. However, such an aberration could be ruled out since it could not explain the new rearrangements found in the propositus.

The possibility of a direct insertion of an inter-

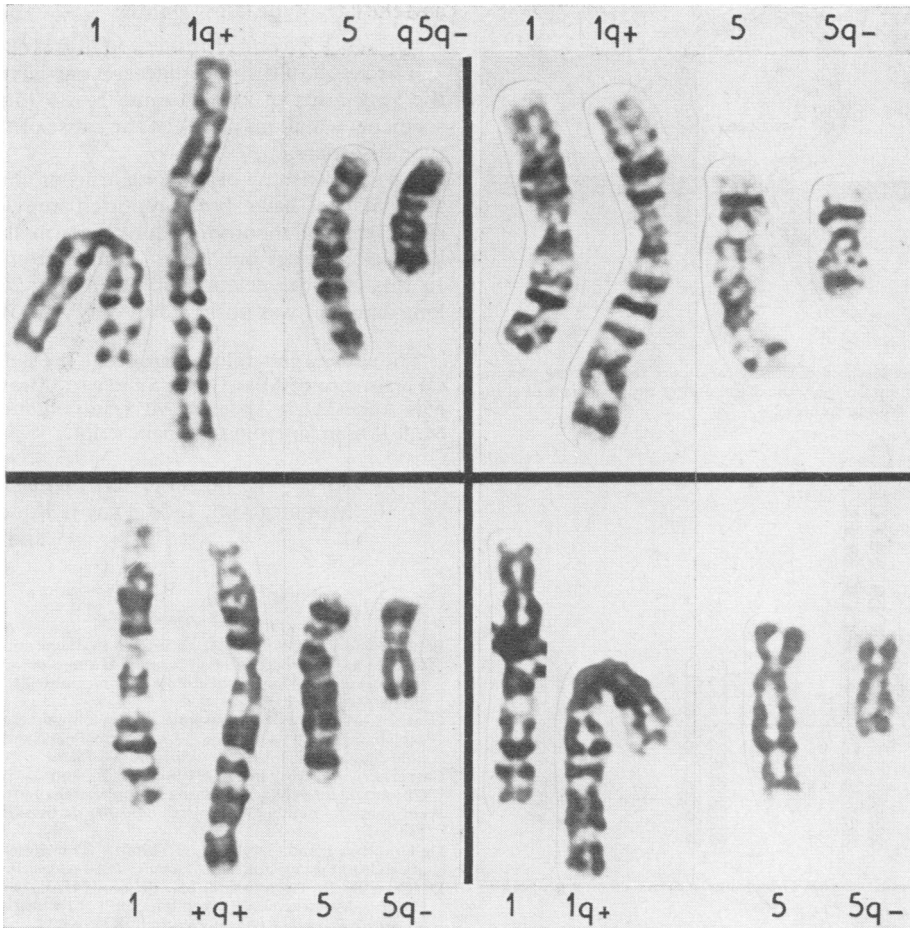


FIG. 4. Karyotype of the mother (III.4) in G-banding.

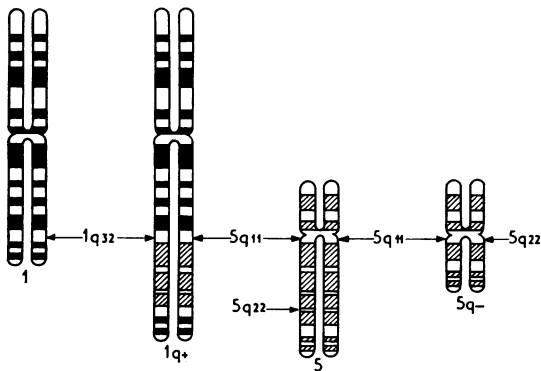


FIG. 5. Diagram of the G-banding pattern of the mother (III.4) and other balanced carriers of the insertion (II.1, II.2, III.7, IV.4).

stitial fragment from the long arms of a chromosome No. 5 into those of a No. 1 resulting in a 'aneusomie de recombinaison' seemed more likely.

Careful observations and comparison of the banding patterns suggest the following interpretation:

In the mother (III.4) and the other 'balanced' members of the family (II.1, III.2, III.7, IV.4) chromosome 1q+ could have the following constitution (Paris Conference, 1971):

1pter→1q32 :: 5q11→5q22 :: 1q32→1qter
while chromosome 5 from which the inserted fragment is missing can be written thus:

5pter→5q11 :: 5q22→5qter.

In all these individuals the karyotype (Fig. 5) may be expressed as 46,ins(1;5)(q32;q11q22).

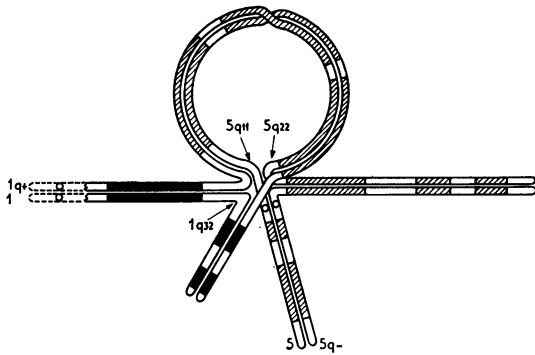


FIG. 6. Pairing mechanism during meiosis of the chromosomes involved in the insertion (only the distal part of the long arms of chromosome No. 1 are shown here).

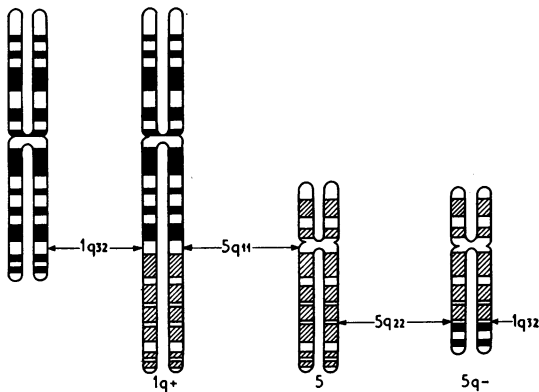


FIG. 7. Diagram of the G-banding pattern of the propositus' karyotype.

If such a hypothesis holds true, pairing of homologous loci at the pachytene stage of meiosis will produce a complex figure (Fig. 6) in which the loop is formed by the inserted fragment. If a cross-over event takes place at the loop, the following changes ensue (1) chromosome 1q+ lengthens slightly because of the replacement of segment 1q32→1qter by the 5q22→5qter segment, (2) chromosome 5 undergoes the reverse changes (replacement of 5q22→5qter by 1q32→1qter). Thus chromosome 5 is shorter than its normal counterpart, but longer, however, than the chromosome 5q- of the mother as it has gained all the inserted fragment.

Finally, if one accepts such a possibility, the two aberrant chromosomes of the propositus may be designated as follows:

chromosome 1q+ = 1pter→1q32 :: 5q11→5qter
 chromosome 5q- = 5pter→5q22 :: 1q32→1qter

and the karyotype (Fig. 7) thus:

46,XX,rec(1;5)(q32;q11q22).

The result of these changes is a partial trisomy for the long arms of chromosome No. 5 (5q11→5q22 segment) which may well be the cause of the phenotypic disorders.

No such trisomy of the long arms of chromosome 5 seems to have been reported previously. A single case of monosomy for this arm has, to our knowledge, been published (Lambotte *et al*, 1971). In this case the deletion involved only 20% of the long arm and was observed in only half of the cells.

The authors gratefully acknowledge the skilful technical assistance of Miss Gisèle Simonetti, Mrs Odile Bas, Mrs Anne-Marie Abônnel, Mr Jean Gilliotte, and Mrs M. J. Bossan for typing the manuscript.

P. JALBERT,* H. JALBERT, B. SELE,
 C. MOURIQUAND, J. MALKA, J. BOUCHARLAT,†
 and H. PISON

REFERENCES

- Boué, J. and Boué, A. (1973). L'intérêt en diagnostic prénatal des techniques nouvelles d'identification chromosomique dans des translocations et une aneusomie de recombinaison. *Nouvelle Presse Médicale*, **2**, 3097.
- Cantu, J.-M. (1972). 'Aneusomie de recombinaison'. A possible explanation for a t(Cp+;Cq-) in a normal male and his dysmorphic daughter. *Annales de Génétique*, **15**, 55.
- Caspersson, T., Hultén, M., Lindsten, J., and Zech, L. (1971). Chromatid interchange resulting in duplication of the short arm of chromosome number 7 in man. *Annales de Génétique*, **14**, 143-144.
- De Grouchy, J. and Gabilan, J. C. (1965). Translocation 5~21-22 et syndrome du cri du chat. *Annales de Génétique*, **8**, 31-38.
- De Grouchy, J., Aussannaire, M., Brissaud, H. E., and Lamy, M. (1966). 'Aneusomie de recombinaison': three further examples. *American Journal of Human Genetics*, **18**, 467-484.
- Dutrillaux, B., Laurent, C., Robert, J. M., and Lejeune, J. (1973). Inversion pericentrique, inv(10), chez la mère et aneusomie de recombinaison, inv(10), rec(10), chez son fils. *Cytogenetics and Cell Genetics*, **12**, 245-253.
- Dutrillaux, B. and Lejeune, J. (1971). Sur une nouvelle technique d'analyse du caryotype humain. *C.R. Academie des Sciences Serie D. Paris*, **272**, 2638-2640.
- Grace, E., Sutherland, G. R., and Bain, A. D. (1972). Family insertional translocation. *Lancet*, **2**, 231.
- Gray, J. E., Syrett, J. E., Ritchie, K. M., and Elliott, W. D. (1972). An interstitial translocation: chromosome No. 1p to 4q. *Lancet*, **2**, 92-93.
- Hoehn, H., Sander, C., and Sander, L. Z. (1971). 'Aneusomie de recombinaison': rearrangement between paternal chromosomes 4 and 18 yielding offspring with features of the 18q- syndrome. *Annales de Génétique*, **14**, 187-192.
- Lambotte, C., Frederic, J., Stainer, L., Jovanovic, M., and Bauduin, P. (1971). Premier cas de délétion au niveau du bras long d'un chromosome 5: caryotype 46,XY/46,XY,5q-. *Acta Paediatrica Belgica*, **25**, 143-158.
- Lejeune, J. and Berger, R. (1965). Sur deux observations familiales de translocations complexes. *Annales de Génétique*, **8**, 21-30.

* Laboratoire d'Histologie, Faculté de Médecine, 38700 La Tronche, France.

† Service de Psychothérapie, C. H. U. Hôpital Sud, 38 Grenoble, France.

- Neu, R. L. and Gardner, L. I. (1972). Three families with abnormal inherited chromosomes: $2q^+mat, t(Cp^+;13q^-)mat,$ and $t(3(?)^-;5q^+)pat$. *Annales de Génétique*, **15**, 19–24.
- Paris Conference (1971). Standardization in human cytogenetics. *Birth Defects: Original Article Series*, **8**, pt. 7, 1972. National Foundation—March of Dimes, New York.
- Rethoré, M. O., Lejeune, J., Carpentier, S., Prieur, M., Dutrillaux B., Seringe, P., Rossier, A., and Job, J. C. (1972). Trisomie pour la partie distale du bras court du chromosome 3 chez trois germains. Premier exemple d'insertion chromosomique: $ins(7;3)(q31;p21p26)$. *Annales de Génétique*, **15**, 159–165.
- Seabright, M. (1972). The use of proteolytic enzymes for the mapping of structural rearrangements in the chromosomes of man. *Chromosoma*, **36**, 204–210.
- Taillemite, J.-L., Baheux-Morlier, G., Cathelineau, L., and Roux, C. (1973). Maladie du cri du chat associé à un remaniement chromosomique complexe chez un jumeau dizygote. *Annales de Génétique*, **16**, 127–130.
- Taysi, K., Bobrow, M., Balci, S., Madan, K., Atasu, M., and Say, B. (1973). Duplication/deficiency product of a pericentric inversion in man: a cause of D1 trisomy syndrome. *Journal of Pediatrics*, **82** (2), 263–268.
- Therkelsen, A. J., Hultén, M., Jonasson, J., Lindsten, J., Christensen, N. C., and Iversen, T. (1973). Presumptive direct insertion within chromosome 2 in man. *Annals of Human Genetics*, **36**, 367–374.

Bloom's syndrome: a probable new case with cytogenetic findings

Summary. A 19-year-old Jordanian girl, born to first-cousin parents, has most features of Bloom's syndrome but is tall and has secondary amenorrhoea. Blood and skin cultures revealed a normal diploid female complement but about one-quarter of the cells show chromosome or chromatid gaps, breaks, and rearrangements. These abnormalities were localized after trypsin banding and have been found non-randomly distributed along the chromosomes.

Case report

The propositus is the third child of first-cousin parents. It is reported that she was not unusually small at birth. The family is Jordanian, of Moslem religion. There is no family history of a similar condition. Height is 164 cm, weight 36 kg, a head circumference of 49 cm—that is below the 1st centile for Palestinian Arab women and Indians (Meredit, 1971). She looks younger than 19. She has extensive scarring of the face and a rash, with both erythema and telangiectasis, which affects the cheeks, nose, eyelids, lips, and forehead. There was ectopia of the left lower lid with synechia of the exposed conjunctiva with keratinization. The dorsal skin of forearms and digits is atrophic, and there is slight atrophy of the

TABLE
ANALYSIS OF THE DIFFERENT TYPES OF
ABERRATIONS

	Culture Time		
	48 h.	72 h.	Total
No. of cells	203	302	505
% of cells with abnormalities	26.5	21.1	23.3
Aberrations per cell	0.31	0.258	0.279
Chromatid gaps	8	13	21
Isogaps	4	10	14
Chromatid breaks	8	2	10
Chromosome breaks	31	40	71
Quadriradials	2	1	3
Dicentric	4	1	5
Rings	—	1	1
Translocations	1	2	3
Acentric fragments	5	6	11
Chromosome duplications	—	2	2
'Cross-configurations'	6	4	10

skin of the upper back. The skin changes appeared at 3 months and are related to sun sensitivity. There are also a few small pigmented café-au-lait patches and a very large lesion of irregular contour (20 × 20 cm) with lentiginosities in it. Breast development is poor and pubic hair scanty. She had had two or three periods since the age of 16 and there was no response to stimulation of the ovaries. The only radiographical abnormality is a short right thumb, found also in her father.

The alpha-feto-protein and haemoglobin levels are within the normal range, but the IgA and IgM levels are below normal as described in Bloom's syndrome by Landau *et al* (1966) and Rauh and Saukup (1968).

Cytogenetic studies

Lymphocyte chromosome analysis of three different samples taken at monthly intervals, each grown for 48 and 72 h, gave almost similar results, which have therefore been pooled (Table). Among 505 well-spread trypsin-banded metaphases 23% were abnormal. Aberrations were mostly of the chromosome type: chromosomal aberrations and chromatic aberrations were seen in a ratio of approximately 3:1. There were rings, dicentric, translocations, and quadriradials (Figure). In seven of 11 instances the exchanges were between homologues and the break points were symmetrical; only three of these are quadriradials. Ten figures looking like symmetrical primary constriction overlaps of pairs of chromosomes with peculiar stretching out of the constriction/overlap region were seen. These cross-configurations differ from quadriradials as no breaks could be seen.

All the 125 localizable break-points of these structural events, including breaks and gaps are non-random: the centromeric region and telomeric region are especially involved. They show, respectively, 34% and 20% of the break-points.