

Unfortunately it was not possible to estimate the probability of excluding parentage because phenotype frequencies for many of the polymorphisms have not been reported for southern Italy. The present case bears some similarities to two Norwegian sisters, whose apparently unaffected parents were aged 62 and 64 years at the time of reporting (Haugerud, 1968), and whose red-cell antigens in 8 systems provided no evidence for excluding parentage. The alleged mutants both had histories of chronic progressive chorea.

The authors wish to thank Dr J. R. B. Ball for referring the patient and Mr J. Case, Mr D. N. Propert, and Mr A. J. Sheehy for typing the saliva and blood samples.

EDMOND CHIU and C. J. BRACKENRIDGE
*Department of Psychiatry, University of
 Melbourne, Royal Melbourne Hospital,
 Parkville 3050, Victoria, Australia*

REFERENCES

- Brackenridge, C. J. and Teltscher, B. (1975). The estimation of the age at onset of Huntington's disease from factors associated with the affected parent. *Journal of Medical Genetics*, **12**, 64-69.
- Cederbaum, S., Heywood, D., Aigner, R., and Motulsky, A. (1971). Progressive chorea, dementia and acanthocytosis; a genocopy of Huntington's chorea. *Clinical Research*, **19**, 177.
- Haugerud, S. (1968). Chronische progressive Chorea bei zwei Schwestern ohne nachweisbare Heredität. *Schweizerische medizinische Wochenschrift*, **98**, 2016-2020.
- Ørbeck, A. L. and Quelprud, L. (1954). *Setesdalsrykka (chorea progressiva hereditaria)*. J. Dybwad, Oslo.
- Palm, J. D. (1973). Longitudinal study of a preclinical test program for Huntington's chorea. *Advances in Neurology*, **1**, 311-324.
- Reed, T. E. and Neel, J. V. (1959). Huntington's chorea in Michigan. 2. Selection and mutation. *American Journal of Human Genetics*, **11**, 107-136.
- Stevens, D. and Parsonage, M. (1969). Mutation in Huntington's chorea. *Journal of Neurology, Neurosurgery and Psychiatry*, **32**, 140-143.

Trigonocephaly and associated minor anomalies in mother and son

Summary. A mother and her son are described with neonatal trigonocephaly, multiple suture synostosis; shallow orbits; unusual nose; deviation of the terminal phalanges of fingers 1, 2, and 5; and broad toes which radiologically may show duplication of the terminal phalanx. Untreated, the condition leads to a disfiguring oxycephaly with hypotelorism.

This appears to be the first documented instance of autosomal dominant trigonocephaly. The importance of the minor anomalies in its recognition and its good prognosis are emphasized.

Recent progress in facial corrective surgery has resulted in large numbers of children with cranio-stenosis being seen in single centres. This growth provides a new opportunity for the study and recognition of increasing numbers of subtypes of cranio-stenosis. Ultimately this will result in improved counselling for parents and patients. We describe here a mother and her son who are affected by trigonocephaly in association with multiple suture synostosis and other minor anomalies. We are unable to find previous reference to the transmission of trigonocephaly from an affected individual to the offspring.

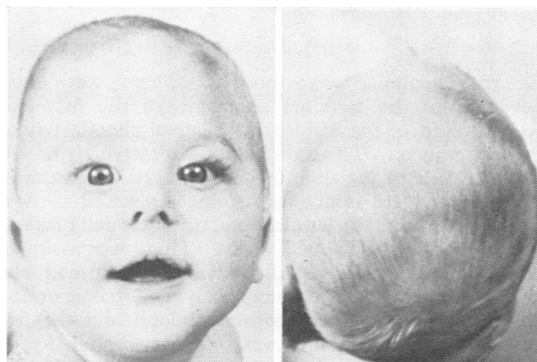


FIG. 1. Propositus at 6 months of age showing prominent metopic ridge, hypotelorism, epicanthic folds, and trigonocephaly.

Case reports

The propositus was referred to the Hospital for Sick Children in Toronto for evaluation of trigonocephaly. Birth had been complicated by a cephalohaematoma and linear parietal fracture, but development was normal.

On examination at 6 months, length was 71 cm (97%), weight 8500 g (80%), and head circumference 42.5 cm (30%). He had trigonocephaly with a prominent metopic ridge, shallow orbits, epicanthic folds, and minimal ptosis (Fig. 1). The inner canthal, outer canthal, and interpupillary distances were 2.5 cm (97%), 7 cm (50%), and 4 cm (3%), respectively. The nose was hooked with the septum extending below the alae, and the philtrum attached anteriorly on the septum. He had a large mouth with a down-turned upper lip.

* Reprint requests to: N.L.R., Department of Genetics, Hospital for Sick Children, Toronto, Ontario, Canada.

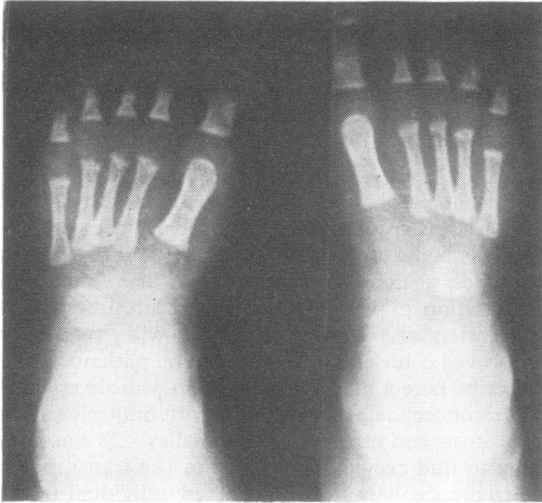


FIG. 2. X-ray of feet of propositus showing duplication of bones of distal phalanx of hallux on right, terminal phalanx on left, and pronounced clinodactyly of all toes.

External genitalia were normal. There was ulnar deviation of the terminal phalanges of the first and second digits of the hands, and bilateral clinodactyly of the fifth fingers. The right hallux was extremely broad, and the nails of the thumbs and halluces lacked dorsal curvature. Dermatoglyphic studies revealed a low total ridge count (44), a right distal triradius, and bilateral open fields in the hallucal areas. There was a simian crease on the left. Skull radiology confirmed the clinical impression of trigonocephaly, and demonstrated closure of the metopic, both lambdoid, and the left coronal sutures. There was distinct orbital hypotelorism. There was duplication of the distal phalanx of the right hallux and widening of the distal phalanx of the left hallux (Fig. 2). In the hands there was an abnormal ossified ossific nucleus at the base of the distal phalanx of each thumb. A radionucleotide scan of the skull showed total craniostenosis with only some questionable activity over the right lambdoid suture. At operation, the left coronal suture was completely closed; the right was partially open. The sagittal suture was open, but appeared to be closing. All sutures were surgically opened and separated by silastic sheeting. At the same time, the forehead was advanced. The child's head shape now looks perfectly normal.

Mother of propositus. Childhood photographs of the mother of the propositus show the typical appearance of trigonocephaly. She had been followed closely throughout childhood, but had received no operative treatment. When examined at the age of 32 years, she was 160 cm tall, and had a head circumference of 51 cm (below 3%). She had normal vision and olfaction, and

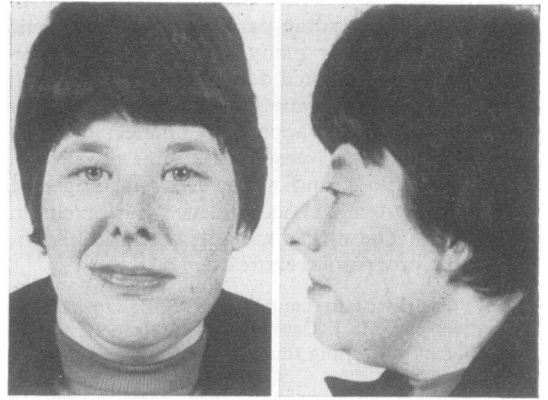

FIG. 3. Mother of propositus showing narrow tall forehead, hypotelorism, facial asymmetry, shallow orbits, sloping forehead, and hooked nose with anterior attachment of philtrum on the nasal septum.

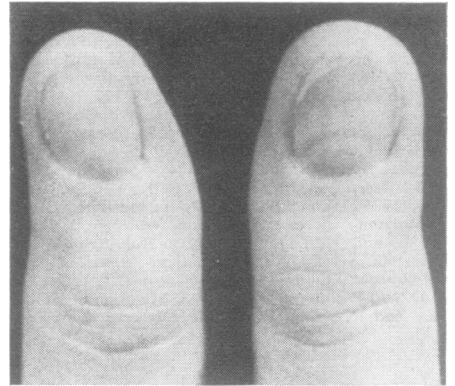


FIG. 4. Thumbs of mother showing flat nails and ulnar deviation of terminal phalanges.

was of average intelligence. She had pronounced oxycephaly, with a tall narrow forehead with a prominent bulge at the bregma and a low straight anterior hairline; the nasal and periorbital structures were similar to those of her son (Fig. 3). Large numbers of medullated nerve fibres emanated from both optic discs. The subnasal maxilla was hypoplastic, and the entire face was concave to the right, because of a relative hypoplasia of that side. She had an exaggerated cervicothoracic kyphosis. Hands, feet, and nails showed similar changes to those of her son, but more distinct (Fig. 4). Dermatoglyphs revealed a low total ridge count (56) and an open field on the right foot. Radiological examination revealed marked oxycephaly, hypotelorism, and a prominence at the bregma. There were no bony abnormalities of the hands or feet.

Other family members. The maternal grandmother had a similar nose, but lacked the shallow orbits, hypotelorism, and cranial abnormalities. Her hands were similar, but much more mildly affected, and without dermatoglyphic abnormality. She too, had an exaggerated cervicothoracic kyphosis. A maternal uncle of the mother is reported to have pronounced cutaneous syndactyly and a similar curvature of the fingers, but he could not be studied. The propositus has two normal sibs.

Discussion

Trigonocephaly results from premature synostosis of the metopic suture. It is evident from the skull shape of the mother, and from radionucleotide and operative studies in her infant, that multiple sutures were involved in our patients. However, both patients had the appearance of trigonocephaly as infants, and the importance of fusion of the metopic suture in this family is evident from the hypotelorism, which is in marked contrast to the hyper-telorism seen with many of the other forms of familial craniostenosis with multiple suture involvement. Anderson and Geiger (1965) found only one instance of multiple suture stenosis among 21 cases of trigonocephaly. Vogelsang (1966) on the other hand feels that multiple suture involvement may often be overlooked.

The incidence of craniostenosis is estimated at less than 5 per 10 000 livebirths, and about 10% of cases are thought to be familial (Menkes, 1974). Trigonocephaly comprises between 4% and 16% of cases of craniostenosis (Anderson and Geiger, 1965; Anderson and Gomes, 1968; Schurr, 1968; Shillito and Matson, 1968). None of these series reports a positive family history of trigonocephaly. However, this malformation, if mild, may be overlooked by both parent and physician (Anderson *et al*, 1962), possibly accounting for the lack of positive family histories. DeMyer (1971) is apparently aware of a family with recessive inheritance of trigonocephaly.

Currarino and Silverman (1960) divided trigonocephaly into two classes: those with and those without associated arrhinencephaly. It appears that in the absence of arrhinencephaly, trigonocephaly is less likely to be associated with other congenital anomalies than the other forms of craniostenosis (Anderson and Geiger, 1965; Schurr, 1968; Shillito and Matson, 1968). The absence of associated problems may contribute to the difficulties in recognizing familial cases; both our patients were

of normal intelligence, and neither had any major malformations.

The absence of associated major malformations in our patients increases the significance of their minor anomalies of face, hands and feet in the recognition of this familial form of multiple suture craniostenosis, with early prenatal involvement of the metopic suture and resultant neonatal trigonocephaly. The remarkably similar constellation of anomalies in mother and son are compatible with an autosomal dominant gene. The mild expression of the nasal and digital anomalies in the grandmother and possibly her brother raise the question of variable expressivity of this gene.

The hypothesis that a primary bony abnormality, rather than an underlying cerebral defect is the cause of simple trigonocephaly is supported by the normal head circumference at birth, and the experience of Currarino and Silverman (1960), who observed pointed frontal lobes to assume a normal size and contour upon removal from the skull. This risk that normal brain growth may be compromised together with the apparently high incidence of increased intracranial pressure and mental retardation (Shillito and Matson, 1968), appear to support early operative intervention, at the time of rapid brain growth. On the other hand, without surgery, the mother of our case had a benign clinical history but a poor cosmetic result.

A. G. W. HUNTER, N. L. RUDD,
and H. J. HOFFMANN

*Departments of Genetics and Surgery, Division
of Neurosurgery, Hospital for Sick Children,
Toronto, Canada*

REFERENCES

- Anderson, F. M. and Geiger, L. (1965). Craniostenosis. *Journal of Neurosurgery*, **22**, 229-240.
- Anderson, H. and Gomes S. P. (1968). Craniostenosis. *Acta Paediatrica Scandinavica*, **57**, 47-54.
- Anderson, F. M., Gwinn, J. L., and Todt, J. C. (1962). Trigonocephaly. *Journal of Neurosurgery*, **19**, 723-730.
- Currarino, G. and Silverman, F. N. (1960). Orbital hypotelorism, arrhinencephaly, and trigonocephaly. *Radiology*, **74**, 206-217.
- DeMyer, W. (1971). In *Mendelian Inheritance in Man*, ed. by V. A. McKusick, 3rd ed., p. 530. Johns Hopkins Press, Baltimore.
- Menkes, J. H. (1974). *Textbook of Child Neurology*. Lea and Febiger, Philadelphia.
- Schurr, P. H. (1968). Craniostenosis. *Developmental Medicine and Child Neurology*, **10**, 789-792.
- Shillito, J. and Matson, D. D. (1968). Craniostenosis: a review of 519 surgical patients. *Pediatrics*, **41**, 829-853.
- Vogelsang, H. (1966). Trigonocephalie. *Zeitschrift für Kinderheilkunde*, **96**, 67-74.